



**PATIENT**

Charlie Reichling

**SPECIES**

Canine

**BREED**

Labrador

**SEX**

Neutered Male

**AGE**

7 Years

**WEIGHT**

105 Pounds

**INTERPRETED BY**

Eric Lindquist, DMV  
DABVP, Cert. IVUSS

**IMAGING PERFORMED BY**

Jill Rumachik

**HOSPITAL NAME**

Clarity Imaging LLC

**REFERRING VET**

John Dally

**INVOICE**

17430

**DATE**

9/23/22

**PRESENTING CLINICAL SIGNS**

History: Palpable mass on exam; otherwise healthy dog with unremarkable lab work

**ULTRASONOGRAPHIC EXAMINATION OF THE ABDOMEN**

**Urinary System**

The **urinary bladder**, trigone, and pelvic urethra presented normal thicknesses and normal tone. The ureters were not visible which is normal. No uroliths or sediment were visualized, and anechoic urine was present. No evidence of inflammatory or neoplastic changes were noted. Ureteral papillae were normal.

The **kidneys** revealed normal size and structure, corticomedullary definition and ratio for this age. The cortices presented largely uniform texture with normal echogenic relationship to liver and spleen. Medullary structure differed distinctly from the cortex and no evidence of pelvic dilation was present. The capsules were acceptably uniform without significant irregularities. The left kidney measured 7.27 cm. The right kidney measured 5.0 cm. Slight mineralizations were noted, nonobstructive.

**Adrenal Glands**

Both **adrenal glands** were visualized and recognized as having normal shape, size, position and echogenicity for this breed. The phrenic vasculature, glandular echogenicity and detail were unremarkable. Capsule, cortex, and medullary definition were normal for this age patient. The left adrenal gland measured 0.5 cm. The right adrenal gland measured 0.6 cm at the cranial pole and 0.4 cm at the caudal pole.

**Spleen**

The **spleen** appeared slightly folded, this may be the source of the mass yet not pathological.

**Liver**

The **liver** images from right and left intercostal as well as subcostal views revealed subjectively normal liver size, contour, and structure. Some minor age-related parenchymal remodeling was noted but likely not clinically significant at this time. Vascular and biliary tracts were of normal volume and no evidence of congestion was noted. The gallbladder presented some dependent debris with essentially normal contour. The cystic and common bile ducts were normal. No overt evidence of active inflammatory, infiltrative or regenerative pathology was noted but should be paired with current or past LE elevations regarding any clinical significance to this presentation. The hepatic lymph nodes were unremarkable.

**Gastrointestinal**

Examination of the **gastrointestinal tract** revealed a stomach and intestine free of stasis, of normal wall thickness, acceptable curvilinear mural detail, and peristaltic activity. Small and large intestine demonstrated normal luminal chyme and stool consistency respectively. No obstructive or overt infiltrative disease was noted. No associated abnormal lymphatic activity was noted.

**Pancreas**



## PATIENT

Charlie Reichling

The base and limbs of the **pancreas** were observed to be largely isoechoic to surrounding omental fat. Pancreatic duct and capsular contour were acceptably normal and parenchyma respected normal curvilinear patterns. No overt evidence of active inflammatory or neoplastic disease was noted.

## SPECIES

Canine

## Free Abdomen

## BREED

Labrador

A large body wall **lipoma** was noted.\*See Spleen section.

## SEX

Neutered Male

## ULTRASONOGRAPHIC FINDINGS

- Structurally unremarkable abdomen
- Minor hepatic remodeling
- Large body wall lipoma
- Slightly folded spleen

## INTERPRETATION OF THE FINDINGS & FURTHER RECOMMENDATIONS

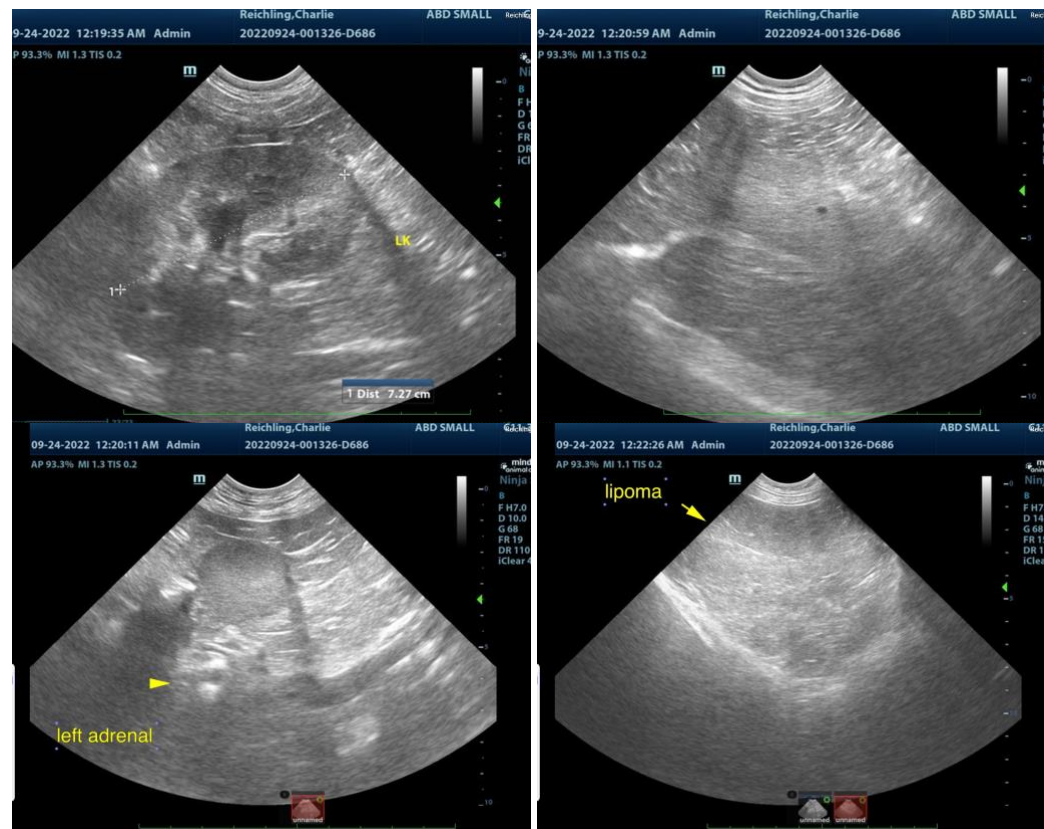
## AGE

7 Years

No evidence of masses.

## WEIGHT

105 Pounds



## INTERPRETED BY

Eric Lindquist, DMV  
DABVP, Cert. IVUSS

## IMAGING PERFORMED BY

Jill Rumachik

## HOSPITAL NAME

Clarity Imaging LLC

## REFERRING VET

John Dally

## INVOICE

17430

## DATE

9/23/22



**PATIENT**

Charlie Reichling

**SPECIES**

Canine

**BREED**

Labrador

**SEX**

Neutered Male

**AGE**

7 Years

**WEIGHT**

105 Pounds

**INTERPRETED BY**

Eric Lindquist, DMV  
DABVP, Cert. IVUSS

**IMAGING  
PERFORMED BY**

Jill Rumachik

**HOSPITAL NAME**

Clarity Imaging LLC

**REFERRING VET**

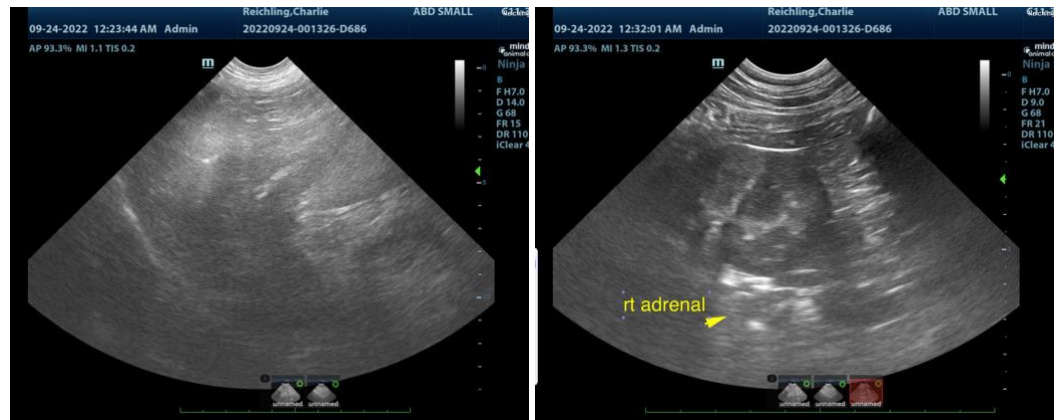John Dally

**INVOICE**

17430

**DATE**

9/23/22



The information and recommendations provided are based on the images presented by the referring veterinarian. No evaluation can be communicated regarding pathology that was not visible in the image/video clips provided.

Thank you for this referral. If the clinical or image interpretation does not parallel your findings or if I can be of any further assistance please contact me.

**Eric Lindquist**, DMV, DABVP, Cert. IVUSS, CEO of SonoPath.com  
info@SonoPath.com