SonoPath
Clinical Sonography & Telecytology

EDUCATIONAL TELECONSULTATION SERVICES™

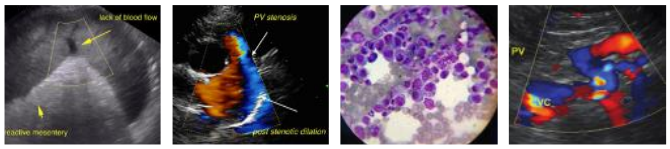

SonoPath.com
1-800-838-4268 info@sonopath.com

PATIENT

Angel Ajaj

SPECIES

Canine

BREED

Beagle Mix

SEX

Spayed Female

AGE

12 Years

WEIGHT

N/A

INTERPRETED BY

Eric Lindquist, DMV DABVP, Cert. IVUSS

IMAGING PERFORMED BY

Kelly Vazquez

HOSPITAL NAME

Sova Animal Hospital

REFERRING VET

Dr. Robert Sova

INVOICE

17420

DATE

9/23/22

PRESENTING CLINICAL SIGNS

History: Mild cardiomegaly on lateral thoracic radiograph. No current meds.

Abnormal PE/Chem/CBC/UA Results: PSL 191.

ULTRASONOGRAPHIC EXAMINATION OF THE HEART

CANINE CARDIAC PARAMETERS	MR VMAX (m/s)	TR VMAX (m/s)	LA/AO (Boon method)	LA/AO (Heart Base; Swe)	FS (%)	EF (%)	EPSS (cm)
NORMAL PARAMETER	4.5-5.5	<2.7	1.3	<1.3	28-40	40-100	<0.6
PATIENT	--	--	NM	1.3	25	51	0.2
CANINE CARDIAC PARAMETERS	**HR** (BPM)	**AV VMAX** (m/s)	**PV MAX** (m/s)	**BODY WEIGHT** (kg)	**LA** 2D short axis Base view (cm)	**LVIDd** Avg; 2D and m-mode short axis (cm)	**LVIDs** Avg; 2D and m-mode short axis (cm)
NORMAL PARAMETER	50-100	0.7-1.7	0.7-1.6				
PATIENT	122	1.24	1.02	--	2.67	2.56	--

Cardiac Presentation

The **echocardiogram** presented a prominent **right heart** with mild **right ventricular** hypertrophy, and normal **right atrial** size. Minor tricuspid insufficiency was noted. No evidence of neoplasia was noted in the right auricle, or elsewhere in the heart. The **pulmonary artery** was uniformly prominent with mildly depressed pulmonic velocity measured on PW Doppler. No overt heartworms were noted in the main or visible deep pulmonary arteries. Yet theoretically heartworms could be present in the deep pulmonary vasculature out of visible sonographic range. More likely, however, this prominent right heart is due to excessive intra-thoracic pressures caused by chronic respiratory disease or potentially excessive intra-thoracic fat (Pickwickian syndrome). The **left heart** demonstrated a linear **ventricular septum**. Contractility was functionally adequate demonstrated by the FS% measurement. The cranial and caudal **mitral** valve leaflets presented vegetative thickening consistent with endocardiosis. Doppler indicated minor insufficiency. The **left ventricular outflow** demonstrated normal flow patterns and velocities through the aortic valve. No evidence of tumor, pericardial or pleural effusion was noted. The visible **extra-cardiac** tissues were uniformly linear without evidence of masses, infiltrative or inflammatory mediastinal tissue. No evident arrhythmic activity was noted during the exam.

ULTRASONOGRAPHIC FINDINGS

- Stage B-1 valvular disease with minor cor pulmonale presentation, compensated

INTERPRETATION OF THE FINDINGS & FURTHER RECOMMENDATIONS

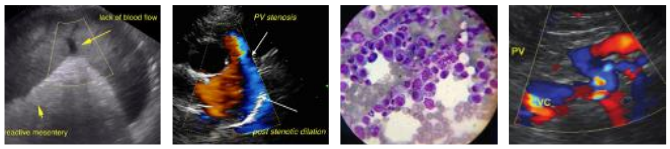

SonoPath.com
1-800-838-4268 info@sonopath.com

PATIENT

Angel Ajaj

SPECIES

Canine

BREED

Beagle Mix

SEX

Spayed Female

AGE

12 Years

WEIGHT

N/A

INTERPRETED BY

Eric Lindquist, DMV
DABVP, Cert. IVUSS

IMAGING PERFORMED BY

Kelly Vazquez

HOSPITAL NAME

Sova Animal Hospital

REFERRING VET

Dr. Robert Sova

INVOICE

17420

DATE

9/23/22

No evidence of functional deficits. The heart is stable without clinical disease. No overt contraindication for anesthesia of brief to moderate duration. I suggest Torbutrol premed, Propofol induction, Isoflo maintenance or similar protocol if anesthesia is desired. Blood pressure recommended if not already performed and target white coat negative systolic pressure of < 160 mmHg. If higher than this ACE-inhibitor is suggested to reach this level. Recheck echocardiogram is recommended in 6 months, earlier if murmur grade increases or clinical signs initiate.

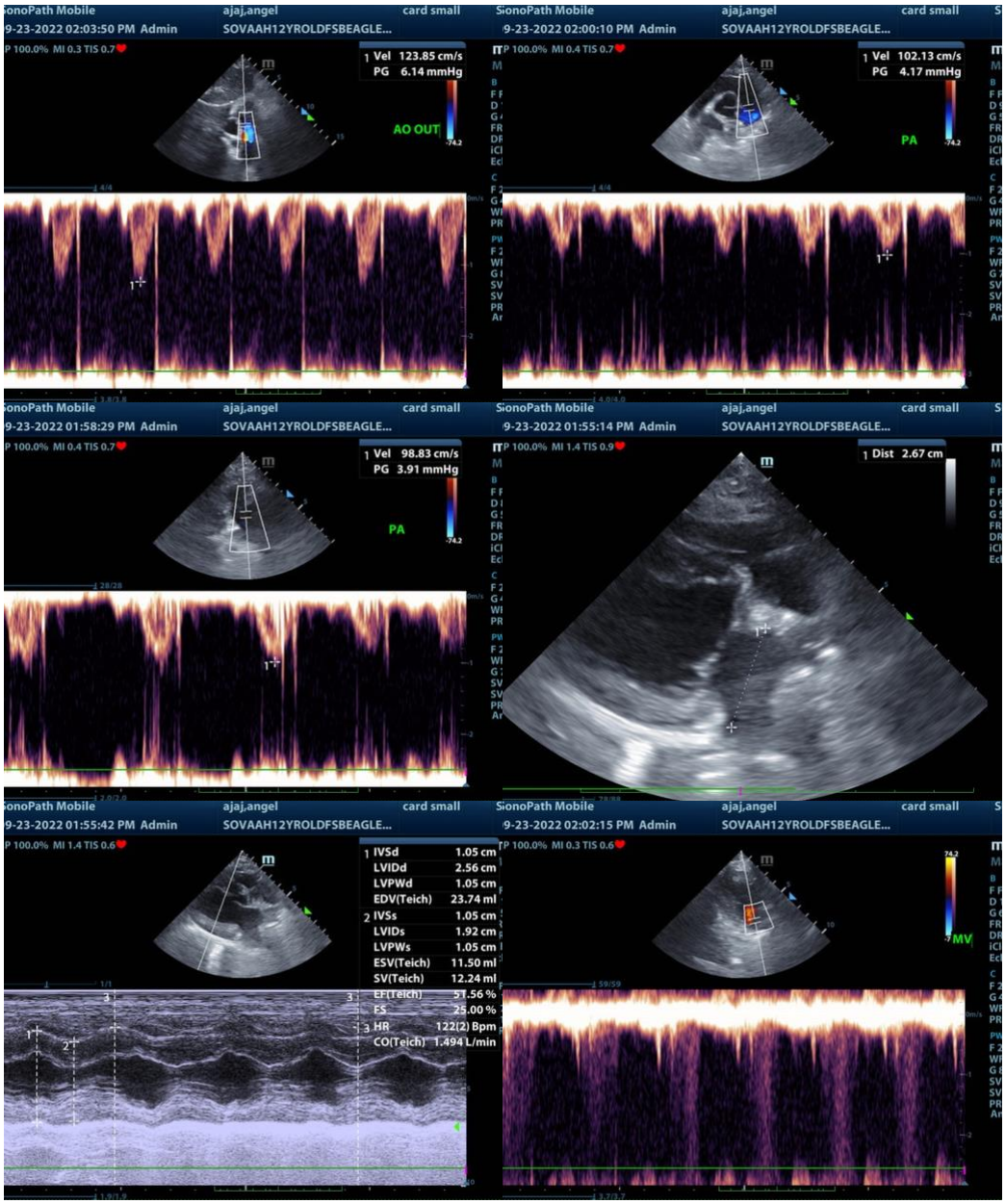

SonoPath

Clinical Sonography & Telecytology

EDUCATIONAL TELECONSULTATION SERVICES™

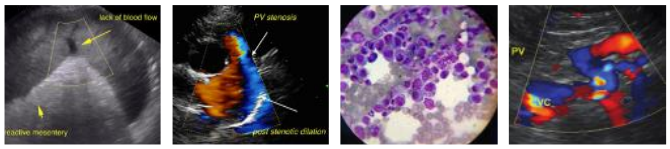

SonoPath.com™
1-800-838-4268 info@sonopath.com

PATIENT

Angel Ajaj

SPECIES

Canine

BREED

Beagle Mix

SEX

Spayed Female

AGE

12 Years

WEIGHT

N/A

INTERPRETED BY

Eric Lindquist, DMV
DABVP, Cert. IVUSS

IMAGING PERFORMED BY

Kelly Vazquez

HOSPITAL NAME

Sova Animal Hospital

REFERRING VET

Dr. Robert Sova

INVOICE

17420

DATE

9/23/22

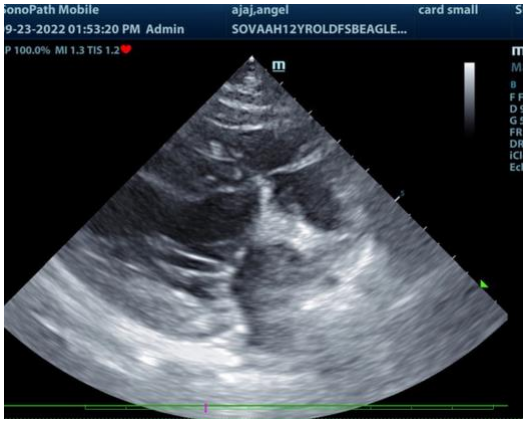

The information and recommendations provided are based on the images presented by the referring veterinarian. No evaluation can be communicated regarding pathology that was not visible in the image/video clips provided.

Thank you for this referral. If the clinical or image interpretation does not parallel your findings or if I can be of any further assistance please contact me.

Eric Lindquist, DMV, DABVP, Cert. IVUSS, CEO of SonoPath.com
info@SonoPath.com