



PATIENT

Maddie Mulder

SPECIES

Canine

BREED

Cockapoo

SEX

Spayed Female

AGE

8 years

WEIGHT

25 lbs

INTERPRETED BY

Eric Lindquist, DMV
DABVP, Cert. IVUSS

IMAGING PERFORMED BY

Dr. Nyberg

HOSPITAL NAME

Stuga North

REFERRING VET

Dr. Nyberg

INVOICE

91955

DATE

9/23/21

PRESENTING CLINICAL SIGNS

History: hospitalized this week at neighbor vet clinic and being treated for pancreatitis. She has been on LRS, cerenia, ondansetron, buprenorphine, famotidine, and metro.

ULTRASONOGRAPHIC EXAMINATION OF THE ABDOMEN

Urinary System

The **urinary bladder**, trigone, and pelvic urethra presented normal thicknesses and normal tone. The ureters were not visible which is normal. No uroliths or sediment were visualized and anechoic urine was present. No evidence of inflammatory or neoplastic changes was noted. Ureteral papillae were normal.

The iliac trifurcation was unremarkable.

The **kidneys** revealed normal size and structure, corticomedullary definition and ratio for this age. The cortices presented largely uniform texture with normal echogenic relationship to liver and spleen. Medullary structure differed distinctly from the cortex and no evidence of pelvic dilation was present. The capsules were acceptably uniform without significant irregularities. The left kidney measured 4.0 cm. The right kidney measured 4.0 cm.

Adrenal Glands

Both **adrenal glands** were visualized and recognized as having normal shape, size, position and echogenicity for this breed. The phrenic vasculature, glandular echogenicity and detail were unremarkable. Capsule, cortex, and medullary definition were normal for this age patient. The left adrenal gland measured 0.5 cm. The right adrenal gland measured 0.8 cm at the cranial pole and 0.4 cm at the caudal pole.

Spleen

The **spleen** presented a smooth homogeneous parenchyma hyperechoic to liver and renal cortical parenchyma. The capsule was smooth without noticeable expansion or deviation from within the spleen or adjacent pathology. The splenic vasculature demonstrated normal volume without signs of congestion or thrombosis. No sonographic evidence of acute or chronic inflammatory, neoplastic, or infarctual changes was noted.

Liver

The **liver** images submitted revealed subjectively normal liver size, contour, and structure. Parenchymal echogenicity was naturally coarse and hypoechoic to the spleen. Vascular and biliary tracts were of normal volume with no evidence of congestion. The gallbladder presented acceptably thin walls with primarily anechoic content. The cystic and common bile ducts were normal. No pathological hepatic lymphadenopathy was evident. No overt structural evidence of inflammatory, infiltrative or regenerative pathology was evident.



PATIENT

Gastrointestinal

Maddie Mulder

Examination of the **gastrointestinal tract** revealed a stomach and intestine free of stasis, of normal wall thickness, acceptable curvilinear mural detail, and peristaltic activity. A minor amount of ingesta was noted in the stomach. Minor, excessive gas was noted. The small intestine and colon were unremarkable.

SPECIES

Canine

BREED

Cockapoo

Pancreas

Slight, **pancreatic remodeling** was noted at the right base.

SEX

Spayed Female

ULTRASONOGRAPHIC FINDINGS

Structurally unremarkable abdomen.

Minor, heterogenous pancreatic changes.

AGE

8 years

INTERPRETATION OF THE FINDINGS & FURTHER RECOMMENDATIONS

Supportive care should prove effective.

WEIGHT

25 lbs

INTERPRETED BY

Eric Lindquist, DMV
DABVP, Cert. IVUSS

IMAGING PERFORMED BY

Dr. Nyberg

HOSPITAL NAME

Stuga North

REFERRING VET

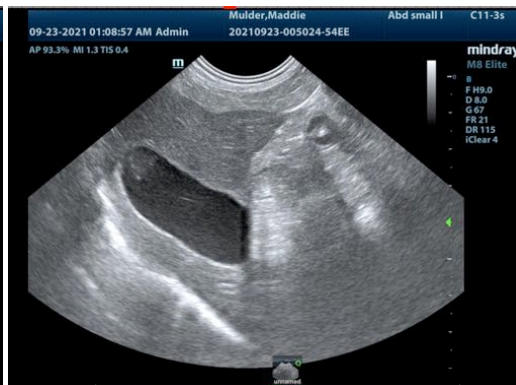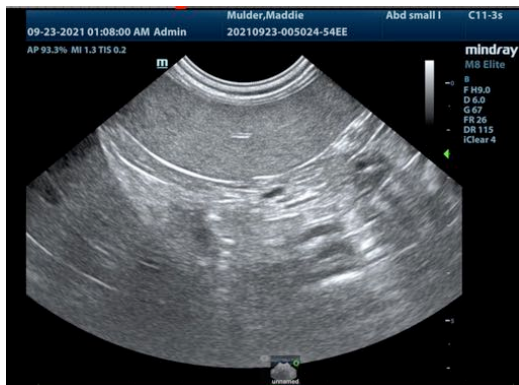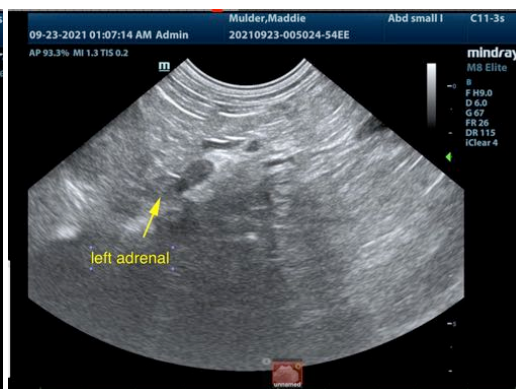
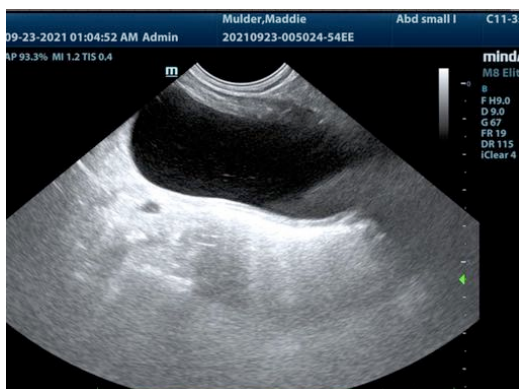
Dr. Nyberg

INVOICE

91955

DATE

9/23/21





PATIENT

Maddie Mulder

SPECIES

Canine

BREED

Cockapoo

SEX

Spayed Female

AGE

8 years

WEIGHT

25 lbs

INTERPRETED BY

Eric Lindquist, DMV
DABVP, Cert. IVUSS

IMAGING PERFORMED BY

Dr. Nyberg

HOSPITAL NAME

Stuga North

REFERRING VET

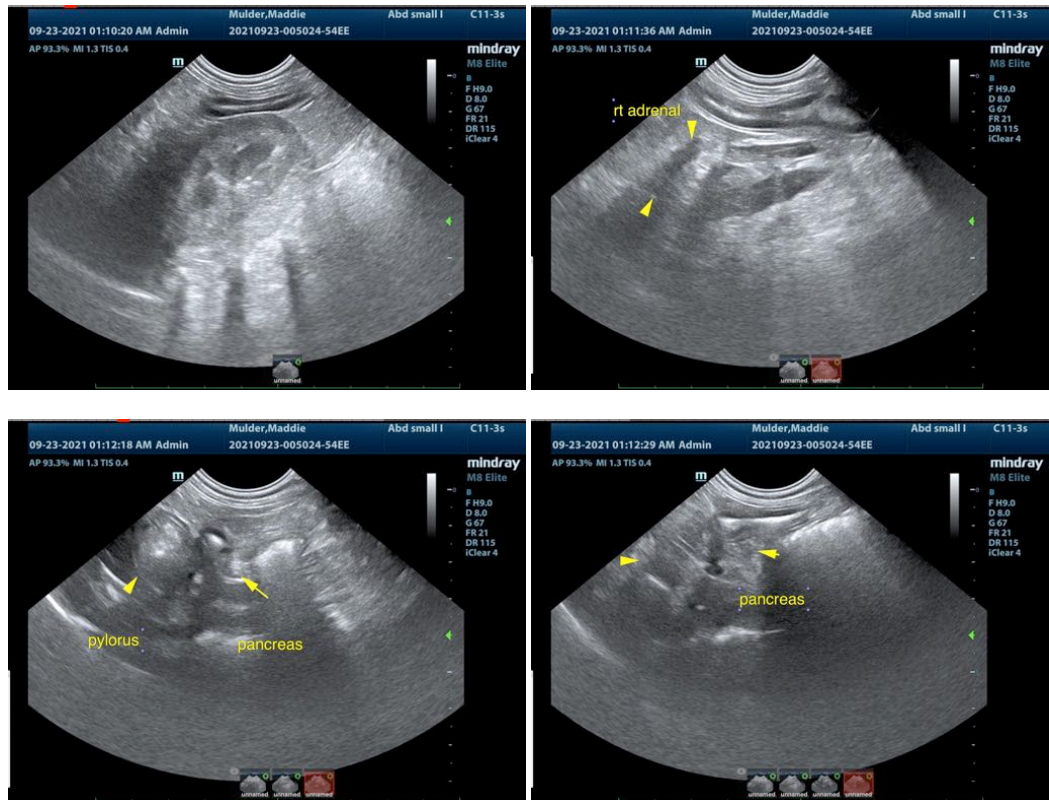
Dr. Nyberg

INVOICE

91955

DATE

9/23/21



The information and recommendations provided are based on the images presented by the referring veterinarian. No evaluation can be communicated regarding pathology that was not visible in the image/video clips provided.

Thank you for this referral. If the clinical or image interpretation does not parallel your findings or if I can be of any further assistance please contact me.

Eric Lindquist, DMV, DABVP, Cert. IVUSS, CEO of SonoPath.com
info@SonoPath.com