

PATIENT

Willie Johnson

SPECIES

Canine

BREED

Poodle Bichon

SEX

Neutered male

AGE

13 years

WEIGHT

20 lbs

INTERPRETED BY

Eric Lindquist, DMV
DABVP, Cert. IVUSS

IMAGING PERFORMED BY

Denise Bruno, LVT,
RDMS

HOSPITAL NAME

Ideal Pet VC

REFERRING VET

Dr. Kolta

INVOICE

39593

DATE

9/22/22

RESENTING CLINICAL SIGNS

History: Soft swelling caudal part of the mandible. Rad report attached.

ULTRASONOGRAPHIC EXAMINATION

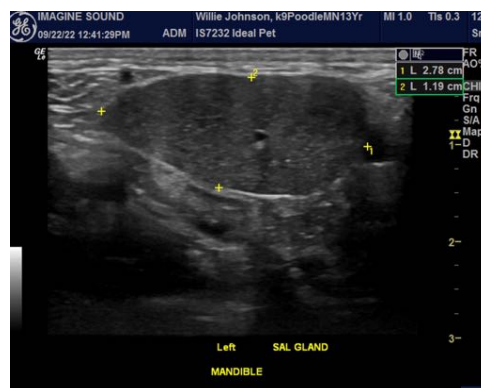
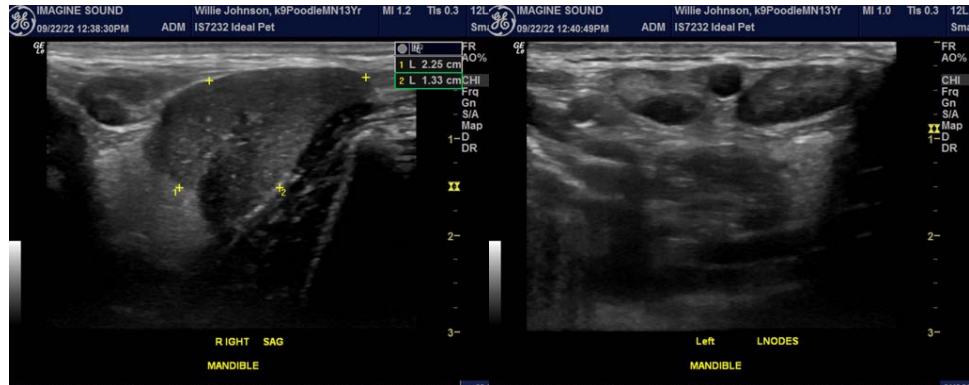
The left salivary gland was uniform and measured 2.8 x 1.2 cm. Submandibular and retropharyngeal lymph nodes were mildly enlarged and reactive. The length to width ratio was maintained. The right salivary gland was uniform and measured 2.25 x 1.33 cm.

ULTRASONOGRAPHIC FINDINGS

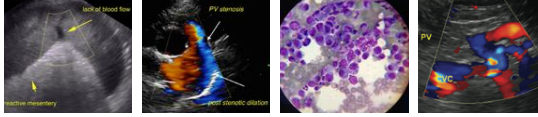
Minor sublumbar lymphadenopathy. Reactive lymph nodes.

INTERPRETATION OF THE FINDINGS & FURTHER RECOMMENDATIONS

There was no evidence of masses. FNA, cytology and culture of the lymph nodes can be considered for further definition.



The information and recommendations provided are based on the images presented by the referring veterinarian/sonographer. No evaluation can be communicated regarding pathology that was not visible in the image/video clips provided.



PATIENT

Willie Johnson

SPECIES

Canine

BREED

Poodle Bichon

SEX

Neutered male

AGE

13 years

WEIGHT

20 lbs

INTERPRETED BY

Eric Lindquist, DMV
DABVP, Cert. IVUSS

**IMAGING
PERFORMED BY**

Denise Bruno, LVT,
RDMS

HOSPITAL NAME

Ideal Pet VC

REFERRING VET

Dr. Kolta

INVOICE

39593

DATE

9/22/22

Thank you for this referral. If the clinical or image interpretation does not parallel your findings or if I can be of any further assistance please contact me.

Eric Lindquist, DMV, DABVP, Cert. IVUSS, CEO of SonoPath.com
Eric.Lindquist@SonoPath.com