



## PATIENT PRESENTING CLINICAL SIGNS

**PATIENT**  
Ronan Buduris  
Mildly overweight Previous mass removed on flank (biopsy confirmed panniculitis), no recurrence of growth since Otherwise normal on exam

## SPECIES

Feline

Abnormal PE/Chem/CBC/UA Results: Neutropenia 7/21/22 at time of surgery, unresolved on recheck 9/15/22 CBC path review negative for infectious or neoplastic organisms FeLV/FIV negative 9/15/22 Chemistry wnl (mild elevated cholesterol) Current Medications None

## BREED

DLH

## ULTRASONOGRAPHIC EXAMINATION OF THE ABDOMEN

### Urinary System

## SEX

Neutered Male

The **urinary bladder**, trigone, and pelvic urethra presented normal thicknesses and normal tone. The ureters were not visible which is normal. No uroliths or sediment were visualized and anechoic urine was present. No evidence of inflammatory or neoplastic changes were noted. Ureteral papillae were normal.

## AGE

2 Years

The **kidneys** revealed normal size and structure, corticomedullary definition and ratio for this age. The cortices presented largely uniform texture with normal echogenic relationship to liver and spleen. Medullary structure differed distinctly from the cortex and no evidence of pelvic dilation was present. The capsules were acceptably uniform without significant irregularities. The left kidney measured 4.46 cm. The right kidney measured 4.6 cm.

## WEIGHT

14.2 Pounds

### Adrenal Glands

## INTERPRETED BY

Eric Lindquist, DMV  
DABVP, Cert. IVUSS

Both **adrenal glands** were visualized and recognized as having normal shape, size, position and echogenicity for this breed. The phrenic vasculature, glandular echogenicity and detail were unremarkable. Capsule, cortex, and medullary definition were normal for this age patient. The right adrenal gland measured 0.64 cm. The left adrenal gland measured 0.53 cm.

## IMAGING PERFORMED BY

Sara Hansen

### Spleen

The **spleen** presented a smooth homogeneous parenchyma hyperechoic to liver and renal cortical parenchyma. The capsule was smooth without noticeable expansion or deviation from within the spleen or adjacent pathology. The splenic vasculature demonstrated normal volume without signs of congestion or thrombosis. No sonographic evidence of acute or chronic inflammatory, neoplastic, or infarctual changes were noted.

## HOSPITAL NAME

The Veterinary  
Hospital

### Liver

## REFERRING VET

Dr. Berman

The **liver** images submitted revealed subjectively normal liver size, contour, and structure. Parenchymal echogenicity was naturally coarse and hypoechoic to the spleen. Vascular and biliary tracts were of normal volume with no evidence of congestion. The gallbladder presented acceptably thin walls with primarily anechoic content. The cystic and common bile ducts were normal. No pathological hepatic lymphadenopathy was evident. No overt structural evidence of inflammatory, infiltrative or regenerative pathology was evident.

## INVOICE

41541

### Gastrointestinal

## DATE

9/22/22

Examination of the **gastrointestinal tract** revealed a stomach and intestine free of stasis, of normal wall thickness, acceptable curvilinear mural detail, and peristaltic activity. Small and large intestine



**PATIENT**

Ronan Buduris

**SPECIES**

Feline

**BREED**

DLH

**SEX**

Neutered Male

**AGE**

2 Years

**WEIGHT**

14.2 Pounds

**INTERPRETED BY**

Eric Lindquist, DMV

DABVP, Cert. IVUSS

**IMAGING PERFORMED BY**

Sara Hansen

**HOSPITAL NAME**

The Veterinary Hospital

**REFERRING VET**

Dr. Berman

**INVOICE**

41541

**DATE**

9/22/22

demonstrated normal luminal chyme and stool consistency respectively. No obstructive or overt infiltrative disease was noted. No associated abnormal lymphatic activity was noted.

**Pancreas**

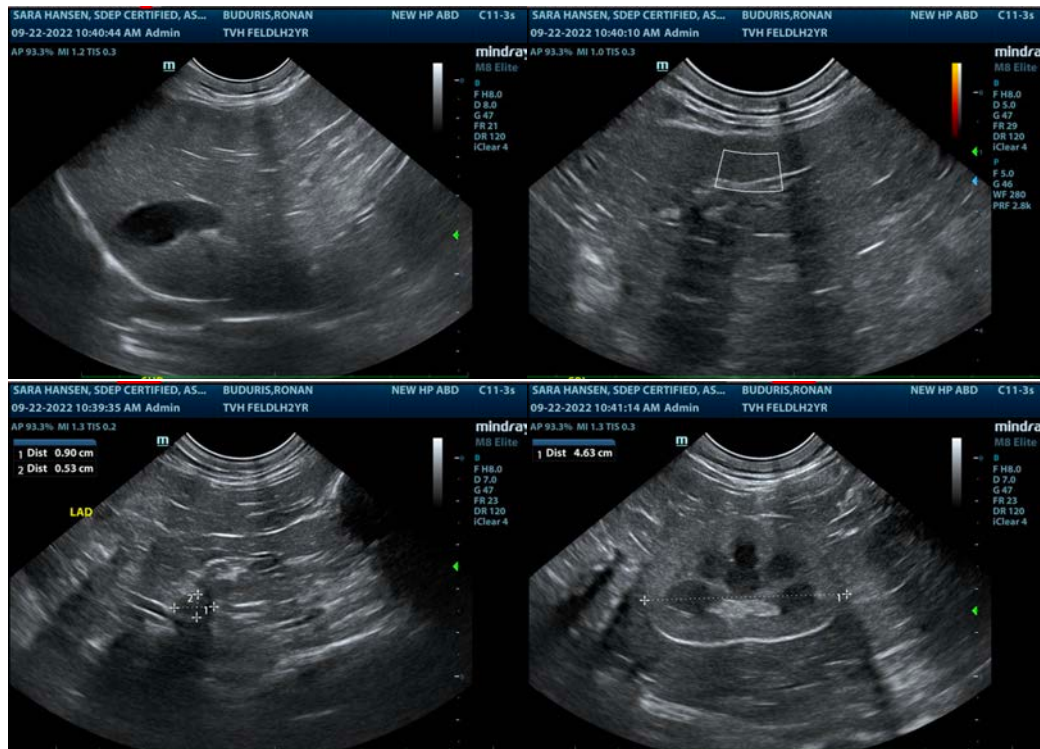
The base and limbs of the **pancreas** were observed to be largely isoechoic to surrounding omental fat. Pancreatic duct and capsular contour were acceptably normal and parenchyma respected normal curvilinear patterns. No overt evidence of active inflammatory or neoplastic disease was noted.

**ULTRASONOGRAPHIC FINDINGS**

- Structurally unremarkable abdomen

**INTERPRETATION OF THE FINDINGS & FURTHER RECOMMENDATIONS**

No evidence of primary or metastatic disease.





**PATIENT**

Ronan Buduris

**SPECIES**

Feline

**BREED**

DLH

**SEX**

Neutered Male

**AGE**

2 Years

**WEIGHT**

14.2 Pounds

**INTERPRETED BY**

Eric Lindquist, DMV  
DABVP, Cert. IVUSS

**IMAGING PERFORMED BY**

Sara Hansen

**HOSPITAL NAME**

The Veterinary  
Hospital

**REFERRING VET**

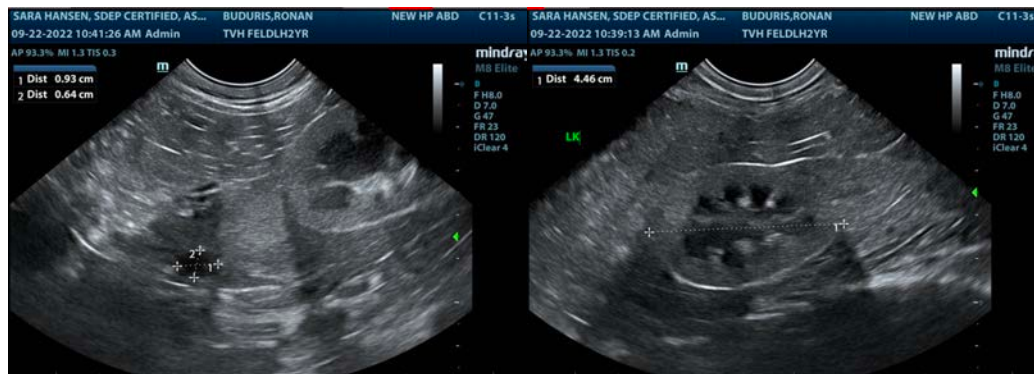
Dr. Berman

**INVOICE**

41541

**DATE**

9/22/22



The information and recommendations provided are based on the images presented by the referring veterinarian/sonographer. No evaluation can be communicated regarding pathology that was not visible in the image/video clips provided.

Thank you for this referral. If the clinical or image interpretation does not parallel your findings or if I can be of any further assistance please contact me.

Eric Lindquist, DMV, DABVP, Cert. IVUSS, CEO of SonoPath.com

[info@SonoPath.com](mailto:info@SonoPath.com)