

**DATE**

9/22/22

**PRESENTING CLINICAL SIGNS**

Not eating since Sept 15<sup>th</sup>. Not giving insulin. Exam: Distended abdomen, non painful. Uncontrolled diabetic.

**PATIENT**

Manly Seebach

Current Medications: Was given, in hospital, first dose of Mirtazapine 7.5mg, SQ fluids, enema and Convenia .72mL SQ. Sent home with Mirtazapine to give ½ tablet 2 days after dose given in hospital.

Lab Results; See attached.

**SPECIES**

Feline

Radiographs: Severe constipation, kidney stones and distended urinary bladder.

Date of Previous IntraPet Ultrasound: No previous.

Sedation: Not required to complete full diagnostic ultrasound.

Stat Report: Declined.

**BREED**

DSH

**ULTRASONOGRAPHIC EXAMINATION OF THE ABDOMEN****SEX**

Neutered Male

**Urinary System**

The **urinary bladder**, trigone, and pelvic urethra presented normal thicknesses and normal tone. The ureters were not visible which is normal. No uroliths or sediment were visualized and anechoic urine was present. No evidence of inflammatory or neoplastic changes were noted. Ureteral papillae were normal.

**AGE**

2/21/10

The **kidneys** revealed largely normal size and structure, corticomedullary definition and ratio (cortex 1/3 of medulla) were essentially maintained with some age-related loss of curvilinear patterns regarding the capsule and C/M junction. The cortices presented largely uniform texture with some increased echogenicity expected for his age patient. Medullary structure differed distinctly from that of the cortex and no evidence of pelvic dilation was present. The left kidney measured 4.88 cm. The right kidney revealed a pelvic calculus at 3.0 mm, non-obstructive. The right kidney measured 4.33 cm. Mild remodeling noted in both kidneys with mineralization.

**WEIGHT**

15.1 Pounds

**INTERPRETED BY**

Eric Lindquist, DMV  
DABVP, Cert. IVUSS

**Adrenal Glands**

The regions of the **adrenal glands** were unremarkable.

**IMAGING PERFORMED BY**

Rachel Brilhart RDMS

**Spleen**

The **spleen** presented a smooth homogeneous parenchyma hyperechoic to liver and renal cortical parenchyma. The capsule was smooth without noticeable expansion or deviation from within the spleen or adjacent pathology. The splenic vasculature demonstrated normal volume without signs of congestion or thrombosis. No sonographic evidence of acute or chronic inflammatory, neoplastic, or infarctual changes were noted.

**HOSPITAL NAME**

Glen Burnie AH

**Liver**

The **liver** images submitted revealed subjectively normal liver size, contour, and structure. Parenchymal echogenicity was naturally coarse and hypoechoic to the spleen. Vascular and biliary tracts were of normal volume with no evidence of congestion. The gallbladder presented acceptably thin walls with primarily anechoic content. The cystic and common bile ducts were normal. No pathological hepatic lymphadenopathy was evident. No overt structural evidence of inflammatory, infiltrative or regenerative pathology was evident.

**REFERRING VET**

Dr. Shah

**INVOICE**

41561

**Gastrointestinal**

The **gastrointestinal** presentation revealed mild uniform prominence of the gastric mucosa as well as areas of "ropey" small intestinal wall with slight disruption of the normal 1:3 muscularis/mucosal ratio. The intestinal submucosa was slightly irregular, thickened and hyperechoic suggestive of low grade, chronic disease. Intestinal wall thickness measured up to 0.43 cm. No concerning lymphadenopathy was visible. No evidence of obstruction was present. Chronic inflammatory bowel disease is likely with a low possibility of an early

neoplastic event such as lymphoma. Full thickness tissue biopsies via open laparotomy, ideally guided by intraoperative ultrasound in order to obtain the most representative mural sample, would be necessary to rule out this possibility.

### ***Pancreas***

The base and limbs of the **pancreas** were observed to be largely isoechoic to surrounding omental fat. Some parenchymal remodeling, however, with mild deviation from curvilinear normalcy was observed. Dilated duct noted at 0.30 cm. The left limb was mildly enlarged at 1.57 cm. If pain upon imaging (+ Murphy sign) was present or if the patient is focally painful in subxyphoid palpation then low-grade smoldering chronic pancreatitis should be suspected.

### ***Chest***

Rapid view of the chest revealed normal cardiac volume, contractility, and structure with a mild amount of pleural effusion as well as ringdown artifacts. This is non-cardiogenic pleural effusion.

## **ULTRASONOGRAPHIC FINDINGS**

- Chronic pancreatic and GI changes with minor intestinal thickening
- Age related renal changes
- Non-cardiogenic pleural effusion and ringdown artifacts

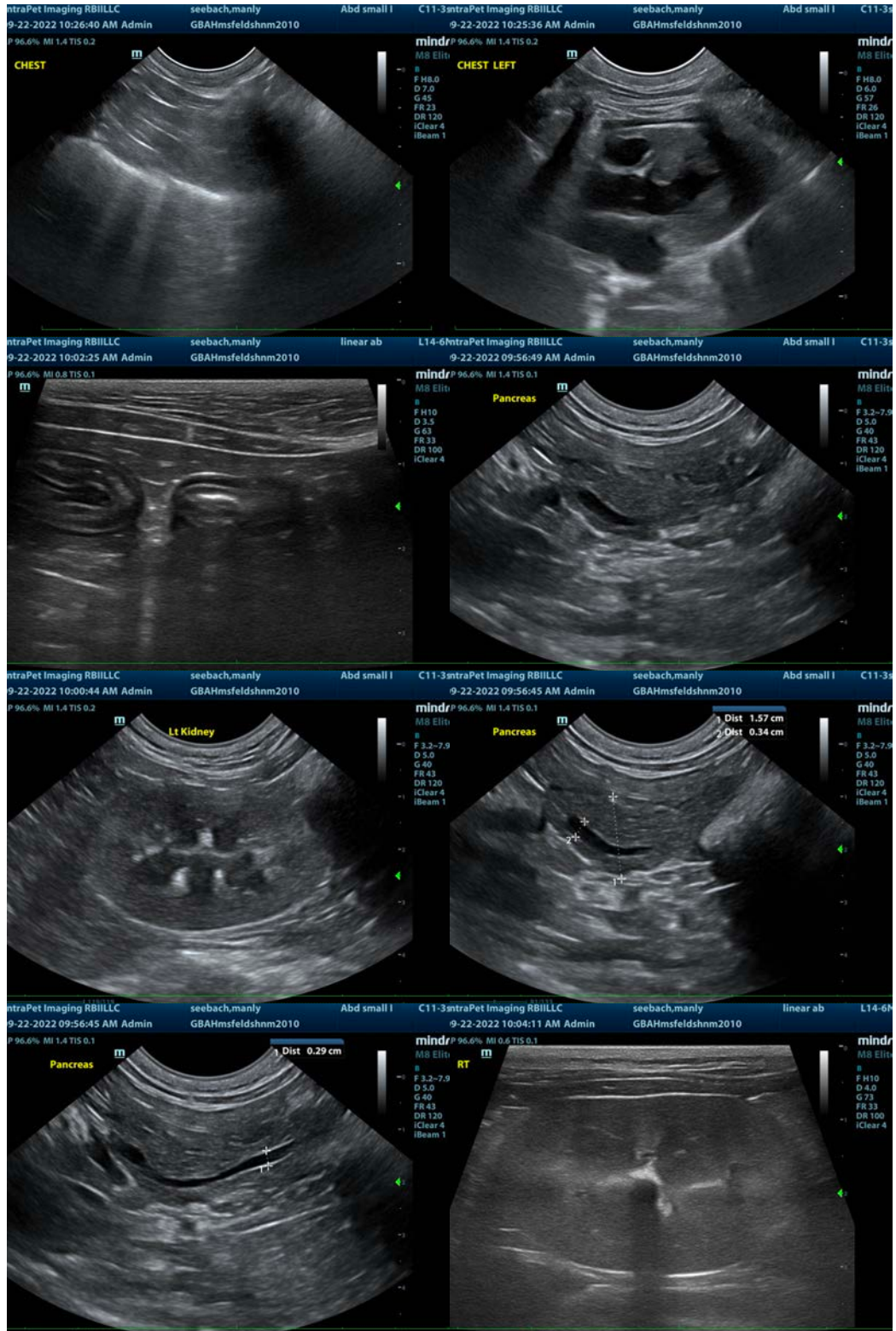
## **INTERPRETATION OF THE FINDINGS & FURTHER RECOMMENDATIONS**

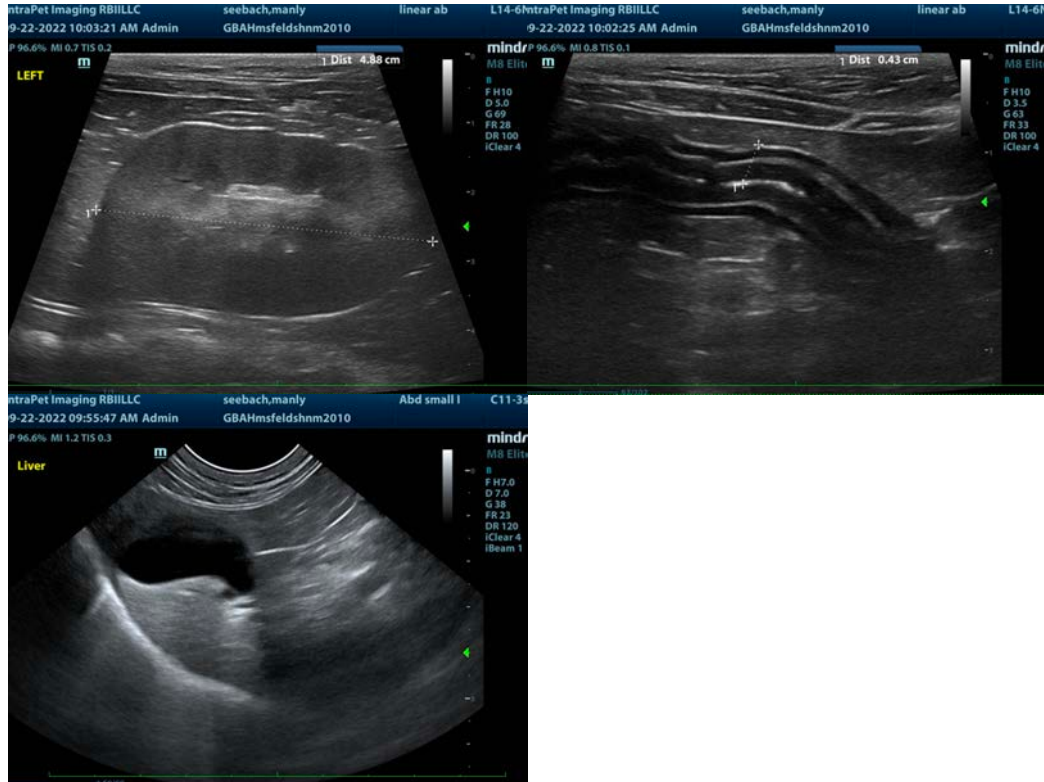
No evidence of active disease. Periodic pancreatitis may be playing a role in the diabetic dysregulation. No evidence of or suspicion of neoplasia in the abdomen. Chest radiographs +/- chest CT warranted. The pleural effusion is minor. However, if sampling is an option, cytospin of the free fluid would be indicated. Guarded prognosis depending upon thoracic workup.

### **Potential Causes of Diabetic Dysregulation**

This is a suggestive checkoff list when faced with an unregulated diabetic patient:

UTI  
Dietary indiscretion/intolerance  
Pancreatitis  
Hyperthyroidism/hypothyroidism  
Exogenous steroids (including topical eye meds)  
Cushing's  
Acromegaly  
Owner compliance  
Insulin quality issues  
Antibodies to insulin  
Underlying Neoplasia  
Diffuse liver disease





The information and recommendations provided are based on the images presented by the referring veterinarian/sonographer. No evaluation can be communicated regarding pathology that was not visible in the image/video clips provided.

Thank you for this referral. If the clinical or image interpretation does not parallel your findings or if I can be of any further assistance please contact me.

**Eric Lindquist**, DMV, DABVP, Cert. IVUSS, CEO of SonoPath.com  
[info@SonoPath.com](mailto:info@SonoPath.com)