



PATIENT

Maggie Savadge

PRESENTING CLINICAL SIGNS

tachypnea, abdominal breathing; chest rads show rounded cardiac silhouette. not on any meds

SPECIES

Canine

ULTRASONOGRAPHIC EXAMINATION OF THE HEART

BREED

German Shepherd

CANINE CARDIAC PARAMETERS	MR VMAX (m/s)	TR VMAX (m/s)	LA/AO (Boon method)	LA/AO (Heart Base; Swe)	FS (%)	EF (%)	EPSS (cm)
NORMAL PARAMETER	4.5-5.5	<2.7	1.3	<1.6	28-40	40-100	<0.6
PATIENT			NM	1.3	30		NM
CANINE CARDIAC PARAMETERS	HR (BPM)	AV VMAX (m/s)	PV MAX (m/s)	BODY WEIGHT (kg)	LA 2D short axis Base view (cm)	LVIDd Avg; 2D and m-mode short axis (cm)	LVIDs Avg; 2D and m-mode short axis (cm)
NORMAL PARAMETER	50-100	0.7-1.7	0.7-1.6	BELOW	BELOW	BELOW	BELOW
PATIENT					2.5	2.4	

SEX

Intact Female

AGE

12 Years

WEIGHT

N/A

Cardiac Presentation

The cardiac presentation revealed moderate pericardial effusion with echogenic debris. Volume contraction of the right ventricle and right atrium noted. Right atrial collapse owing to tamponade effect noted. The right auricle and right ventricular free wall appeared infiltrated with a mural mass measuring approximately 3.0 cm. Tamponade effect noted with hepatic vein dilation, gallbladder edema and secondary ascites.

INTERPRETED BY

Eric Lindquist, DMV
DABVP, Cert. IVUSS

ULTRASONOGRAPHIC FINDINGS

- Right auricular mass with pericardial effusion

IMAGING PERFORMED BY

Diane McFadden

INTERPRETATION OF THE FINDINGS & FURTHER RECOMMENDATIONS

Palliative pericardiocentesis and empirical chemotherapy should be considered in this patient. Some echogenic changes noted within the pericardium as well, which may represent tumor seeding or concurrent blood clot. Abdominal sonogram recommended to assess for related pathology.

HOSPITAL NAME

Blairstown AH

REFERRING VET

Dr. Lovell

INVOICE

41540

DATE

9/22/22



PATIENT

Maggie Savadge

SPECIES

Canine

BREED

German Shepherd

SEX

Intact Female

AGE

12 Years

WEIGHT

N/A

INTERPRETED BY

Eric Lindquist, DMV
DABVP, Cert. IVUSS

IMAGING PERFORMED BY

Diane McFadden

HOSPITAL NAME

Blairstown AH

REFERRING VET

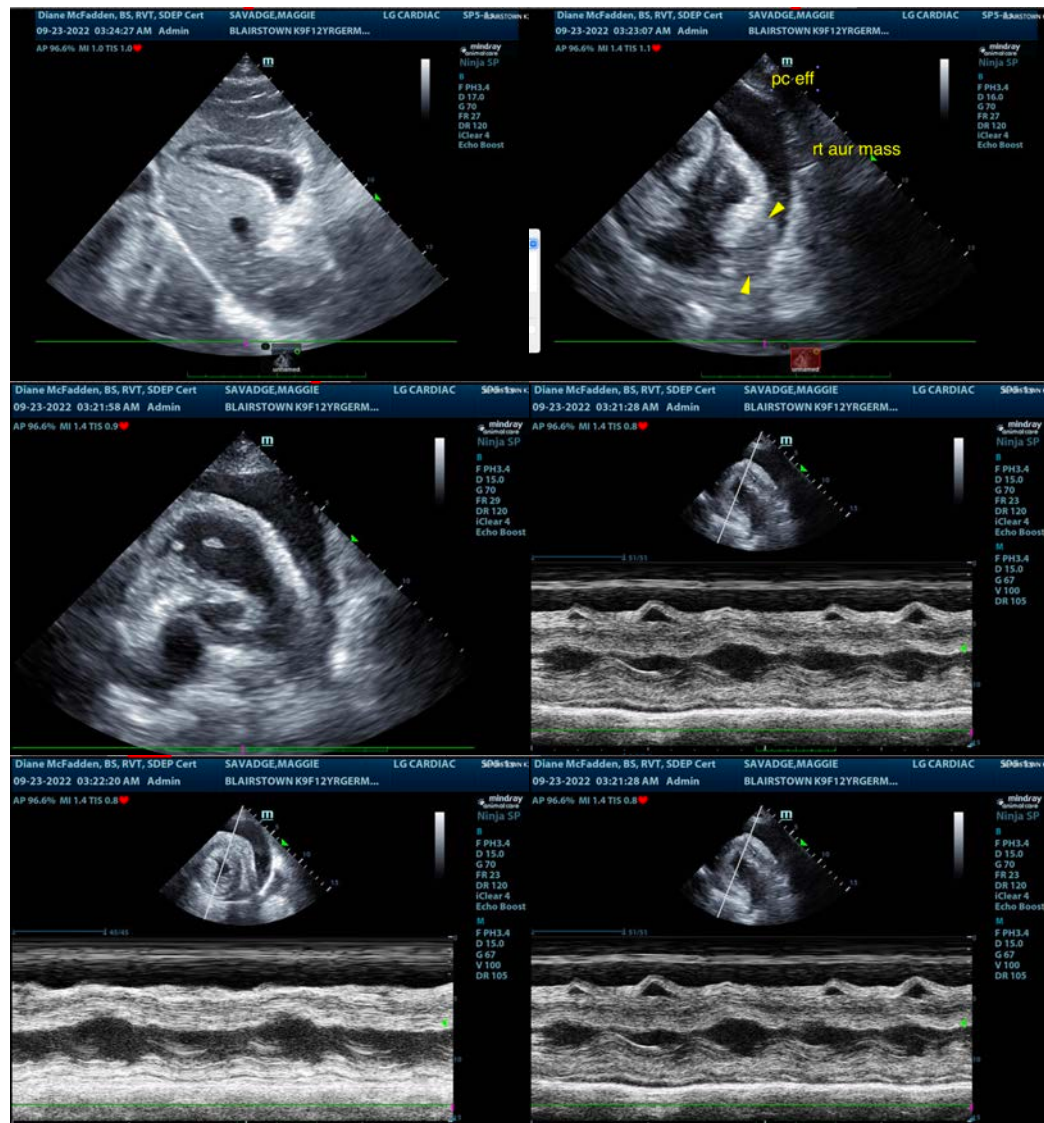
Dr. Lovell

INVOICE

41540

DATE

9/22/22



The information and recommendations provided are based on the images presented by the referring veterinarian/sonographer. No evaluation can be communicated regarding pathology that was not visible in the image/video clips provided.

Thank you for this referral. If the clinical or image interpretation does not parallel your findings or if I can be of any further assistance please contact me.

Eric Lindquist, DMV, DABVP, Cert. IVUSS, CEO of SonoPath.com

info@SonoPath.com



PATIENT

Maggie Savadge

Pericardial Effusion and Cardiac Neoplasia

SPECIES

Canine

<http://www.sonopath.com/CardiacNeoplasiaEffusion>

BREED

German Shepherd

SEX

Intact Female

Description: The pericardium is a fibrous sac that encloses the heart and the great vessels—aorta, pulmonary artery, proximal pulmonary veins, and vena cava—located at the heart’s base. It is attached caudally to the diaphragm and under normal circumstances contains 1-15 mL of fluid. The latter is comprised of phospholipids that lubricate the heart and allow it to expand and contract without generating friction. The pericardium also fixes the heart, prevents excess motion, and links the diastolic distensibility of the ventricles, thus limiting the degree to which either the left or the right ventricle will distend during diastole. When there are acute changes in venous return (i.e., during exercise), the pericardium plays a critical role in limiting ventricular filling. In cases of chronic cardiac enlargement, the pericardium also becomes distended, and its ability to limit ventricular filling, especially when the heart is at rest, becomes compromised. Pericardial tamponade occurs when there is a rapid accumulation of fluid and the pressure inside the pericardium increases significantly. With tamponade, ventricular filling is restricted and cardiac output is decreased. The right atrium and ventricle are the most vulnerable to this condition as these compartments have thinner walls and a lower pressure.

AGE

12 Years

WEIGHT

N/A

Etiology: Causes of pericardial effusion include:

INTERPRETED BY

Eric Lindquist, DMV

DABVP, Cert. IVUSS

- Neoplasia
 - Right atrial (RA) hemangiosarcoma
 - Heart base (aortic body) tumors
 - Mesothelioma
 - Rhabdomyosarcoma
 - Ectopic thyroid carcinoma
 - Metastatic neoplasia
- Idiopathic
- Congestive heart failure
- Peritoneal-pericardial diaphragmatic hernia
- Pericardial cyst
- Hypoalbuminemia
- Infectious pericarditis (bacterial, *Coccidioides immitus*)
- Feline infectious peritonitis
- Left atrial tear secondary to valvular disease
- Coagulopathy

IMAGING PERFORMED BY

Diane McFadden

HOSPITAL NAME

Blairstown AH

REFERRING VET

Dr. Lovell

INVOICE

41540

DATE

9/22/22

The majority of neoplastic masses consist of hemangiosarcoma and heart-based tumors (chemodectomas or ectopic thyroid adenocarcinoma). Idiopathic pericardial effusion is a diagnosis of exclusion; the effusion is typically hemorrhagic. Approximately 50% of dogs will be cured with a single pericardiocentesis, while some dogs will require multiple pericardiocenteses as well as surgery. A peritoneal-pericardial diaphragmatic hernia is a congenital hernia seen in dogs and cats in which the abdominal contents (i.e.,



PATIENT

Maggie Savadge

liver, small intestine, spleen, stomach) herniate into the pericardial sac. Constrictive pericarditis is an uncommon condition in which a non-distensible, thickened, fibrotic pericardium develops over time.

SPECIES

Canine

Clinical Signs: One will observe the following clinical signs, which often present in combination: ascites, lethargy, exercise intolerance, pale mucous membranes, weak pulses, *pulsus paradoxus*, and respiratory distress.

BREED

German Shepherd

Diagnostics: Survey radiographs will reveal hepatomegaly, cardiomegaly (generalized or sectorial globoid), and small pulmonary vessels. Pulmonary edema is typically not found, although one may discover concurrent pulmonary metastatic disease. An ECG will show electrical alternans or small complexes, but often the changes are very subtle and difficult to detect.

SEX

Intact Female

AGE

12 Years

Echocardiography is usually considered the gold standard for diagnosing pericardial effusion. Findings include:

WEIGHT

N/A

- Anechoic space between the heart and the pericardium.
- Abnormal side-to-side cardiac motion.
- Decreased chamber size (right ventricle [RV] and left ventricle [LV]).
- Presence of a pericardial or cardiac mass.
- Tamponade with early diastolic RA and RV collapse.

INTERPRETED BY

Eric Lindquist, DMV

DABVP, Cert. IVUSS

Cytology is helpful in the diagnosis of lymphoma, septic pericarditis, and idiopathic effusion, but not in cases of neoplasia.

IMAGING PERFORMED BY

Diane McFadden

According to a study that found troponin I levels to be higher in dogs with neoplastic pericardial effusion, the cardiac troponin I assay can be helpful in the diagnosis hemangiosarcoma.

HOSPITAL NAME

Blairstown AH

Prognosis:

REFERRING VET

Dr. Lovell

- Cardiac hemangiosarcoma: < 8 months with surgical debulking and chemotherapy.
- Chemodectoma (aortic derived): MST 730 days post pericardectomy.
- Idiopathic: 50% complete resolution post cardiocentesis; curative with pericardectomy, which can be done via thoracotomy, or thoracoscopy, or using a balloon to tear the pericardium.
- Mesothelioma: Poor.
- Restrictive pericarditis: Poor, especially when the pericardium has not been surgical stripped.

INVOICE

41540

DATE

9/22/22

References:



PATIENT

Maggie Savadge

Cagle LA, Epstein SE, Owens SD, et al. Diagnostic yield of cytology analysis of pericardial effusion in dogs. *J Vet Int Med* 2014;28:66-71.

SPECIES

Canine

Feigenbaum H. Pericardial disease. In: Feigenbaum H, ed. *Echocardiography, 5th ed.* Philadelphia, PA: Lippincott, Williams & Wilkins; 1994:556-588.

BREED

German Shepherd

Jackson J, Richter KP, Launer DP. Thoroscopic partial pericardectomy in 13 dogs. *J Vet Int Med* 1999;13:529-33.

SEX

Intact Female

AGE

12 Years

Johnson MS, Martin M, Binns S. A retrospective study of clinical findings, treatment and outcome in 143 dogs with pericardial effusion. *J Small Anim Prac* 2004;45:546-52.

WEIGHT

N/A

Kienle RD, Thomas WP. Echocardiography. In: Nyland TG and Mattoon JS, eds. *Small Animal Diagnostic Ultrasound, 2nd ed.* Philadelphia, PA: WB Saunders; 2000:354-423.

INTERPRETED BY

Eric Lindquist, DMV

Miller MW, Sisson DD. Pericardial disorders. In: Ettinger SJ and Feldman EC, eds. *Textbook of Veterinary Internal Medicine, 5th ed.* Philadelphia, PA: WB Saunders; 2000:923-36.

DABVP, Cert. IVUSS

IMAGING PERFORMED BY

Diane McFadden

Rajagopalan V, Jesty SA, Craig LE, et al. Comparison of presumptive echocardiographic and definitive diagnoses of cardiac tumors in dogs. *J Vet Int Med* 2013;27:1092-96.

HOSPITAL NAME

Blairstown AH

Shaw SP, Rozanski EA, Ruhs JE. Cardiac troponins I and T in dogs with pericardial effusion. *J Vet Int Med* 2004;18:322-24.

REFERRING VET

Dr. Lovell

Sidley JA, Atkins CE, Keene BW, et al. Percutaneous balloon pericardiotomy as a treatment for recurrent pericardial effusion in 6 dogs. *J Vet Intern Med* 2002;16:541.

Sisson D, Thomas WP. Pericardial disease and cardiac tumors. In: Fox PR, Sisson D, Moise NS, eds. *Textbook of Canine and Feline Cardiology, 2nd ed.* Philadelphia, PA: WB Saunders; 1999:679-701.

INVOICE

41540

Sisson D, Thomas WP, Reed J, et al. Intrapericardial cysts in the dog. *J Vet Int Med* 1993;7:364-69.

DATE

9/22/22