



PATIENT

Grace Siemer

PRESENTING CLINICAL SIGNS

newly diagnosed diabetes also has evidence of UTI pancreatitis, R/O underlying dz

SPECIES

Feline

ULTRASONOGRAPHIC EXAMINATION OF THE ABDOMEN

Urinary System

The **urinary bladder** revealed a minimal amount of urine. Minor debris present.

BREED

DSH

The **left kidney** was subnormal in size and irregular in contour, measuring 2.7 cm. Chronic interstitial nephrosis pattern. Multiple infarcts noted. No evidence of active inflammation.

SEX

Spayed Female

The **right kidney** was only partially visualized and appeared to be enlarged at approximately 5.0 cm with pericapsular inflammation. Further imaging of the right kidney indicated.

Adrenal Glands

The regions of the **adrenal glands** were unremarkable.

AGE

13 Years

Spleen

The **spleen** presented a smooth homogeneous parenchyma hyperechoic to liver and renal cortical parenchyma. The capsule was smooth without noticeable expansion or deviation from within the spleen or adjacent pathology. The splenic vasculature demonstrated normal volume without signs of congestion or thrombosis. No sonographic evidence of acute or chronic inflammatory, neoplastic, or infarctual changes were noted.

WEIGHT

14 Pounds

Liver

The **liver** images submitted revealed subjectively normal liver size, contour, and structure. Parenchymal echogenicity was naturally coarse and hypoechoic to the spleen. Vascular and biliary tracts were of normal volume with no evidence of congestion. The gallbladder presented acceptably thin walls with primarily anechoic content. The cystic and common bile ducts were normal. No pathological hepatic lymphadenopathy was evident. No overt structural evidence of inflammatory, infiltrative or regenerative pathology was evident.

INTERPRETED BY

Eric Lindquist, DMV

DABVP, Cert. IVUSS

Gastrointestinal

Examination of the **gastrointestinal tract** revealed a stomach and intestine free of stasis, of normal wall thickness, acceptable curvilinear mural detail, and peristaltic activity. Small and large intestine demonstrated normal luminal chyme and stool consistency respectively. No obstructive or overt infiltrative disease was noted. No associated abnormal lymphatic activity was noted.

IMAGING PERFORMED BY

Jenn

HOSPITAL NAME

Rockaway AH

Pancreas

The base and limbs of the **pancreas** were observed to be largely isoechoic to surrounding omental fat. Pancreatic duct and capsular contour were acceptably normal and parenchyma respected normal curvilinear patterns. No overt evidence of active inflammatory or neoplastic disease was noted.

REFERRING VET

Dr. Maniar

INVOICE

41514

ULTRASONOGRAPHIC FINDINGS

- Chronic nephritis left kidney, active nephritis right kidney
- Geriatric abdomen otherwise

DATE

9/21/22



PATIENT

Grace Siemer

INTERPRETATION OF THE FINDINGS & FURTHER RECOMMENDATIONS

Full urinary workup indicated.

SPECIES

Feline

Potential Causes of Diabetic Dysregulation

This is a suggestive checkoff list when faced with an unregulated diabetic patient:

UTI

BREED

DSH

Dietary indiscretion/intolerance

Pancreatitis

Hyperthyroidism/hypothyroidism

SEX

Spayed Female

Exogenous steroids (including topical eye meds)

Cushing's

AGE

13 Years

Acromegaly

Owner compliance

Insulin quality issues

WEIGHT

14 Pounds

Antibodies to insulin

Underlying Neoplasia

Diffuse liver disease

INTERPRETED BY

Eric Lindquist, DMV

DABVP, Cert. IVUSS

IMAGING PERFORMED BY

Jenn

HOSPITAL NAME

Rockaway AH

REFERRING VET

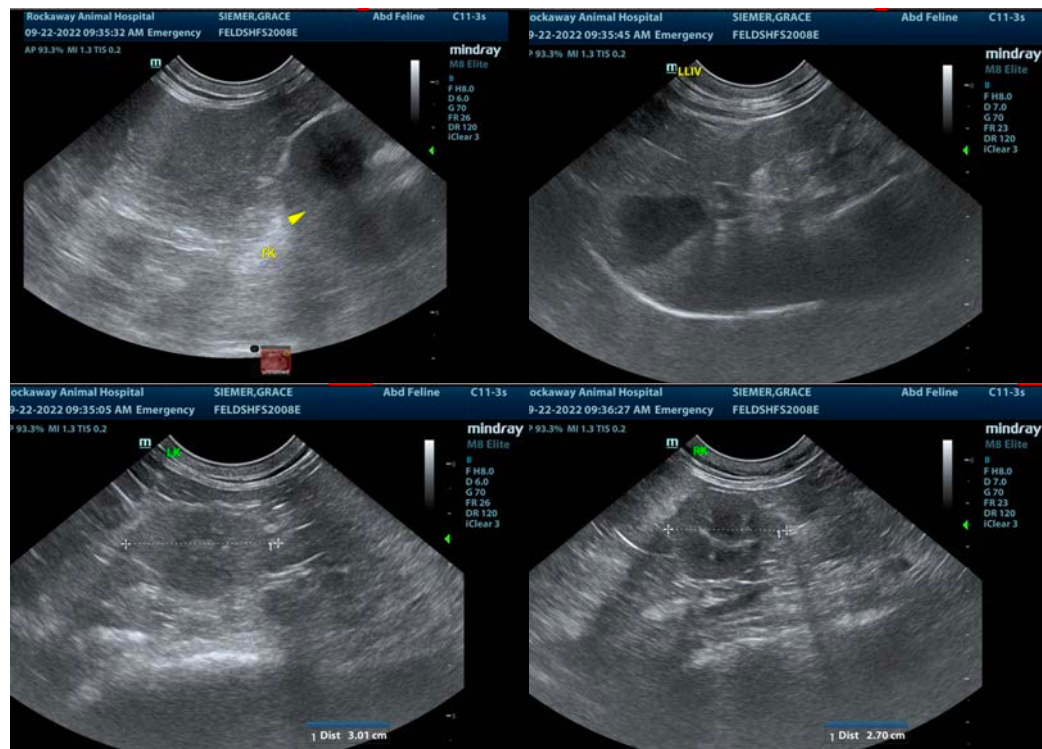
Dr. Maniar

INVOICE

41514

DATE

9/21/22





PATIENT

Grace Siemer

The information and recommendations provided are based on the images presented by the referring veterinarian/sonographer. No evaluation can be communicated regarding pathology that was not visible in the image/video clips provided.

SPECIES

Feline

Thank you for this referral. If the clinical or image interpretation does not parallel your findings or if I can be of any further assistance please contact me.

Eric Lindquist, DMV, DABVP, Cert. IVUSS, CEO of SonoPath.com

info@SonoPath.com

BREED

DSH

SEX

Spayed Female

AGE

13 Years

WEIGHT

14 Pounds

INTERPRETED BY

Eric Lindquist, DMV

DABVP, Cert. IVUSS

IMAGING PERFORMED BY

Jenn

HOSPITAL NAME

Rockaway AH

REFERRING VET

Dr. Maniar

INVOICE

41514

DATE

9/21/22