



PATIENT

Maple Pittock

PRESENTING CLINICAL SIGNS

History: P began losing weight rapidly over last 6 months. CBC, Superchem, UA, T4 all WNL, P acting normal otherwise. P very painful on abdominal palpation/ultrasound.

SPECIES

Canine

ULTRASONOGRAPHIC EXAMINATION

Spleen

The **spleen** revealed multi-focal, hyperechoic nodular changes. This is likely lipogranulomas. There were no overt masses; however, underlying neoplastic event cannot be completely ruled out.

BREED

Labrador Mix

Liver

The **liver** revealed increased portal markings and coarse architecture. This is consistent with hepatic remodeling.

SEX

Spayed female

AGE

12 years

ULTRASONOGRAPHIC FINDINGS

Undefined splenic nodules, likely lipogranulomas. However, underlying fibrosarcoma or similar neoplasia cannot be ruled out.

WEIGHT

61 lbs

Hepatic remodeling.

INTERPRETED BY

Eric Lindquist, DMV
DABVP, Cert. IVUSS

INTERPRETATION OF THE FINDINGS & FURTHER RECOMMENDATIONS

*****4 still images and 5 videos were submitted****

FNA of the spleen is recommended for a definitive diagnosis.

IMAGING PERFORMED BY

Christina

HOSPITAL NAME

Animal Health VC

REFERRING VET

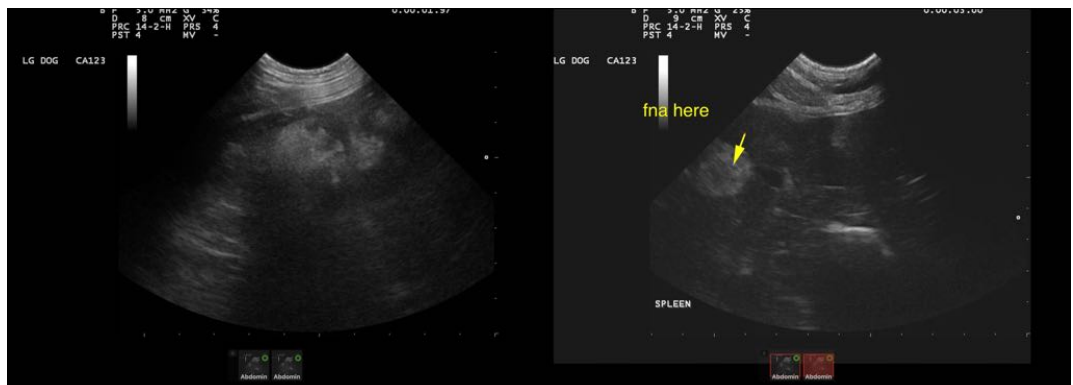Dr. Collazos

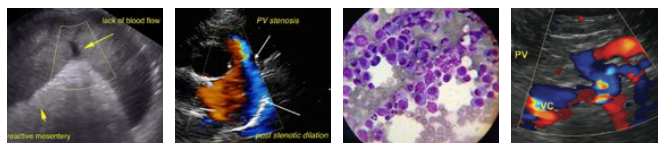
INVOICE

39533

DATE

9/21/22





PATIENT

Maple Pittcock

SPECIES

Canine

BREED

Labrador Mix

SEX

Spayed female

AGE

12 years

WEIGHT

61 lbs

INTERPRETED BY

Eric Lindquist, DMV
DABVP, Cert. IVUSS

IMAGING PERFORMED BY

Christina

HOSPITAL NAME

Animal Health VC

REFERRING VET

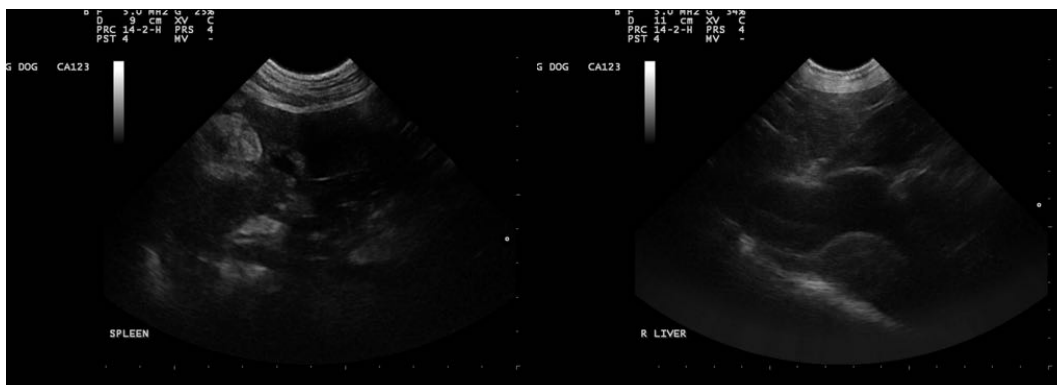Dr. Collazos

INVOICE

39533

DATE

9/21/22



The information and recommendations provided are based on the images presented by the referring veterinarian/sonographer. No evaluation can be communicated regarding pathology that was not visible in the image/video clips provided.

Thank you for this referral. If the clinical or image interpretation does not parallel your findings or if I can be of any further assistance please contact me.

Eric Lindquist, DMV, DABVP, Cert. IVUSS, CEO of SonoPath.com
info@SonoPath.com