



PATIENT

Artin X. Gates Bailey

SPECIES

Marsupial

BREED

Sugar Glider

SEX

Male

AGE

1 Year 4 Months

WEIGHT

81.5 grams

INTERPRETED BY

Eric Lindquist, DMV

DABVP, Cert. IVUSS

IMAGING PERFORMED BY

Dr. Agnes Rupley

HOSPITAL NAME

All Pets Medical

REFERRING VET

Dr. Agnes Rupley

INVOICE

41457

DATE

9/21/22

PRESENTING CLINICAL SIGNS

Presented yesterday for vomiting. REPORTED SYMPTOM: Owner reports that Artin has been acting nauseated and like he is not feeling well. Began vomiting 9/17, and hs vomited approx 6 times. Passed two pale but otherwise normal stools, one normal color but somewhat dehydrated. Hyporrexia. Had tremors in forelimbs while vomiting, frantic movement immediately prior to vomiting. Tired but still bright eyed, alert, and responsive. No urine output. No grooming well. Seems to be breathing a bit heavy. Not fast. Again it looks like he is uncomfortable. Sometime after eating. He ate last night and vomited almost immediately (9pm). Abdomen looks a bit more bloated and uncomfortable today. He ate some at 6:30am, urinated, had a solid but somewhat pale bowel movement. VITALS: 815 g Heart Rate: TNTC bpm Respiratory Rate: 200 bpm Mucous Membrane Color: pink Capillary Refill Time: <2 CURRENT MEDICATIONS: None yesterday. Gave subcutaneous fluids and Cerenia injection yesterday. EXAM FINDINGS: Artin is underweight, with a body score of 3/9 Skin tenting LAB RESULTS: Intestinal Parasite Screen (Fecal Float) reveals no evidence of intestinal parasites. Owner declined further testing yesterday, but approved testing today: Chemistry panel: elevated BUN, calcium, and glucose with low phosphorus. CBC: anemia, leukopenia resulting from a neutropenia eosinopenia, and lymphopenia, however a monocytosis is present. ASSESSMENT AND PLAN: Loops of small intestine appeared dilated on GLOBAL ultrasound today. Recommended antibiotics, fluids, pain relief and exploratory diagnostic surgery.

LIMITED ULTRASONOGRAPHIC EXAMINATION

Interpreting images was difficult due to poor resolution and image quality. Large amount of gastric artifact present.

The kidneys appear subjectively unremarkable, measuring approximately 1.3 cm each.

The spleen appeared volume contracted.

The visible liver appeared unremarkable. The gallbladder was unremarkable.

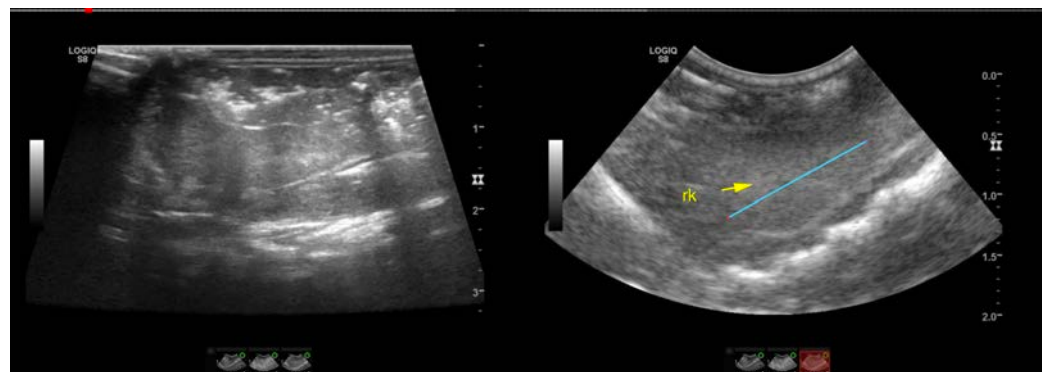
Gastric stasis was present with a 0.5 cm shadowing structure in the pylorus, which may represent medications or ingesta. The small intestine was mildly thickened. Some intestinal stasis was present.

ULTRASONOGRAPHIC FINDINGS

- Gastric stasis with slight shadowing 0.5 cm material in the pylorus

INTERPRETATION OF THE FINDINGS & FURTHER RECOMMENDATIONS

Underlying parasitic disease may be an issue/worm burden. Fecal test, treatment for parasites, supportive care all indicated. Recheck sonogram in 48-72 hours if clinical signs are persistent. Otherwise, exploratory surgery necessary.





PATIENT

Artin X. Gates Bailey

SPECIES

Marsupial

BREED

Sugar Glider

SEX

Male

AGE

1 Year 4 Months

WEIGHT

81.5 grams

INTERPRETED BY

Eric Lindquist, DMV

DABVP, Cert. IVUSS

IMAGING PERFORMED BY

Dr. Agnes Rupley

HOSPITAL NAME

All Pets Medical

REFERRING VET

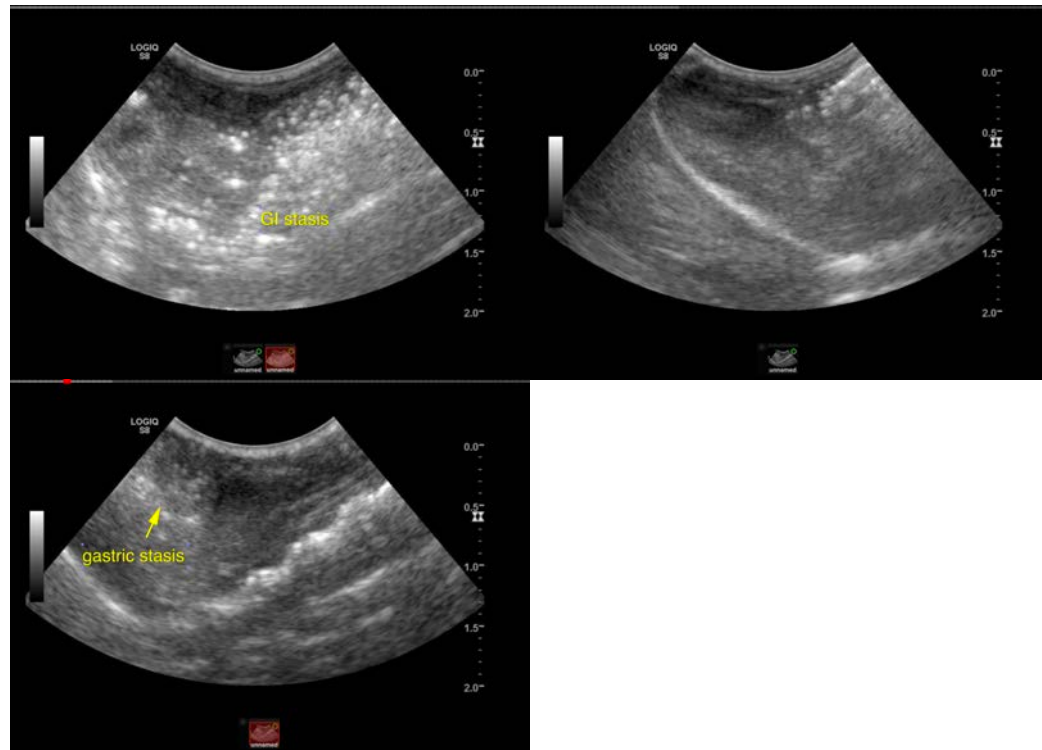
Dr. Agnes Rupley

INVOICE

41457

DATE

9/21/22



The information and recommendations provided are based on the images presented by the referring veterinarian/sonographer. No evaluation can be communicated regarding pathology that was not visible in the image/video clips provided.

Thank you for this referral. If the clinical or image interpretation does not parallel your findings or if I can be of any further assistance please contact me.

Eric Lindquist, DMV, DABVP, Cert. IVUSS, CEO of SonoPath.com

info@SonoPath.com