



**PATIENT PRESENTING CLINICAL SIGNS**

**Sasha Gibb** History: Doing well at home aside from marked arthritis. Screening blood work done prior to starting meds, and elevated liver values found so doing u/s Was on CBD but off of it for the past month. Not on any meds

**SPECIES** ALT-209, AlkP 1997, GGT 16, remainder of chem included Tbili and TT4 normal. CBC normal. U/A normal, USG 1.022

Canine

**BREED ULTRASONOGRAPHIC EXAMINATION OF THE ABDOMEN**

Husky Mix

**Urinary System**

The **urinary bladder**, trigone, and pelvic urethra presented normal thicknesses and normal tone. The ureters were not visible which is normal. No uroliths or sediment were visualized and anechoic urine was present. No evidence of inflammatory or neoplastic changes was noted. Ureteral papillae were normal.

**SEX**

Spayed Female

**AGE**

10 years

The **kidneys** revealed largely normal size and structure, corticomedullary definition and ratio (cortex 1/3 of medulla) were essentially maintained with some age-related loss of curvilinear patterns regarding the capsule and C/M junction. The cortices presented largely uniform texture with some increased echogenicity expected for this age patient. Medullary structure differed distinctly from that of the cortex and no evidence of pelvic dilation was present. Slight pinpoint mineralization was noted. The left kidney measured 6.0 cm.

**WEIGHT**

49 kg

**INTERPRETED BY**

Eric Lindquist, DMV  
DABVP, Cert. IVUSS

**Adrenal Glands**

The **adrenal glands** were not visualized.

**IMAGING PERFORMED BY**

Dr. Biederbeck

**Spleen**

The **spleen** in this patient was mildly enlarged with uniform parenchyma and was folded upon itself caudally. This is a positional variant and is not pathological. There was no evidence of significant disease.

**HOSPITAL NAME**

Lomsnes VH

**Liver**

The **liver** revealed minor coarse architecture with slight increased portal markings. The gallbladder was unremarkable with a trace amount of dependent debris.

**REFERRING VET**

Dr. Biederbeck

**Gastrointestinal**

**INVOICE**

91907

Examination of the **gastrointestinal tract** revealed a stomach and intestine free of stasis, of normal wall thickness, acceptable curvilinear mural detail, and peristaltic activity. Small and large intestine demonstrated normal luminal chyme and stool consistency respectively. The mesenteric lymph node was reactive and measured 0.5 cm.

**DATE**

9/21/21



**PATIENT**

**Pancreas**

Sasha Gibb

The base and limbs of the **pancreas** were observed to be largely isoechoic to surrounding omental fat. Pancreatic duct and capsular contour were acceptably normal and parenchyma respected normal curvilinear patterns. No overt evidence of active inflammatory or neoplastic disease was noted.

**SPECIES**

Canine

**ULTRASONOGRAPHIC FINDINGS**

**BREED**

Benign hepatopathy with an inflammatory component.

Husky Mix

**INTERPRETATION OF THE FINDINGS & FURTHER RECOMMENDATIONS**

**SEX**

Spayed Female

FNA of the liver could be considered for further definition. There is no evidence of neoplasia. If adrenal disease is suspected then imaging under sedation would be appropriate.

**AGE**

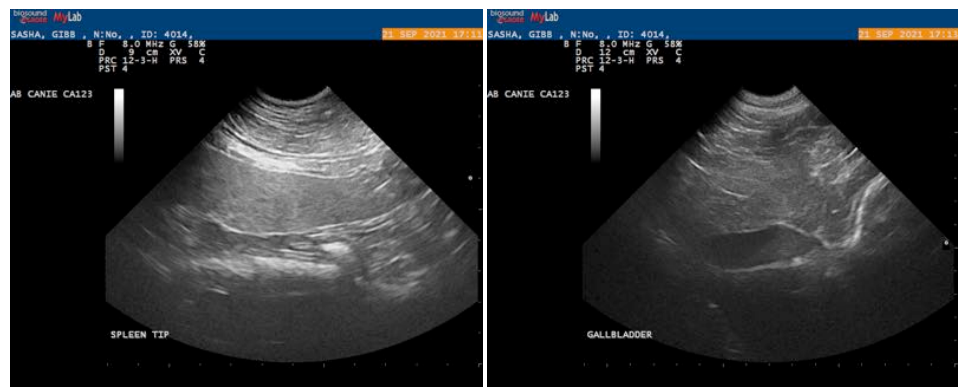
10 years

**WEIGHT**

49 kg

**INTERPRETED BY**

Eric Lindquist, DMV  
DABVP, Cert. IVUSS

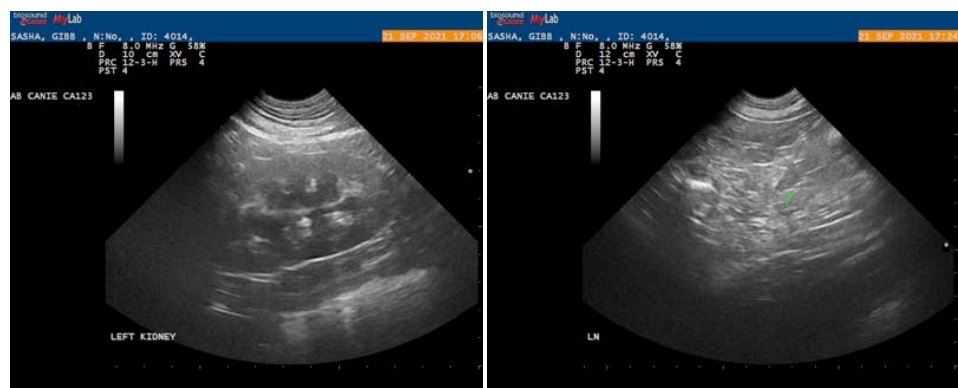


**IMAGING PERFORMED BY**

Dr. Biederbeck

**HOSPITAL NAME**

Lomsnes VH



**REFERRING VET**

Dr. Biederbeck

**INVOICE**

91907

The information and recommendations provided are based on the images presented by the referring veterinarian. No evaluation can be communicated regarding pathology that was not visible in the image/video clips provided.

**DATE**

9/21/21

Thank you for this referral. If the clinical or image interpretation does not parallel your findings or if I can be of any further assistance please contact me.



**PATIENT**

Sasha Gibb

**Eric Lindquist**, DMV, DABVP, Cert. IVUSS, CEO of SonoPath.com  
info@SonoPath.com

**SPECIES**

Canine

**BREED**

Husky Mix

**SEX**

Spayed Female

**AGE**

10 years

**WEIGHT**

49 kg

**INTERPRETED BY**

Eric Lindquist, DMV  
DABVP, Cert. IVUSS

**IMAGING  
PERFORMED BY**

Dr. Biederbeck

**HOSPITAL NAME**

Lomsnes VH

**REFERRING VET**

Dr. Biederbeck

**INVOICE**

91907

**DATE**

9/21/21