

**PATIENT PRESENTING CLINICAL SIGNS**

Sadie Carabello Repeat SAS.

**SPECIES ULTRASONOGRAPHIC EXAMINATION OF THE HEART**

Canine

**BREED**

Boxer

**SEX**

Spayed Female

**AGE**

9 years

**INTERPRETED BY**

Eric Lindquist, DMV  
DABVP, Cert. IVUSS

**IMAGING PERFORMED BY**

Eric Lindquist, DMV  
DABVP, Cert. IVUSS

**HOSPITAL NAME**

Franklin Lakes AH

**REFERRING VET ULTRASONOGRAPHIC FINDINGS**

Dr. Ward Compensated subaortic stenosis and boxer cardiomyopathy ARVC.

**INVOICE INTERPRETATION OF THE FINDINGS & FURTHER RECOMMENDATIONS**

91879 Anti-arrhythmic treatment is recommended. The patient is at a moderate anesthetic risk.

**DATE**

9/21/21

The echocardiogram in this patient revealed normal volumes in all four chambers. Left ventricular internal diameter was normal, however, contractility was mildly subnormal likely owing to the arrhythmia noted possible effects of boxer cardiomyopathy, yet no volume overload was noted. . Trivial mitral valve insufficiency was noted with a centralized jet. This is not clinically significant. The myocardium was unremarkable. The aortic velocity was excessive. This is consistent with subaortic stenosis, yet only mild form. The pulmonic outflow, tricuspid and right atrium were unremarkable. There was no pericardial or pleural effusion noted.

CANINE CARDIAC PARAMETERS	MR VMAX (m/s)	TR VMAX (m/s)	LA/AO (Boon method)	LA/AO (Heart Base; Swe)	FS (%)	EF (%)	EPSS (cm)
NORMAL PARAMETER	4.5-5.5	<2.7	1.3	<1.6	28-40	40-100	<0.6
PATIENT			1.3	1.5	18	38	0.2
CANINE CARDIAC PARAMETERS	HR (BPM)	AV VMAX (m/s)	PV MAX (m/s)	BODY WEIGHT (kg)	LA 2D short axis Base view (cm)	LVIDd Avg; 2D and m-mode short axis (cm)	LVIDs Avg; 2D and m-mode short axis (cm)
NORMAL PARAMETER	50-100	0.7-1.7	0.7-1.6				
PATIENT	166	3.0	1.15		4.23 max	3.6	



**PATIENT**

Sadie Carabello

**SPECIES**

Canine

**BREED**

Boxer

**SEX**

Spayed Female

**AGE**

9 years

**INTERPRETED BY**

Eric Lindquist, DMV  
DABVP, Cert. IVUSS

**IMAGING PERFORMED BY**

Eric Lindquist, DMV  
DABVP, Cert. IVUSS

**HOSPITAL NAME**

Franklin Lakes AH

**REFERRING VET**

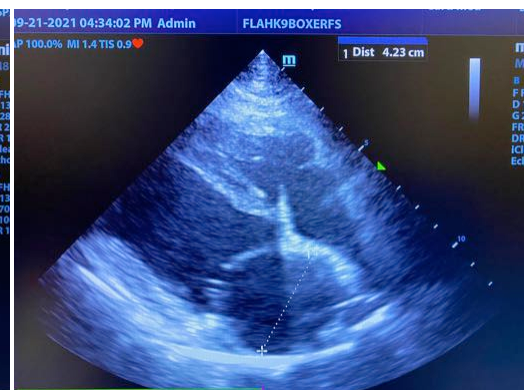
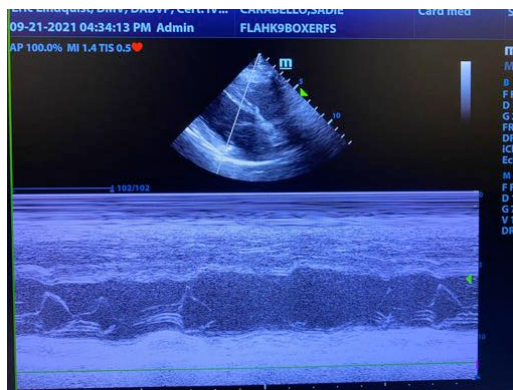
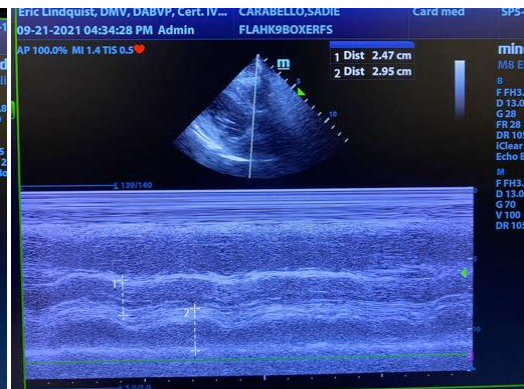
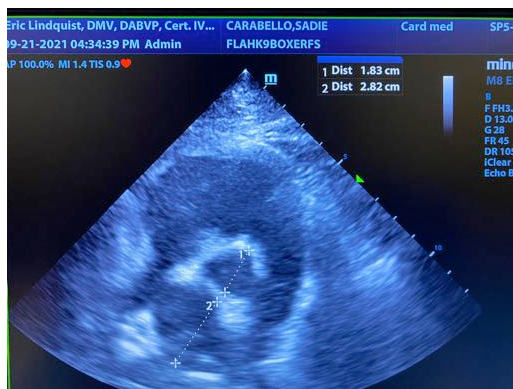
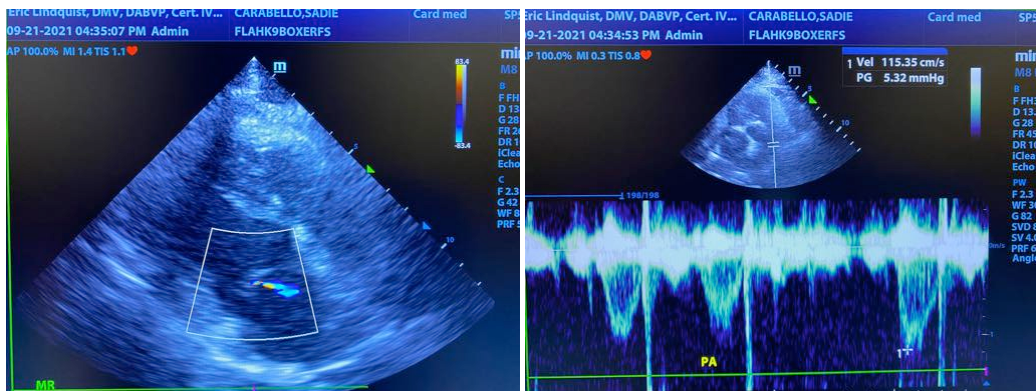
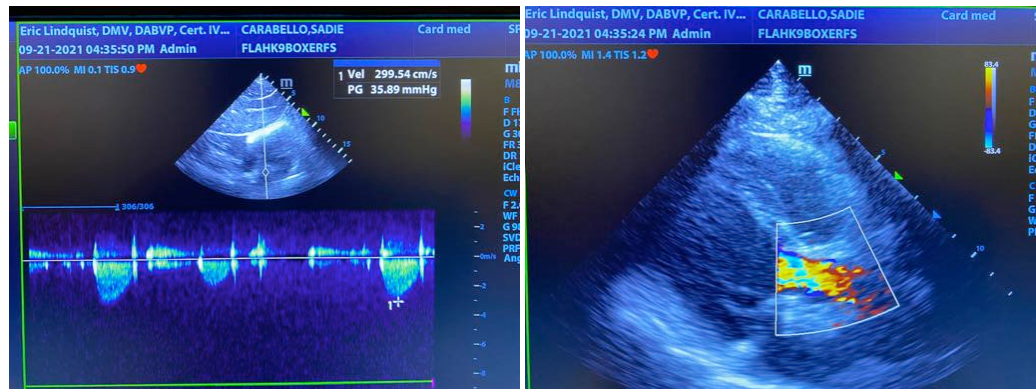
Dr. Ward

**INVOICE**

91879

**DATE**

9/21/21





**PATIENT**

Sadie Carabello

**SPECIES**

Canine

**BREED**

Boxer

**SEX**

Spayed Female

**AGE**

9 years

**INTERPRETED BY**

Eric Lindquist, DMV  
DABVP, Cert. IVUSS

**IMAGING PERFORMED BY**

Eric Lindquist, DMV  
DABVP, Cert. IVUSS

**HOSPITAL NAME**

Franklin Lakes AH

**REFERRING VET**

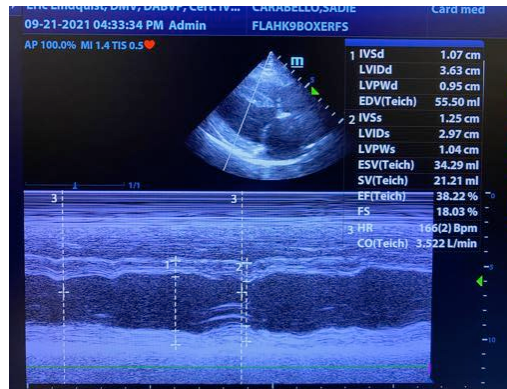
Dr. Ward

**INVOICE**

91879

**DATE**

9/21/21



The information and recommendations provided are based on the images presented by the referring veterinarian. No evaluation can be communicated regarding pathology that was not visible in the image/video clips provided.

Thank you for this referral. If the clinical or image interpretation does not parallel your findings or if I can be of any further assistance please contact me.

**Eric Lindquist, DMV, DABVP, Cert. IVUSS, CEO of SonoPath.com**  
Info@SonoPath.com