



PATIENT PRESENTING CLINICAL SIGNS

Abby Miller

History: Texas rescue at 7mo of age, Negative HWT 4/2020 at 13mo. of age and preventative started then, tested positive on 2 different snap tests and on ELISA, negative microfilaria test. Very active and no symptoms. Owner wanting to establish worm burden and heart health.

SPECIES

Canine

Abnormal PE/Chem/CBC/UA Results: PE: Fractured 104 to gum line, right grade 1 medial patella luxation, over weight. No recent labs other than heart worm test. Positive 4Dx, Positive ELISA, Negative Microfilaria check.

BREED

Coonhound

ULTRASONOGRAPHIC EXAMINATION OF THE HEART

SEX

Spayed Female

The echocardiogram in this patient demonstrated normal **left atrial** size based on 3 separate methods of LA evaluation. The cranial and caudal **mitral** valve leaflets presented normal linear structure, extension in systole, and union in diastole with normal kinesis. The **left ventricle** presented thicknesses with linear contour and was not dilated nor restricted. The **myocardium** presented normal echogenicity without subjective evidence of significant fibrotic or ischemic disease. **Contractility** of the ventricular walls was adequate and in normal range for this patient evidenced by the fractional shortening measurement and subjective evaluation of the different regions of the myocardium. The **left ventricular outflow** tract demonstrated normal laminar flow and subjective structural integrity. The **right atrium** and auricle revealed normal size, structure and content. No evidence of masses was noted. **Tricuspid** valvular assessment demonstrated adequate linear morphology and kinesis. The **right ventricle** was of normal size (1/3 diameter of LV), chordae structure, myocardial echogenicity and thickness. **Pulmonary outflow** tract assessment revealed normal valve structure, laminar flow, and diameter (approx.1:1 pa/ao ratio). No visible **pericardial** or free pleura fluid was noted. The cranial **mediastinum and pericardial and extra-cardiac regions** were free of masses in the visible window.

AGE

2 ½ years

WEIGHT

48.2 lbs

INTERPRETED BY

Eric Lindquist, DMV
DABVP, Cert. IVUSS

IMAGING PERFORMED BY

Dr. Anderson

HOSPITAL NAME

Elizabeth AH

REFERRING VET

Dr. Anderson

CANINE CARDIAC PARAMETERS	MR VMAX (m/s)	TR VMAX (m/s)	LA/AO (Boon method)	LA/AO (Heart Base; Swe)	FS (%)	EF (%)	EPSS (cm)
NORMAL PARAMETER	4.5-5.5	<2.7	1.3	<1.6	28-40	40-100	<0.6
PATIENT			1.3	1.3	40	73	NM
CANINE CARDIAC PARAMETERS	HR (BPM)	AV VMAX (m/s)	PV MAX (m/s)	BODY WEIGHT (kg)	LA (2D short axis Base view) (cm)	LVIDd (Avg; 2D and m-mode short axis) (cm)	LVIDs (Avg; 2D and m-mode short axis) (cm)
NORMAL PARAMETER	50-100	0.7-1.7	0.7-1.6				
PATIENT		1.74	0.94	48.2 lbs	3.21 max	3.23	

INVOICE

91893

DATE

9/21/21



PATIENT

ULTRASONOGRAPHIC FINDINGS

Abby Miller

Normal echocardiogram.

SPECIES

INTERPRETATION OF THE FINDINGS & FURTHER RECOMMENDATIONS

Canine

There is no evidence of heartworms, structural or functional disease.

BREED

Coonhound

SEX

Spayed Female

AGE

2 ½ years

WEIGHT

48.2 lbs

INTERPRETED BY

Eric Lindquist, DMV
DABVP, Cert. IVUSS

IMAGING PERFORMED BY

Dr. Anderson

HOSPITAL NAME

Elizabeth AH

REFERRING VET

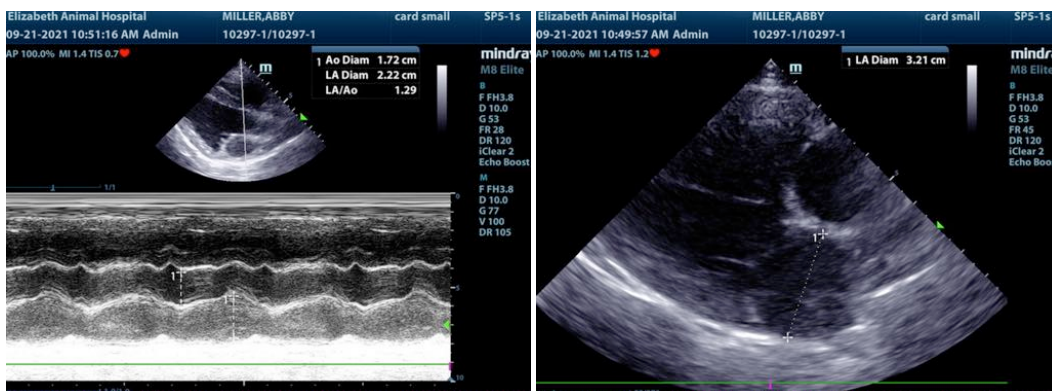
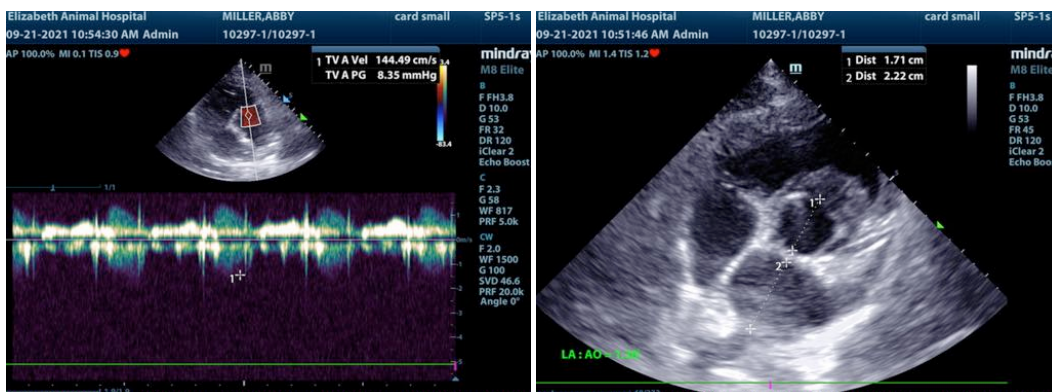
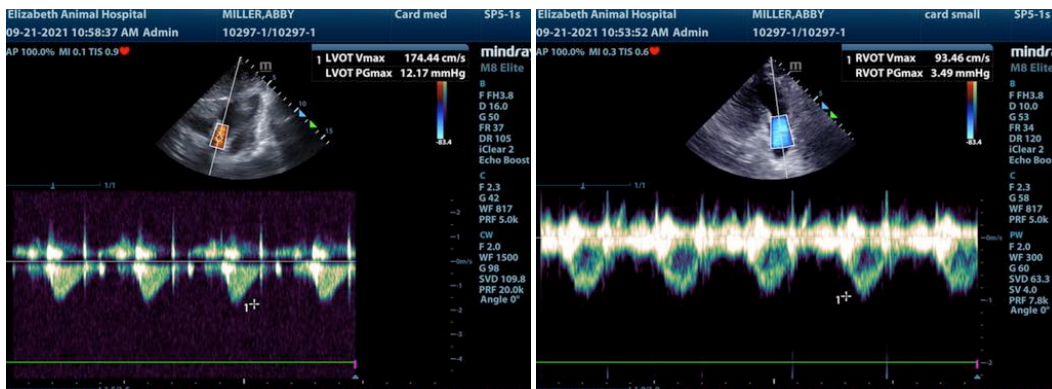
Dr. Anderson

INVOICE

91893

DATE

9/21/21





PATIENT

Abby Miller

SPECIES

Canine

BREED

Coonhound

SEX

Spayed Female

AGE

2 ½ years

WEIGHT

48.2 lbs

INTERPRETED BY

Eric Lindquist, DMV
DABVP, Cert. IVUSS

IMAGING PERFORMED BY

Dr. Anderson

HOSPITAL NAME

Elizabeth AH

REFERRING VET

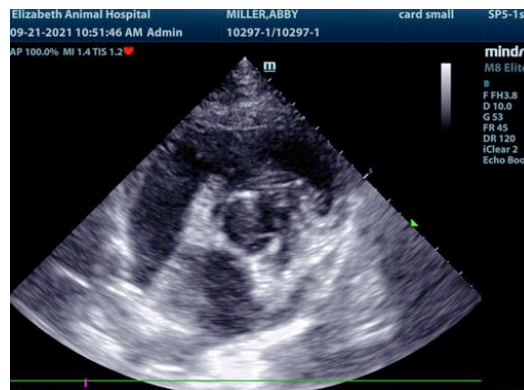
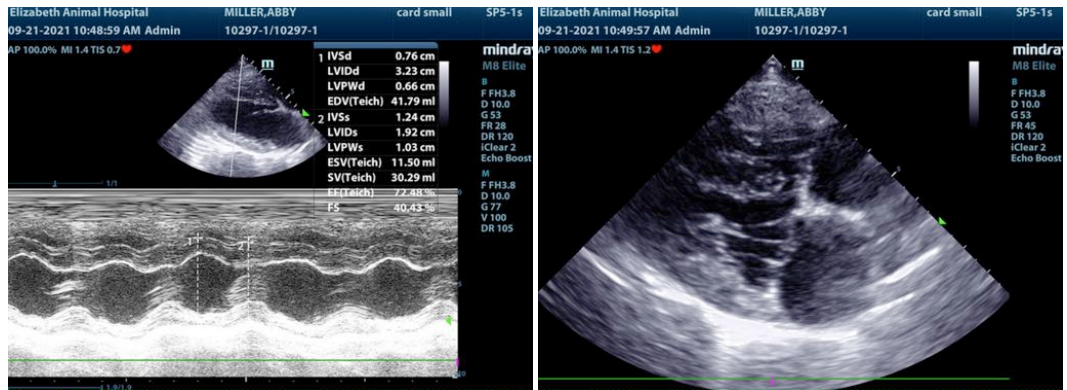
Dr. Anderson

INVOICE

91893

DATE

9/21/21



The information and recommendations provided are based on the images presented by the referring veterinarian. No evaluation can be communicated regarding pathology that was not visible in the image/video clips provided.

Thank you for this referral. If the clinical or image interpretation does not parallel your findings or if I can be of any further assistance please contact me.

Eric Lindquist, DMV, DABVP, Cert. IVUSS, CEO of SonoPath.com
info@SonoPath.com