



**PATIENT**

Sarge Save A Soul  
Rescue North

**SPECIES**

Canine

**BREED**

Pit Mix

**SEX**

Neutered male

**AGE**

8 years

**WEIGHT**

84.8 lbs

**INTERPRETED BY**

Eric Lindquist, DMV  
DABVP, Cert. IVUSS

**IMAGING PERFORMED BY**

Dr. Waffle

**HOSPITAL NAME**

Torch Lake VC

**REFERRING VET**

Dr. Waffle

**INVOICE**

91833

**DATE**

9/20/21

**PRESENTING CLINICAL SIGNS**

History: Owner has been treating for sialadenosis/ She is currently treating with 300 mg doxycycline BID and 20 mg pred SID

Abnormal PE/Chem/CBC/UA Results: L head tilt. Tongue deviated to L. Reduce abduction. respiratory stridor and decreased gag. Thoracic rads show no evidence of neoplastic disease (met check). Blood work in April showed elevated ALT 149. CBC normal

**ULTRASONOGRAPHIC EXAMINATION OF THE THYROID**

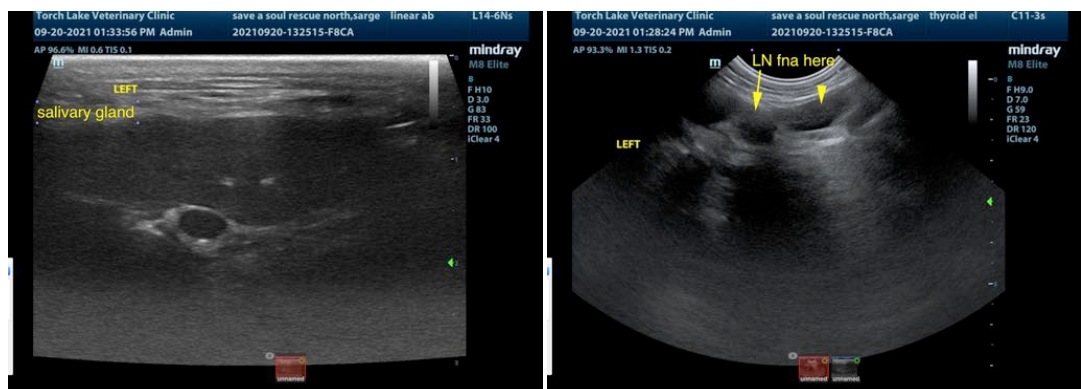
The left thyroid region revealed a disruptive 3.0 x 2.5 cm, mixed, hypoechoic mass with regional inflammation and lymphadenopathy. The mass appeared to infiltrate regional tissues with inflammation extending into the salivary glands. The left thyroid region, salivary gland and regional tissues appeared unremarkable.

**ULTRASONOGRAPHIC FINDINGS**

Undefined mass in the left thyroid region. Suspect thyroid carcinoma with potential lymphadenopathy, granulomatous disease is possible.

**INTERPRETATION OF THE FINDINGS & FURTHER RECOMMENDATIONS**

Ultrasound-guided FNA of the lymph nodes and mass as well as cytology and culture is recommended. The prognosis is guarded. This does not appear overtly surgical. CT of the region with contrast would be the gold standard.





**PATIENT**

Sarge Save A Soul  
Rescue North

**SPECIES**

Canine

**BREED**

Pit Mix

**SEX**

Neutered male

**AGE**

8 years

**WEIGHT**

84.8 lbs

**INTERPRETED BY**

Eric Lindquist, DMV  
DABVP, Cert. IVUSS

**IMAGING  
PERFORMED BY**

Dr. Waffle

**HOSPITAL NAME**

Torch Lake VC

**REFERRING VET**

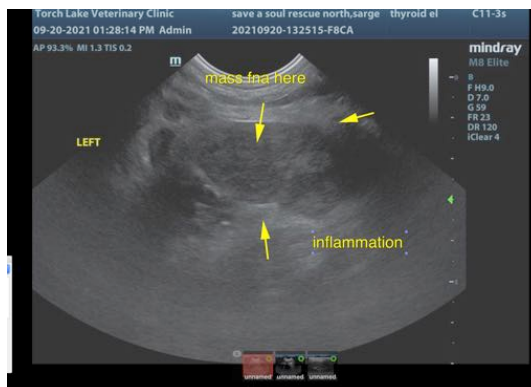
Dr. Waffle

**INVOICE**

91833

**DATE**

9/20/21



The information and recommendations provided are based on the images presented by the referring veterinarian. No evaluation can be communicated regarding pathology that was not visible in the image/video clips provided.

Thank you for this referral. If the clinical or image interpretation does not parallel your findings or if I can be of any further assistance please contact me.

**Eric Lindquist**, DMV, DABVP, Cert. IVUSS, CEO of SonoPath.com  
info@SonoPath.com