



PATIENT

Mason Jenkins

SPECIES

Canine

BREED

Miniature Schnauzer

SEX

Neutered male

AGE

5 years

WEIGHT

13 lbs

INTERPRETED BY

Eric Lindquist, DMV
DABVP, Cert. IVUSS

IMAGING PERFORMED BY

Dr. Leal

HOSPITAL NAME

Blairstown AH

REFERRING VET

Dr. Leal

INVOICE

91839

DATE

9/20/21

PRESENTING CLINICAL SIGNS

History: Dog presented ADR. Dog yelps sometimes when picked up. Dog somewhat bloated (new symptom). Not eating well and more lethargic. Has some loose stool. Bloodwork essentially WNL

ULTRASONOGRAPHIC EXAMINATION OF THE ABDOMEN

Urinary System

The **urinary bladder**, trigone, and pelvic urethra presented normal thicknesses and normal tone. The ureters were not visible which is normal. No uroliths or sediment were visualized and anechoic urine was present. No evidence of inflammatory or neoplastic changes was noted. Ureteral papillae were normal.

The **kidneys** revealed normal size and structure, corticomedullary definition and ratio for this age. The cortices presented largely uniform texture with normal echogenic relationship to liver and spleen. Medullary structure differed distinctly from the cortex and no evidence of pelvic dilation was present. The capsules were acceptably uniform without significant irregularities. The right kidney measured 4.5 cm. The left kidney measured 4.5 cm.

Adrenal Glands

Both **adrenal glands** were visualized and recognized as having normal shape, size, position and echogenicity for this breed. The phrenic vasculature, glandular echogenicity and detail were unremarkable. Capsule, cortex, and medullary definition were normal for this age patient. The left adrenal gland measured 0.4 cm. The right adrenal gland measured 0.8 cm at the cranial pole and 0.5 cm at the caudal pole.

Spleen

The **spleen** was uniformly enlarged with relatively uniform parenchyma without evidence of masses. The spleen was folded upon itself caudally. The capsule was mildly swollen. This is most consistent with hypersplenism and reactive hyperplasia deriving from splenic white or red pulp. However, early infiltrative disease, such as lymphoma or mast cell neoplasia can, at times, present in this manner. True hypersplenism from an internal medicine standpoint causes sequestering of thrombocytes resulting in thrombocytopenia and anemia. Clinical manifestation of this phenomenon should be considered. US-guided FNA would be best in order to ensure only reactive hyperplasia is present. If clinical signs fit with potential neoplasia or mast cell disease, then Benadryl injection (1 mg/pound IM) 15 minutes prior to FNA would be recommended.

Liver

The **liver** images submitted revealed subjectively normal liver size, contour, and structure. Parenchymal echogenicity was naturally coarse and hypoechoic to the spleen. Vascular and biliary tracts were of normal volume with no evidence of congestion. The gallbladder presented acceptably thin walls with primarily anechoic content. The cystic and common bile ducts were normal. No pathological hepatic



PATIENT

Mason Jenkins

lymphadenopathy was evident. No overt structural evidence of inflammatory, infiltrative or regenerative pathology was evident.

SPECIES

Canine

Gastrointestinal

Examination of the **gastrointestinal tract** revealed a stomach and intestine free of stasis, of normal wall thickness, acceptable curvilinear mural detail, and peristaltic activity. Small and large intestine demonstrated normal luminal chyme and stool consistency respectively. No obstructive or overt infiltrative disease was noted. No associated abnormal lymphatic activity was noted.

BREED

Miniature Schnauzer

Pancreas

SEX

Neutered male

The base and limbs of the **pancreas** were observed to be largely isoechoic to surrounding omental fat. Pancreatic duct and capsular contour were acceptably normal and parenchyma respected normal curvilinear patterns. No overt evidence of active inflammatory or neoplastic disease was noted.

AGE

5 years

ULTRASONOGRAPHIC FINDINGS

Normal abdomen.

WEIGHT

13 lbs

INTERPRETATION OF THE FINDINGS & FURTHER RECOMMENDATIONS

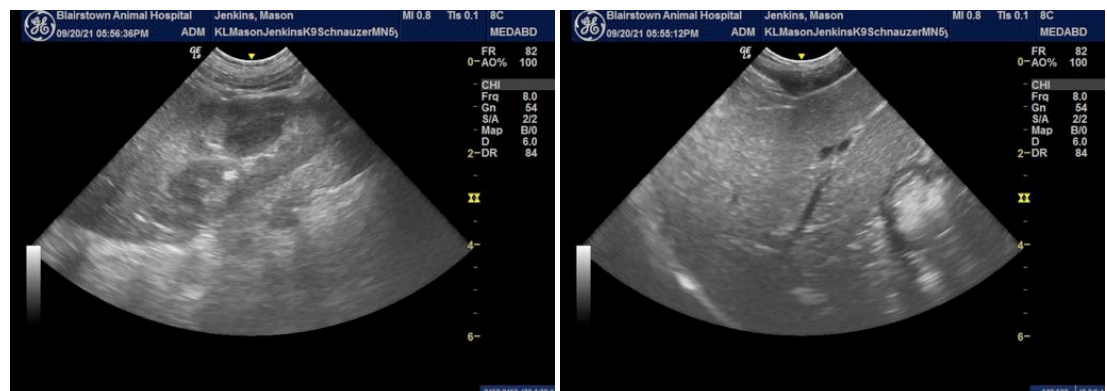
INTERPRETED BY

Eric Lindquist, DMV
DABVP, Cert. IVUSS

There was no evidence of visceral pathology responsible for the clinical signs. Orthopedic/spinal pain referred pain causing tense abdomen may be the issue in this patient. There was no evidence of visceral disease.

IMAGING PERFORMED BY

Dr. Leal



HOSPITAL NAME

Blairstown AH

REFERRING VET

Dr. Leal

INVOICE

91839

DATE

9/20/21



PATIENT

Mason Jenkins

SPECIES

Canine

BREED

Miniature Schnauzer

SEX

Neutered male

AGE

5 years

WEIGHT

13 lbs

INTERPRETED BY

Eric Lindquist, DMV
DABVP, Cert. IVUSS

IMAGING PERFORMED BY

Dr. Leal

HOSPITAL NAME

Blairstown AH

REFERRING VET

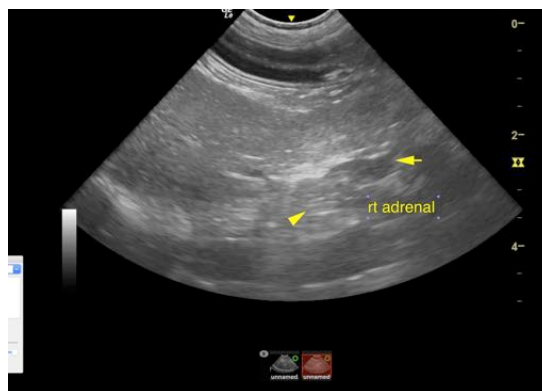
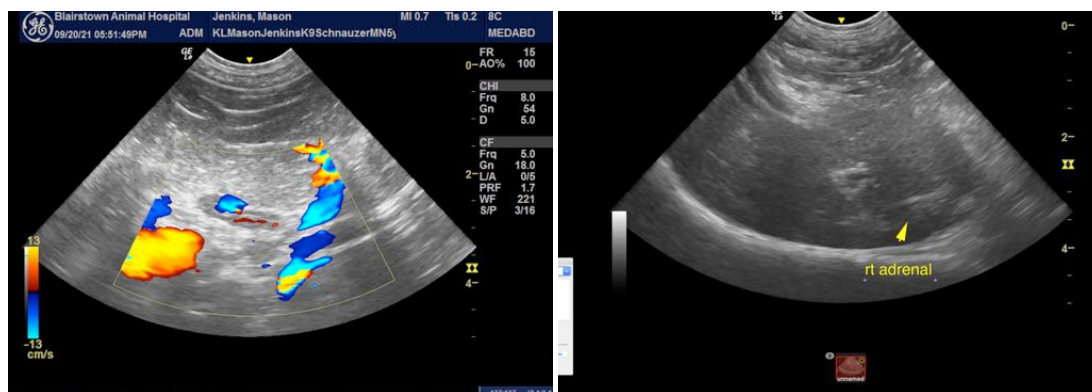
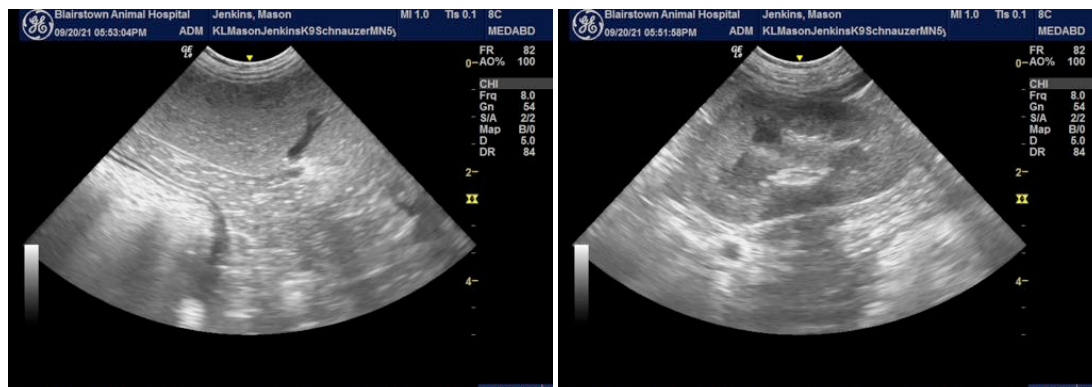
Dr. Leal

INVOICE

91839

DATE

9/20/21



The information and recommendations provided are based on the images presented by the referring veterinarian. No evaluation can be communicated regarding pathology that was not visible in the image/video clips provided.

Thank you for this referral. If the clinical or image interpretation does not parallel your findings or if I can be of any further assistance please contact me.

Eric Lindquist, DMV, DABVP, Cert. IVUSS, CEO of SonoPath.com
info@SonoPath.com