



**PATIENT**

Coco Castellanos

**SPECIES**

Canine

**BREED**

Fench Bulldog

**SEX**

Spayed Female

**AGE**

2 years

**WEIGHT**

18.9 lbs

**INTERPRETED BY**

Eric Lindquist, DMV  
DABVP, Cert. IVUSS

**IMAGING PERFORMED BY**

Dr. Barnea

**HOSPITAL NAME**

Tenaflly VC

**REFERRING VET**

Dr. Barnea

**INVOICE**

91835

**DATE**

9/20/21

**PRESENTING CLINICAL SIGNS**

History: ectopic ureter and single left kidney pet had corrective laser sx at AMC 1 month ago but seems to be doing same, not better currently on proin cc lethargic, depraved appetite but seem fine today on exam bw/ua collected today been on/off on ab for chronic UTI for many months us done at request of AMC

**ULTRASONOGRAPHIC EXAMINATION OF THE ABDOMEN**

**Urinary System**

The **urinary bladder**, trigone, and pelvic urethra presented normal thicknesses and normal tone. The pelvic urethra was imaged 1.0 cm beyond the cystourethral junction. The ureters were not visible which is normal. No uroliths or sediment were visualized and anechoic urine was present. No evidence of inflammatory or neoplastic changes was noted. Ureteral papillae were normal.

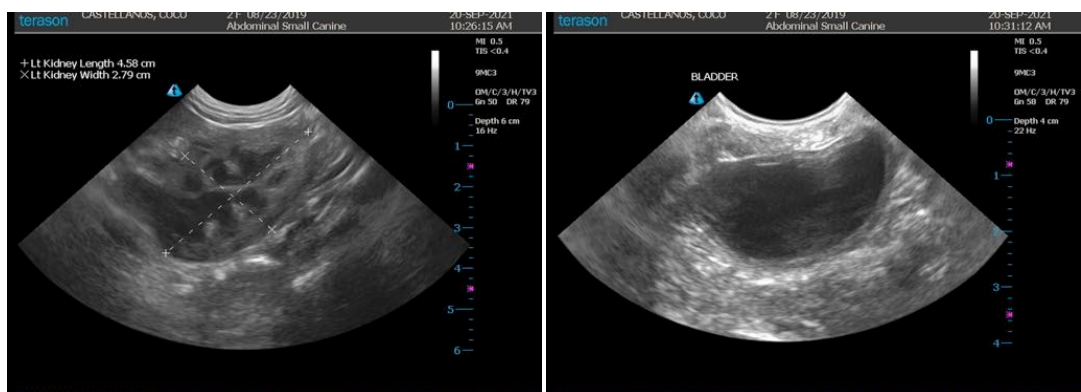The **left kidney** revealed normal size and structure, corticomedullary definition and ratio for this age. The cortices presented largely uniform texture with normal echogenic relationship to liver and spleen. Medullary structure differed distinctly from the cortex and no evidence of pelvic dilation was present. The capsule was acceptably uniform without significant irregularities. The left kidney measured 4.58 cm.

**ULTRASONOGRAPHIC FINDINGS**

Structurally normal urinary tract.

**INTERPRETATION OF THE FINDINGS & FURTHER RECOMMENDATIONS**

There was no evidence of residual pathology. Single left kidney appeared normal in size and contour. There was no evidence of residual pathology.





**PATIENT**

Coco Castellanos

**SPECIES**

Canine

**BREED**

Fench Bulldog

**SEX**

Spayed Female

**AGE**

2 years

**WEIGHT**

18.9 lbs

**INTERPRETED BY**

Eric Lindquist, DMV  
DABVP, Cert. IVUSS

**IMAGING PERFORMED BY**

Dr. Barnea

**HOSPITAL NAME**

Tenaflly VC

**REFERRING VET**

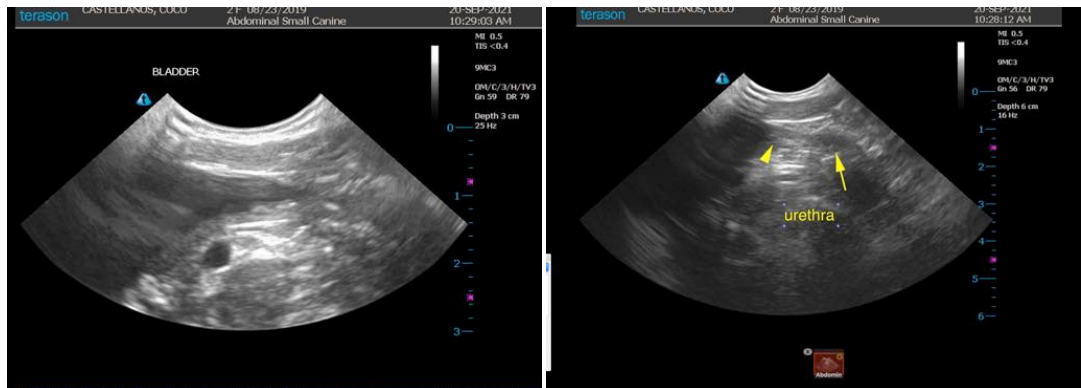
Dr. Barnea

**INVOICE**

91835

**DATE**

9/20/21



The information and recommendations provided are based on the images presented by the referring veterinarian. No evaluation can be communicated regarding pathology that was not visible in the image/video clips provided.

Thank you for this referral. If the clinical or image interpretation does not parallel your findings or if I can be of any further assistance please contact me.

**Eric Lindquist, DMV, DABVP, Cert. IVUSS, CEO of SonoPath.com**  
info@SonoPath.com