IMAGING PERFORMED BY

IntraPet.com

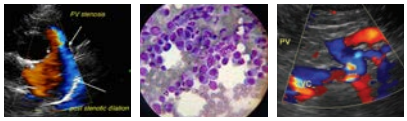

SonoPath
Clinical Sonography & Telecytology
EDUCATIONAL TELECONSULTATION SERVICES™
1-800-838-4268 info@sonopath.com SonoPath.com

DATE

9/2/22

PATIENT

Zoey Dirocco

SPECIES

Canine

BREED

Norwegian Elkhound

SEX

Spayed Female

AGE

12/1/18

WEIGHT

74.4 Pounds

INTERPRETED BY

Eric Lindquist, DMV
DABVP, Cert. IVUSS

IMAGING PERFORMED BY

Rachel Brilhart RDMS

HOSPITAL NAME

Animal Emergency Hospital

REFERRING VET

Dr. Thompson

INVOICE

41016

PRESENTING CLINICAL SIGNS

Zoey is a 3 y/o FS Norwegian Elkhound who presents for vomiting - hospitalized 8/26 for referral for food bloat, got into 9 cups of puppy food and pizza - Hx lethargy and weight gain, eating a mouse; tapeworms- treated, skin irritation- vaginal- gives Zyrtec - since discharge, Sunday was more tired - diarrhea consistent, yellow, asking to go out more, straining with low production, mucus/jelly, no blood, no FM, low volume - has been on a bland diet, tried to mix in with kibble, has had an appetite - more food going in then coming out - Monday vomited again, withheld food, has been feeding QID - Tuesday/Wednesday did not vomit, vomited yesterday evening - had more energy then prior to presenting but not back normal - would miss a step going up steps - vomited twice today, confirmed vomiting vs regurgitation Medications: - Omeprazole Capsules 40 mg BID still on got this am - Metoclopramide Tablets 10mg TID no longer on - Gabapentin Capsules 300mg TID still on got this am - proviable still on, did get this am - previous Zyrtec BW at RDVM 8/26: HCT 35.6%, Bun 41, Chol 366, Amy 423, Lipase 2434, 4dx negative BW 8/27: Bun 21 Thyroid panel: TT4 <0.4 (L), Free T4 0.3 (L), Free T4 by ED 3.9 (L), cTSH 2.06 (H)

Current Medications: Buprenorphine, Ondansetron, Proviable, Metoclopramide, Omeprazole.
Lab Results: See attached.
Date of Previous IntraPet Ultrasound: No previous.
Sedation: Not required to complete full diagnostic ultrasound.
Stat Report: Not requested.

ULTRASONOGRAPHIC EXAMINATION OF THE ABDOMEN

Urinary System

The **urinary bladder**, trigone, and pelvic urethra presented normal thicknesses and normal tone. The ureters were not visible which is normal. No uroliths or sediment were visualized and anechoic urine was present. No evidence of inflammatory or neoplastic changes were noted. Ureteral papillae were normal.

The **kidneys** revealed normal size and structure, corticomedullary definition and ratio for this age. The cortices presented largely uniform texture with normal echogenic relationship to liver and spleen. Medullary structure differed distinctly from the cortex and no evidence of pelvic dilation was present. The capsules were acceptably uniform without significant irregularities. The right kidney measured 6.42 cm. The left kidney measured 6.11 cm.

Adrenal Glands

Both **adrenal glands** were visualized and recognized as having normal shape, size, position and echogenicity for this breed. The phrenic vasculature, glandular echogenicity and detail were unremarkable. Capsule, cortex, and medullary definition were normal for this age patient. The right adrenal gland measured 3.33 cm x 0.72 cm at the caudal pole and 0.87 cm at the cranial pole. The left adrenal gland measured 2.58 cm x 0.64 cm at the caudal pole and 0.56 cm at the cranial pole.

Spleen

The **spleen** presented a smooth homogeneous parenchyma hyperechoic to liver and renal cortical parenchyma. The capsule was smooth without noticeable expansion or deviation from within the spleen or adjacent pathology. The splenic vasculature demonstrated normal volume without signs of congestion or thrombosis. No sonographic evidence of acute or chronic inflammatory, neoplastic, or infarctual changes were noted.

Liver

The **liver** was slightly coarse in architecture, mildly hyperechoic to falciform fat. The gallbladder and common bile duct were unremarkable. History of hepatic insult likely. Appears stable.

Gastrointestinal

Examination of the **gastrointestinal tract** revealed a stomach and intestine free of stasis, of normal wall thickness, acceptable curvilinear mural detail, and peristaltic activity. Minor gastric artifact noted, no evidence of foreign bodies. Small and large intestine demonstrated normal luminal chyme and stool consistency respectively. No obstructive or overt infiltrative disease was noted. No associated abnormal lymphatic activity was noted.

Pancreas

The **pancreas** revealed slight heterogeneous parenchymal changes. No evidence of significant active disease. However, low-grade inflammation cannot be ruled out.

ULTRASONOGRAPHIC FINDINGS

- Mildly hyperechoic liver
- Slight heterogeneous pancreas

INTERPRETATION OF THE FINDINGS & FURTHER RECOMMENDATIONS

Supportive care should prove effective.

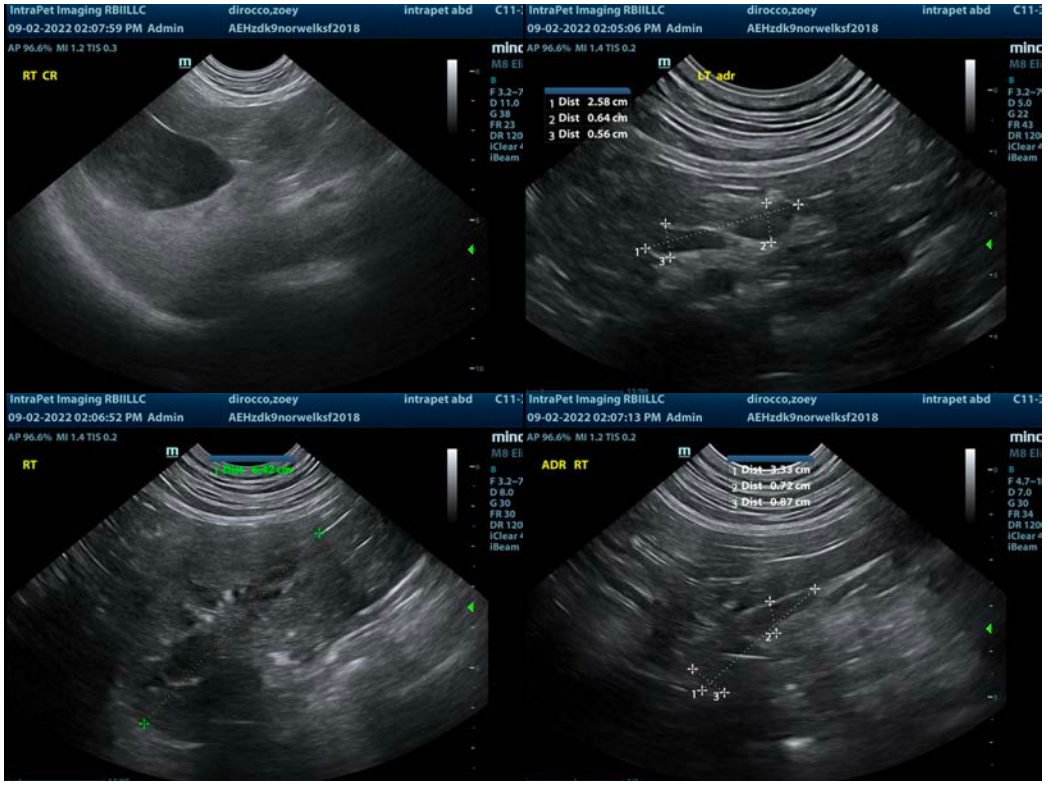

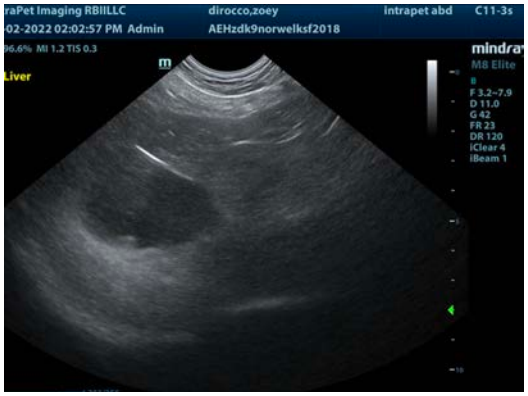

The information and recommendations provided are based on the images presented by the referring veterinarian/sonographer. No evaluation can be communicated regarding pathology that was not visible in the image/video clips provided.

Thank you for this referral. If the clinical or image interpretation does not parallel your findings or if I can be of any further assistance please contact me.

Eric Lindquist, DMV, DABVP, Cert. IVUSS, CEO of SonoPath.com
info@SonoPath.com