

**DATE**

9/2/22

PATIENT

Noah Cornish

SPECIES

Canine

BREED

Yorkshire Terrier

SEX

Neutered Male

AGE

7/10/08

WEIGHT

3.45 kg

INTERPRETED BYEric Lindquist, DMV
DABVP, Cert. IVUSS**IMAGING PERFORMED BY**

Andi Parkinson RDMS

HOSPITAL NAME

Banfield Timonium

REFERRING VET

Dr. Kameka

INVOICE

41028

PRESENTING CLINICAL SIGNS

Persistent cough for over a year, exacerbated by increased activity/ excitement. Newly heard grade 2/6 systolic heart murmur, PMI left apex.
Hepatic enlargement. Currently being treated for UTI.

Current Medications: Hydrocodone, Theophylline, Amoxicillin x 10 days.

Radiographs: 1) Rule out cervical tracheal collapse. 2) Left atrial enlargement secondary to chronic mitral endocardiosis without signs of CHF. Rule out tricuspid endocardiosis with post-capillary pulmonary hypertension. 3) Hepatomegaly: Metabolic vs Vacuolar infiltration vs Hepatic nodular hyperplasia vs Inflammatory vs Toxic vs Neoplastic or a combination of these differentials

Date of Previous IntraPet Ultrasound: No previous.

Sedation: Not required to complete full diagnostic ultrasound.

Stat Report: Not requested.

ULTRASONOGRAPHIC EXAMINATION OF THE ABDOMEN**Urinary System**

The **urinary bladder** revealed apical polypoid changes with a mural cyst that measured 0.39 cm at the dorsal wall.

The **kidneys** revealed largely normal size and structure, corticomedullary definition and ratio (cortex 1/3 of medulla) were essentially maintained with some age-related loss of curvilinear patterns regarding the capsule and C/M junction. The cortices presented largely uniform texture with some increased echogenicity expected for his age patient. Medullary structure differed distinctly from that of the cortex and no evidence of pelvic dilation was present. The right kidney measured 3.65 cm. The left kidney measured 3.57 cm.

Adrenal Glands

The **right adrenal gland** was heterogeneous and measured 2.02 cm x 0.81 cm at the caudal pole and 0.57 cm at the cranial pole.

The **left adrenal gland** was uniform and measured 1.43 cm x 0.61 cm at the cranial pole and 0.47 cm at the caudal pole.

Spleen

The **spleen** presented a smooth homogeneous parenchyma hyperechoic to liver and renal cortical parenchyma. The capsule was smooth without noticeable expansion or deviation from within the spleen or adjacent pathology. The splenic vasculature demonstrated normal volume without signs of congestion or thrombosis. No sonographic evidence of acute or chronic inflammatory, neoplastic, or infarctual changes were noted.

Liver

The **liver** presented heterogenous parenchyma with increased portal markings and coarse architecture. Slight undulating capsular contour was noted. An isoechoic nodule was noted in the left cranial liver, measuring 2.0 cm. The nodule impinged upon the gallbladder medially. Likely hyperplasia, however FNA warranted given that there are minor areas of mineralization noted on the nodule. The **gallbladder** was mildly over distended with suspended and dependent debris, yet not to the level of emerging mucocele, yet sludge appears to be mildly excessive. No adjunctive inflammation was noted. This is consistent with chronic inflammatory hepatopathy. Gallbladder polyps and mural cyst also noted.

Gastrointestinal

Examination of the **gastrointestinal tract** revealed a stomach and intestine free of stasis, of normal wall thickness, acceptable curvilinear mural detail, and peristaltic activity. Small and large intestine demonstrated normal luminal chyme and stool consistency respectively. No obstructive or overt infiltrative disease was noted. No associated abnormal lymphatic activity was noted.

Pancreas

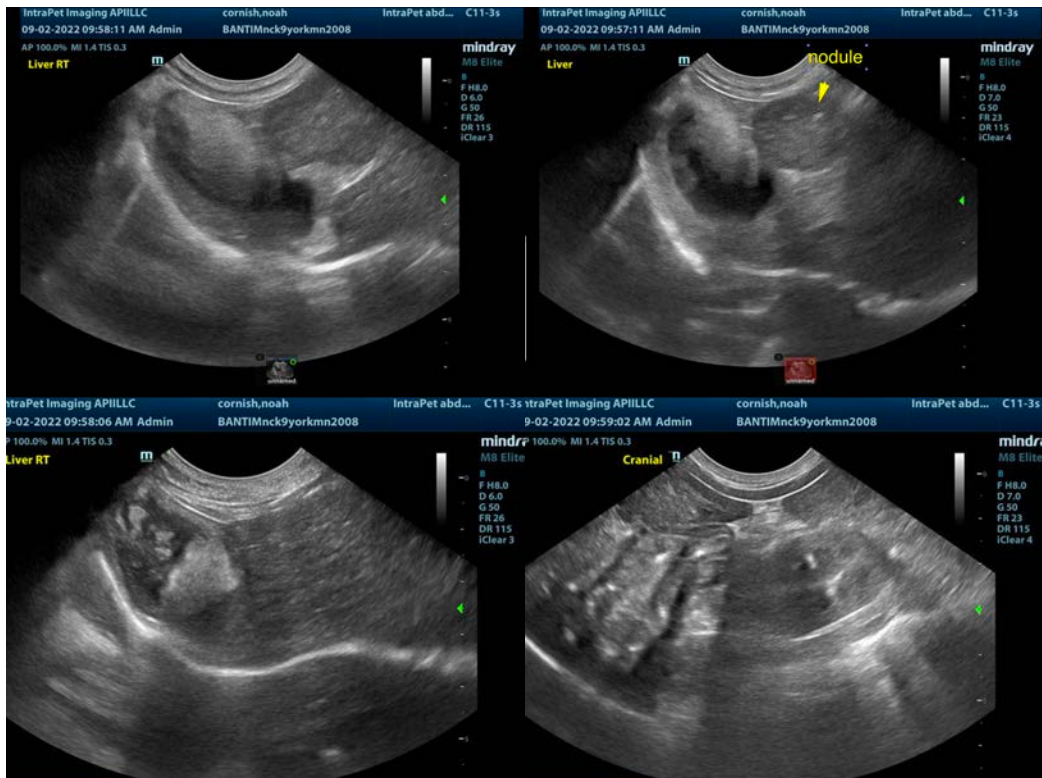
The base and limbs of the **pancreas** were observed to be largely isoechoic to surrounding omental fat. Pancreatic duct and capsular contour were acceptably normal and parenchyma respected normal curvilinear patterns. No overt evidence of active inflammatory or neoplastic disease was noted.

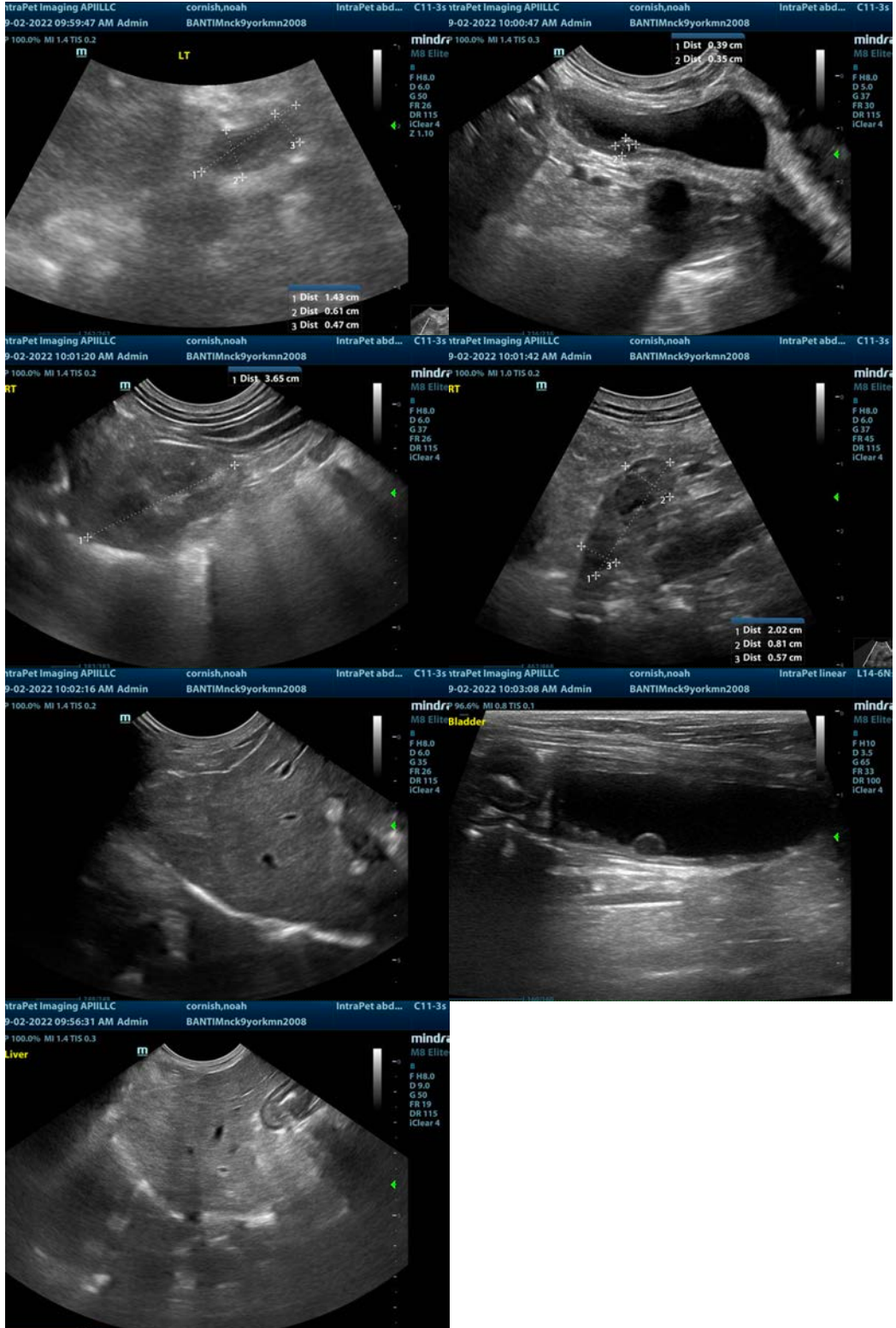
ULTRASONOGRAPHIC FINDINGS

- Hepatic remodeling with isoechoic nodule – pronounced nodular hyperplasia likely, carcinoma possible. Microvascular dysplasia/portal vein hypoplasia also possible given the breed.
- Gallbladder polyps and mural cyst
- Heterogeneous right adrenal gland

INTERPRETATION OF THE FINDINGS & FURTHER RECOMMENDATIONS

Bile acid profile warranted regarding the hepatic presentation. Ursodiol therapy warranted given the gallbladder presentation. FNA of the general liver and nodular change recommended, or core biopsy. Full urinary workup warranted to assess for inflammatory sediment if not already performed.





The information and recommendations provided are based on the images presented by the referring veterinarian/sonographer. No evaluation can be communicated regarding pathology that was not visible in the image/video clips provided.

Thank you for this referral. If the clinical or image interpretation does not parallel your findings or if I can be of any further assistance please contact me.

Eric Lindquist, DMV, DABVP, Cert. IVUSS, CEO of SonoPath.com
info@SonoPath.com