

PATIENT

Esteban Haseotes

PRESENTING CLINICAL SIGNS

Chronic history of vomiting and weight loss. Patient eats a hydrolyzed diet. Mildly elevated ALT, AST. Screening for GI disease (IBD).

SPECIES

Feline

ULTRASONOGRAPHIC EXAMINATION OF THE ABDOMEN

Urinary System

BREED

DSH

The **urinary bladder**, trigone, and pelvic urethra presented normal thicknesses and normal tone. The ureters were not visible which is normal. No uroliths or sediment were visualized and anechoic urine was present. No evidence of inflammatory or neoplastic changes were noted. Ureteral papillae were normal. The pelvic urethra was imaged 2.0 cm beyond the cystourethral junction.

SEX

Neutered Male

The **kidneys** revealed largely normal size and structure, corticomedullary definition and ratio (cortex 1/3 of medulla) were essentially maintained with some age-related loss of curvilinear patterns regarding the capsule and C/M junction. The cortices presented largely uniform texture with some increased echogenicity expected for his age patient. Medullary structure differed distinctly from that of the cortex and no evidence of pelvic dilation was present. The left kidney measured 3.67 cm. The right kidney measured 3.67 cm.

AGE

12 Years 9 Months

Adrenal Glands

WEIGHT

10.53 Pounds

Both **adrenal glands** were visualized and recognized as having normal shape, size, position and echogenicity for this breed. The phrenic vasculature, glandular echogenicity and detail were unremarkable. Capsule, cortex, and medullary definition were normal for this age patient. The left adrenal gland measured 0.50 cm.

INTERPRETED BY

Eric Lindquist, DMV

DABVP, Cert. IVUSS

Spleen

The **spleen** presented a smooth homogeneous parenchyma hyperechoic to liver and renal cortical parenchyma. The capsule was smooth without noticeable expansion or deviation from within the spleen or adjacent pathology. The splenic vasculature demonstrated normal volume without signs of congestion or thrombosis. No sonographic evidence of acute or chronic inflammatory, neoplastic, or infarctual changes were noted.

IMAGING PERFORMED BY

M Kermendy CVT

Liver

The **liver** images from right and left intercostal as well as subcostal views revealed subjectively normal liver size, contour, and structure. Some age-related parenchymal remodeling was noted but likely not clinically significant at this time. Vascular and biliary tracts were of normal volume and no evidence of congestion was noted. The gallbladder presented some dependent debris with essentially normal contour. The cystic and common bile ducts were normal. No overt evidence of active inflammatory, infiltrative or regenerative pathology was noted but should be paired with current or past LE elevations regarding any clinical significance to this presentation. The hepatic lymph nodes were unremarkable.

HOSPITAL NAME

Wauwatosa VC

REFERRING VET

Dr. Ericka Haynes

Gastrointestinal

INVOICE

41012

Examination of the **gastrointestinal tract** revealed a stomach and intestine free of stasis, of normal wall thickness, acceptable curvilinear mural detail, and peristaltic activity. Small and large intestine demonstrated normal luminal chyme and stool consistency respectively. No obstructive or overt infiltrative disease was noted. No associated abnormal lymphatic activity was noted.

DATE

9/2/22



PATIENT

Pancreas

Esteban Haseotes

The base and limbs of the **pancreas** were observed to be largely isoechoic to surrounding omental fat. Some parenchymal remodeling, however, with mild deviation from curvilinear normalcy was observed. Pancreatic duct and capsular irregularities were present consistent with age related changes. If pain upon imaging (+ Murphy sign) was present or if the patient is focally painful in subxyphoid palpation then low-grade smoldering chronic pancreatitis should be suspected.

SPECIES

Feline

BREED

DSH

- Structurally unremarkable abdomen with geriatric changes
- Likely reactive hepatopathy, structurally unremarkable

ULTRASONOGRAPHIC FINDINGS

INTERPRETATION OF THE FINDINGS & FURTHER RECOMMENDATIONS

SEX

Neutered Male

Maldigestion panel, three view chest radiographs and full CNS examination is recommended to examine for occult disease that could be responsible for the weight loss. Evaluation for competitive eating environments should also be considered.

AGE

Chest & Abdominal Radiographs (VD & Lateral): Unremarkable, no overt pathology.

12 Years 9 Months

WEIGHT

10.53 Pounds

INTERPRETED BY

Eric Lindquist, DMV
DABVP, Cert. IVUSS

IMAGING PERFORMED BY

M Kermendy CVT

HOSPITAL NAME

Wauwatosa VC

REFERRING VET

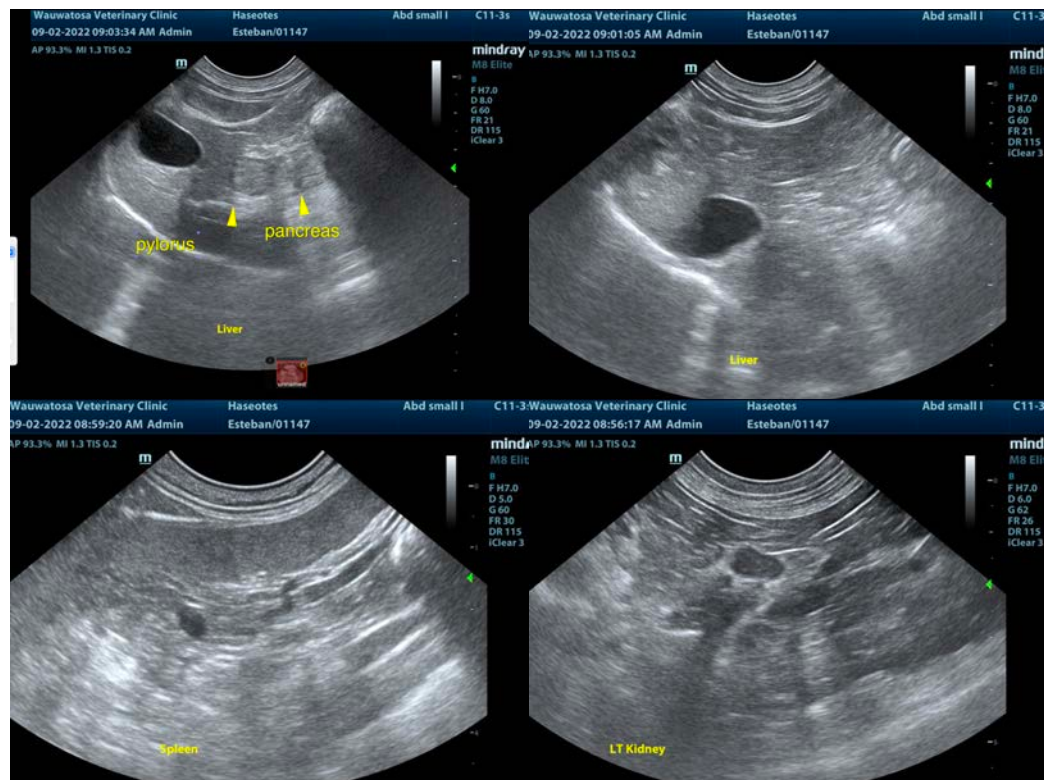
Dr. Ericka Haynes

INVOICE

41012

DATE

9/2/22





PATIENT

Esteban Haseotes

SPECIES

Feline

BREED

DSH

SEX

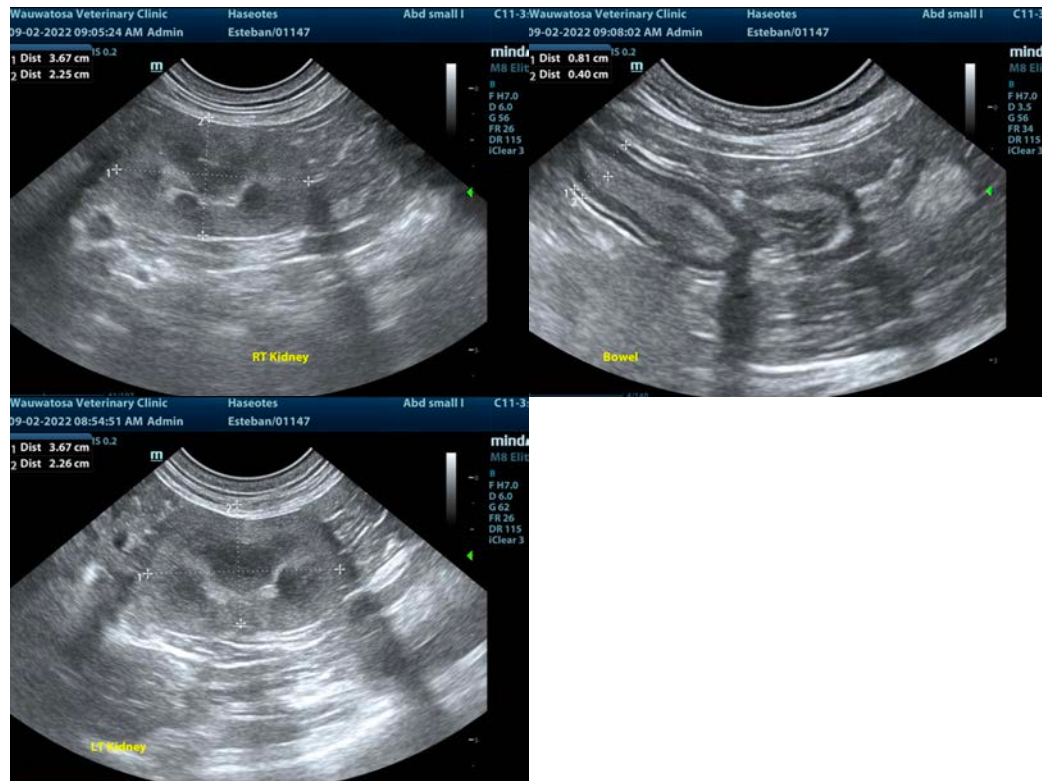
Neutered Male

AGE

12 Years 9 Months

WEIGHT

10.53 Pounds



The information and recommendations provided are based on the images presented by the referring veterinarian/sonographer. No evaluation can be communicated regarding pathology that was not visible in the image/video clips provided.

Thank you for this referral. If the clinical or image interpretation does not parallel your findings or if I can be of any further assistance please contact me.

Eric Lindquist, DMV, DABVP, Cert. IVUSS, CEO of SonoPath.com

info@SonoPath.com

INTERPRETED BY

Eric Lindquist, DMV
DABVP, Cert. IVUSS

IMAGING PERFORMED BY

M Kermendy CVT

HOSPITAL NAME

Wauwatosa VC

REFERRING VET

Dr. Ericka Haynes

INVOICE

41012

DATE

9/2/22