



PATIENT

Oliver Kolackovsky
Powell

SPECIES

Canine

BREED

Chow

SEX

Neutered male

AGE

11 years

WEIGHT

32 kg

INTERPRETED BY

Eric Lindquist, DMV
DABVP, Cert. IVUSS

IMAGING PERFORMED BY

Dave Stasiuk RDMS,
RDMS

HOSPITAL NAME

Montgomery Village
VC

REFERRING VET

Chris Belan VS

INVOICE

91640

DATE

9/2/21

PRESENTING CLINICAL SIGNS

History: Enlarged spleen noted on AXR and on exam.

Urinary System

The **urinary bladder**, trigone, and pelvic urethra presented normal thicknesses and normal tone. The ureters were not visible which is normal. No uroliths or sediment were visualized and anechoic urine was present. No evidence of inflammatory or neoplastic changes was noted. Ureteral papillae were normal.

The **right kidneys** revealed normal size and structure, corticomedullary definition and ratio for this age. The cortices presented largely uniform texture with normal echogenic relationship to liver and spleen. Medullary structure differed distinctly from the cortex and no evidence of pelvic dilation was present. The capsules were acceptably uniform without significant irregularities. The right kidney measured 7.05 cm. The **left kidney** revealed moderate hydronephrosis and hydroureter. The left kidney was significantly subnormal in size at 4.2 cm with hydroureter of 1.7 cm.

Adrenal Glands

Both **adrenal glands** were visualized and recognized as having normal shape, size, position and echogenicity for this breed. The phrenic vasculature, glandular echogenicity and detail were unremarkable. Capsule, cortex, and medullary definition were normal for this age patient.

Spleen

The **spleen** in this patient was mildly enlarged with uniform parenchyma and was folded upon itself likely creating the appearance of splenomegaly. This is a positional variant and is not pathological. There was no evidence of significant disease.

Liver

The **liver** images from right and left intercostal as well as subcostal views revealed subjectively normal liver size, contour, and structure. Some age-related parenchymal remodeling was noted but likely not clinically significant at this time. Vascular and biliary tracts were of normal volume and no evidence of congestion was noted. The gallbladder presented some dependent debris with essentially normal contour. The cystic and common bile ducts were normal. No overt evidence of active inflammatory, infiltrative or regenerative pathology was noted but should be paired with current or past LE elevations regarding any clinical significance to this presentation. The hepatic lymph nodes were unremarkable.

Gastrointestinal

Examination of the **gastrointestinal tract** revealed a stomach and intestine free of stasis, of normal wall thickness, acceptable curvilinear mural detail, and peristaltic activity. Small and large intestine



PATIENT

Oliver Kolackovsky
Powell

demonstrated normal luminal chyme and stool consistency respectively. No obstructive or overt infiltrative disease was noted. No associated abnormal lymphatic activity was noted.

SPECIES

Canine

Pancreas

The base and limbs of the **pancreas** were observed to be largely isoechoic to surrounding omental fat. Pancreatic duct and capsular contour were acceptably normal and parenchyma respected normal curvilinear patterns. No overt evidence of active inflammatory or neoplastic disease was noted.

BREED

Chow

ULTRASONOGRAPHIC FINDINGS

SEX

Neutered male

Left hydroureter. Likely owing to stricture, possible congenital lesion.

Chronic obstructive nephrolithiasis.

Folded spleen, positional variant.

AGE

11 years

INTERPRETATION OF THE FINDINGS & FURTHER RECOMMENDATIONS

The exact cause of the hydroureter is unclear. It was followed to the level of the urinary bladder and likely strictured.

WEIGHT

32 kg

INTERPRETED BY

Eric Lindquist, DMV
DABVP, Cert. IVUSS

IMAGING PERFORMED BY

Dave Stasiuk RDMS,
RDCS

HOSPITAL NAME

Montgomery Village
VC

REFERRING VET

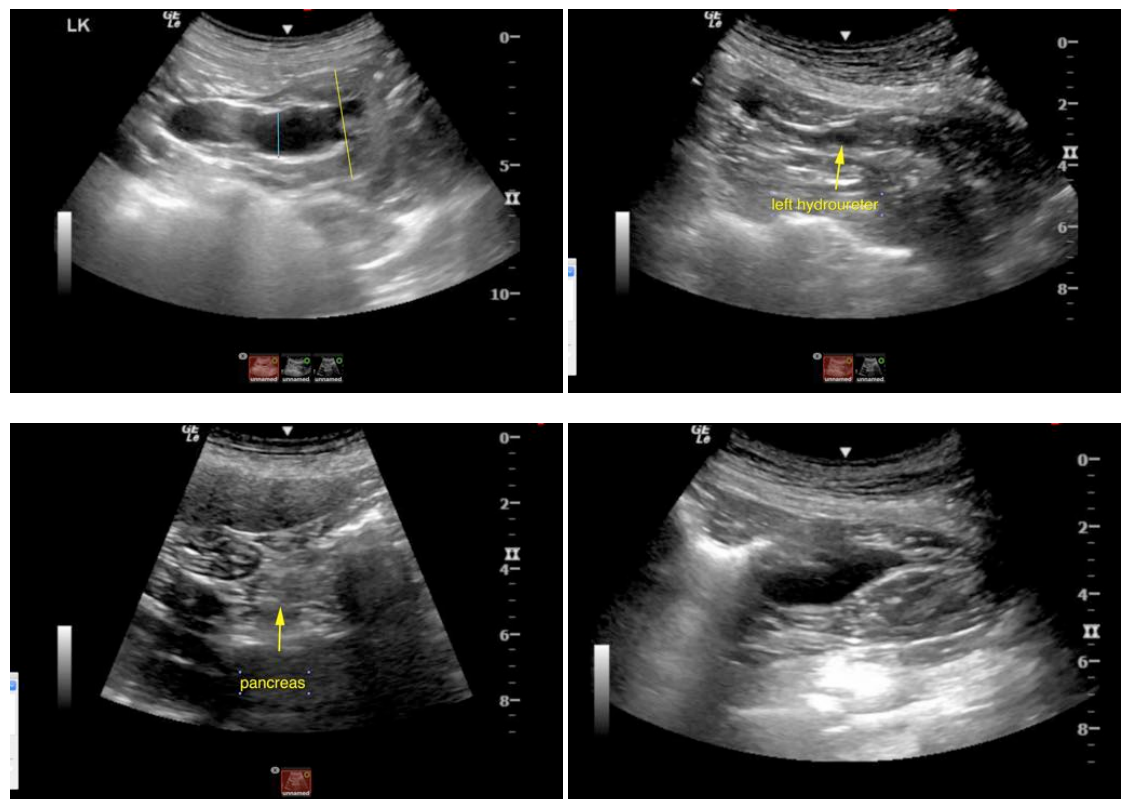
Chris Belan VS

INVOICE

91640

DATE

9/2/21





PATIENT

Oliver Kolackovsky
Powell

SPECIES

Canine

BREED

Chow

SEX

Neutered male

AGE

11 years

WEIGHT

32 kg

INTERPRETED BY

Eric Lindquist, DMV
DABVP, Cert. IVUSS

IMAGING PERFORMED BY

Dave Stasiuk RDMS,
RDCS

HOSPITAL NAME

Montgomery Village
VC

REFERRING VET

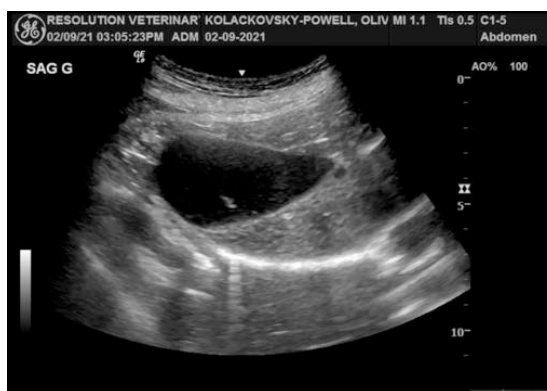
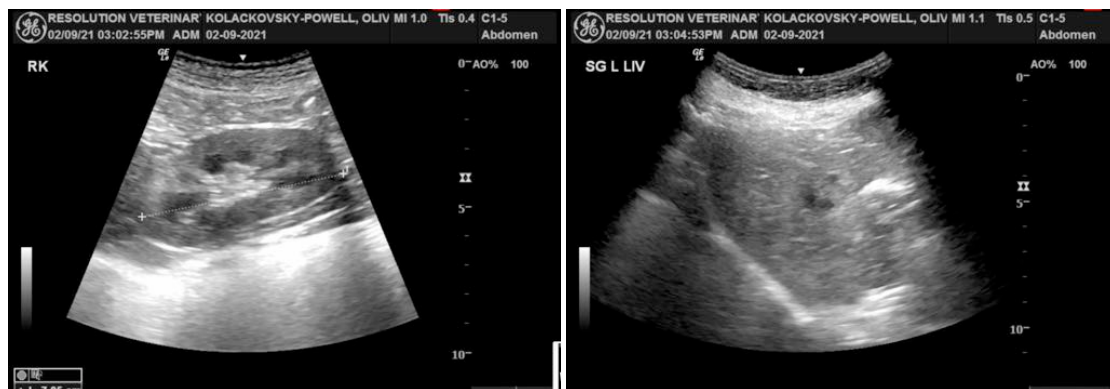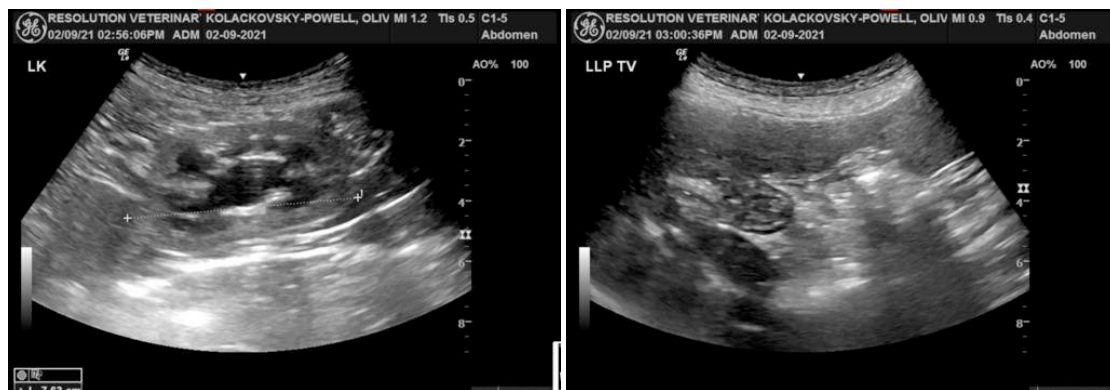
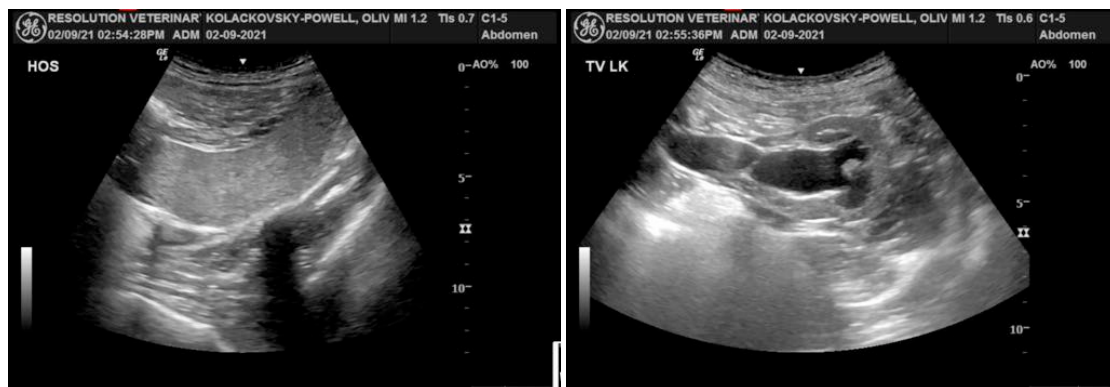
Chris Belan VS

INVOICE

91640

DATE

9/2/21



The information and recommendations provided are based on the images presented by the referring



PATIENT

Oliver Kolackovsky
Powell

veterinarian. No evaluation can be communicated regarding pathology that was not visible in the image/video clips provided.

Thank you for this referral. If the clinical or image interpretation does not parallel your findings or if I can be of any further assistance please contact me.

SPECIES

Canine

Eric Lindquist, DMV, DABVP, Cert. IVUSS, CEO of SonoPath.com
info@SonoPath.com

BREED

Chow

SEX

Neutered male

AGE

11 years

WEIGHT

32 kg

INTERPRETED BY

Eric Lindquist, DMV
DABVP, Cert. IVUSS

**IMAGING
PERFORMED BY**

Dave Stasiuk RDMS,
RDCS

HOSPITAL NAME

Montgomery Village
VC

REFERRING VET

Chris Belan VS

INVOICE

91640

DATE

9/2/21