



PATIENT

Foxy Brown

SPECIES

Feline

BREED

Domestic Longhair

SEX

Spayed Female

AGE

12 years

WEIGHT

7 lbs

INTERPRETED BY

Eric Lindquist, DMV
DABVP, Cert. IVUSS

IMAGING PERFORMED BY

Jessica Biles

HOSPITAL NAME

All Creatures Great
and Small

REFERRING VET

Dr. Biles

INVOICE

91639

DATE

9/2/21

PRESENTING CLINICAL SIGNS

History: Hx of cerebellar hypoplasia as a kitten evaluated for lethargy, decreased appetite, bradycardia and hypothermia 1 year ago; hx of elevated WBC on bloodwork - echo performed for further evaluation - segmental ventricular hyperplasia noted, otherwise NSF on echo; recheck echo recommended in 1 year; since then concerning symptoms have for the most part resolved w/ regular administration of mirataz.
Abnormal PE/Chem/CBC/UA Results: Neuro symptoms consistent w/ cerebellar hypoplasia 4/6 heart murmur heard today Weight stable, otherwise NSF on exam Bloodwork pending.

ULTRASONOGRAPHIC EXAMINATION OF THE HEART

The cardiac presentation revealed relatively normal septal and free wall thicknesses and contractility. Normal internal volume were noted. Trivial mitral and tricuspid insufficiency was noted. no pericardial or pleural effusion was present.

FELINE CARDIAC PARAMETERS	BODY WEIGHT (kg)	HR (BPM)	IVSd (cm)	LVIDd (cm)	LVWd (cm)	FS (%)	EF (%)
NORMAL PARAMETER	-----	150-240	0.3-0.6	1.0-2.1	0.25-0.6	35-67	80-100
PATIENT		NM	0.54	1.07	0.48	69	96
FELINE CARDIAC PARAMETERS	LA/AO (Boon)	LA/AO HEART BASE (Sisson)	LA 2D 4-chamber long axis AS to FW (Sisson) (cm)	LVOT VEL. (m/s)	RVOT VEL. (m/s)	IVRT (m/)	
NORMAL PARAMETER	<1.5	0.88-1.79	0.7-1.7	<1.6	<1.3	40-60	
PATIENT	1.0	1.1		1.3	0.96	NM	

Adapted from June Boon, Veterinary Echocardiography, 1998
Sisson D et al. JVIM 1991; 5: 232, Jacobs et al. Am J Vet Res 1985; 46:1705

ULTRASONOGRAPHIC FINDINGS

Essentially flow murmur.

No evidence of pathology.

INTERPRETATION OF THE FINDINGS & FURTHER RECOMMENDATIONS

No therapy is recommended.



PATIENT

Foxy Brown

SPECIES

Feline

BREED

Domestic Longhair

SEX

Spayed Female

AGE

12 years

WEIGHT

7 lbs

INTERPRETED BY

Eric Lindquist, DMV
DABVP, Cert. IVUSS

IMAGING PERFORMED BY

Jessica Biles

HOSPITAL NAME

All Creatures Great and Small

REFERRING VET

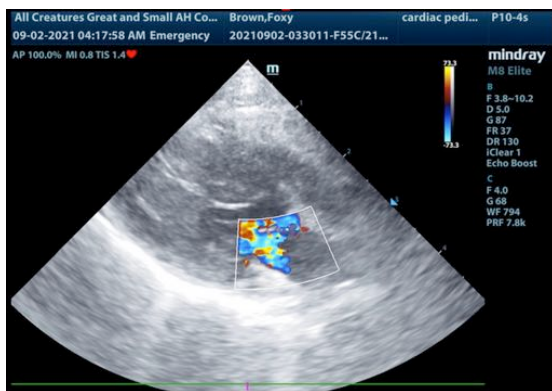
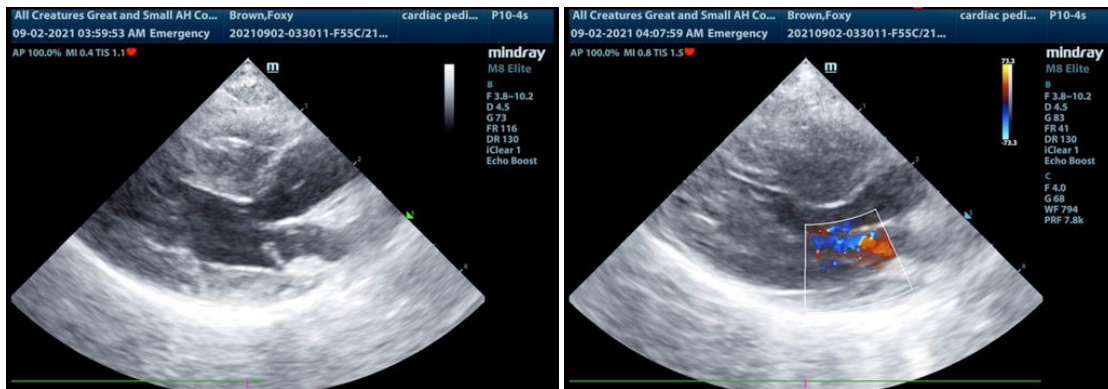
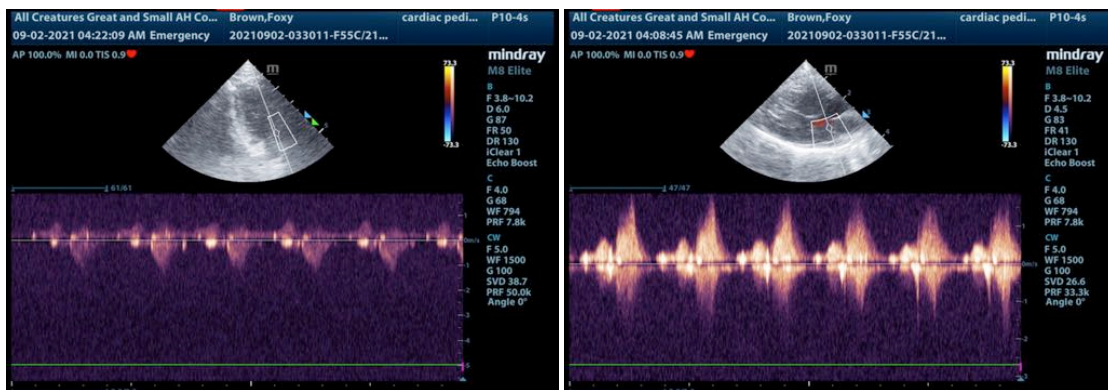
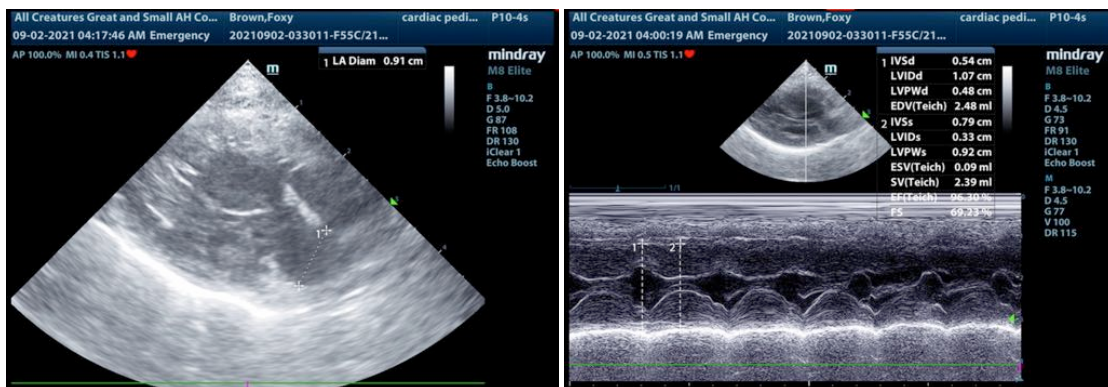
Dr. Biles

INVOICE

91639

DATE

9/2/21





PATIENT

Foxy Brown

veterinarian. No evaluation can be communicated regarding pathology that was not visible in the image/video clips provided.

Thank you for this referral. If the clinical or image interpretation does not parallel your findings or if I can be of any further assistance please contact me.

SPECIES

Feline

Eric Lindquist, DMV, DABVP, Cert. IVUSS, CEO of SonoPath.com
info@SonoPath.com

BREED

Domestic Longhair

SEX

Spayed Female

AGE

12 years

WEIGHT

7 lbs

INTERPRETED BY

Eric Lindquist, DMV
DABVP, Cert. IVUSS

**IMAGING
PERFORMED BY**

Jessica Biles

HOSPITAL NAME

All Creatures Great
and Small

REFERRING VET

Dr. Biles

INVOICE

91639

DATE

9/2/21