



PATIENT

Sophie Basch

SPECIES

Canine

BREED

Yorkie Poo

SEX

Spayed Female

AGE

3 Years

WEIGHT

10.2 Pounds

INTERPRETED BY

Eric Lindquist, DMV
DABVP, Cert. IVUSS

**IMAGING
PERFORMED BY**

Adrienne Waffle

HOSPITAL NAME

Torch Lake VC

REFERRING VET

Adrienne Waffle

INVOICE

17362

DATE

9/19/22

PRESENTING CLINICAL SIGNS

History: Hx of recurrent vomiting and bloody diarrhea Improved with metro, famotidine, sucralfate. Considering ACTH Stim.

Abnormal PE/Chem/CBC/UA Results: PE unremarkable, previous bloods unremarkable.

ULTRASONOGRAPHIC EXAMINATION OF THE ABDOMEN

Urinary System

The **urinary bladder**, trigone, and pelvic urethra presented normal thicknesses and normal tone. The ureters were not visible which is normal. No uroliths or sediment were visualized, and anechoic urine was present. No evidence of inflammatory or neoplastic changes were noted. Ureteral papillae were normal.

The **kidneys** revealed normal size and structure, corticomedullary definition and ratio for this age. The cortices presented largely uniform texture with normal echogenic relationship to liver and spleen. Medullary structure differed distinctly from the cortex and no evidence of pelvic dilation was present. The capsules were acceptably uniform without significant irregularities. Both kidneys measured 3.0 cm each.

Adrenal Glands

Both **adrenal glands** appeared subjectively isoechoic and small. The left adrenal gland measured 0.4 cm. The right adrenal gland measured 0.4 cm.

Spleen

The **spleen** presented a smooth homogeneous parenchyma hyperechoic to liver and renal cortical parenchyma. The capsule was smooth without noticeable expansion or deviation from within the spleen or adjacent pathology. The splenic vasculature demonstrated normal volume without signs of congestion or thrombosis. No sonographic evidence of acute or chronic inflammatory, neoplastic, or infarctual changes were noted.

Liver

The **liver** was slightly subnormal in size yet uniform parenchyma. The gallbladder and common bile duct were unremarkable.

Gastrointestinal

Examination of the **gastrointestinal tract** revealed a stomach and intestine free of stasis, of normal wall thickness, acceptable curvilinear mural detail, and peristaltic activity. Small and large intestine demonstrated normal luminal chyme and stool consistency respectively. No obstructive or overt infiltrative disease was noted. No associated abnormal lymphatic activity was noted.

Pancreas

The base and limbs of the **pancreas** were observed to be largely isoechoic to surrounding omental fat. Pancreatic duct and capsular contour were acceptably normal and parenchyma respected normal curvilinear patterns. No overt evidence of active inflammatory or neoplastic disease was noted.

ULTRASONOGRAPHIC FINDINGS



PATIENT

Sophie Basch

- Subjectively isoechoic and small adrenal glands
- Subnormal liver size

SPECIES

Canine

INTERPRETATION OF THE FINDINGS & FURTHER RECOMMENDATIONS

Screening for Addisons warranted. General supportive care for GI upset should prove effective, unless underlying Addisons disease is an issue.

BREED

Yorkie Poo

SEX

Spayed Female

AGE

3 Years

WEIGHT

10.2 Pounds

INTERPRETED BY

Eric Lindquist, DMV
DABVP, Cert. IVUSS

IMAGING PERFORMED BY

Adrienne Waffle

HOSPITAL NAME

Torch Lake VC

REFERRING VET

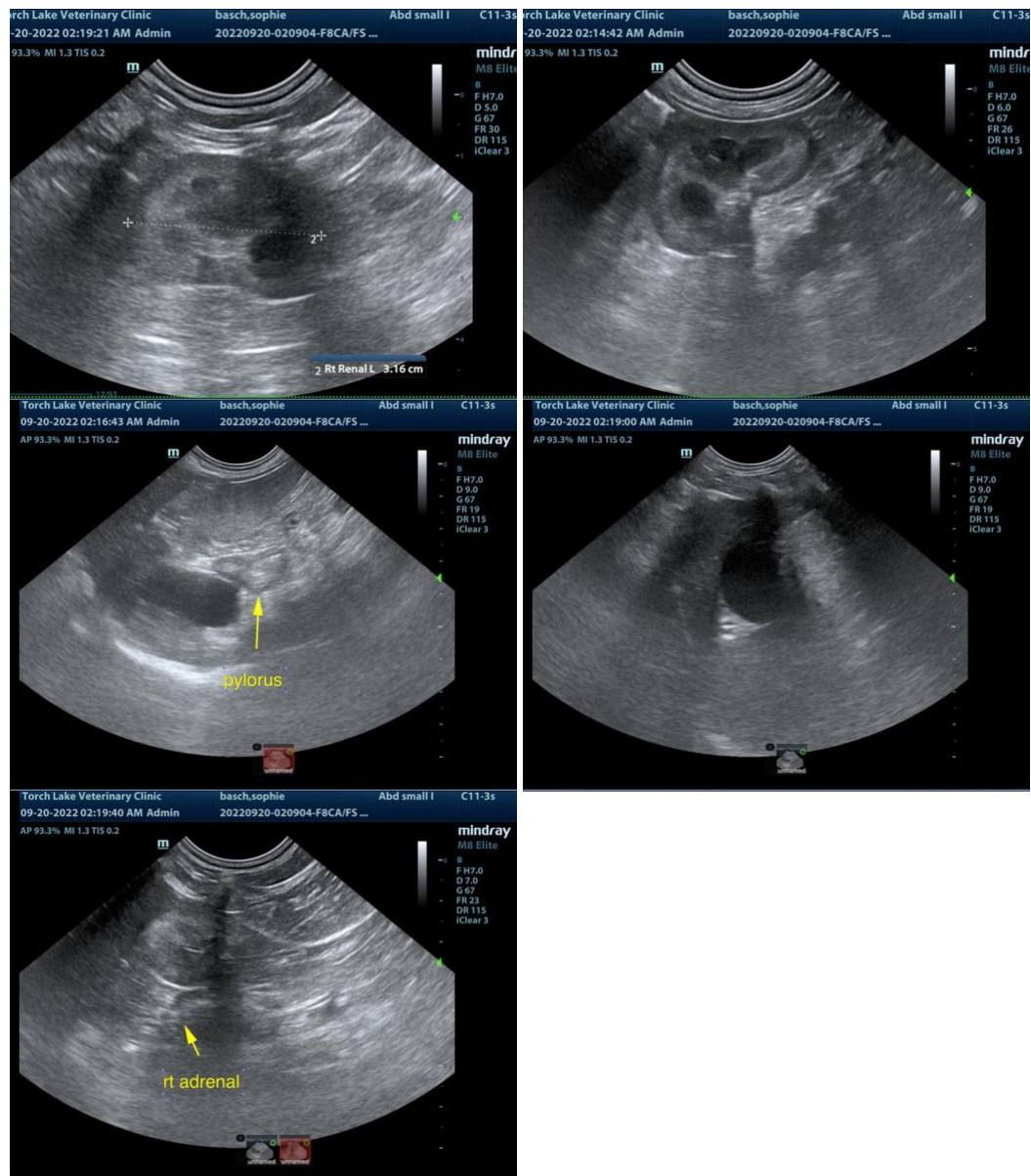
Adrienne Waffle

INVOICE

17362

DATE

9/19/22



The information and recommendations provided are based on the images presented by the referring veterinarian. No evaluation can be communicated regarding pathology that was not visible in the image/video clips provided.

Thank you for this referral. If the clinical or image interpretation does not parallel your findings or if I



PATIENT

can be of any further assistance please contact me.

Sophie Basch

SPECIES

Eric Lindquist, DMV, DABVP, Cert. IVUSS, CEO of SonoPath.com
info@SonoPath.com

Canine

BREED

Yorkie Poo

SEX

Spayed Female

AGE

3 Years

WEIGHT

10.2 Pounds

INTERPRETED BY

Eric Lindquist, DMV
DABVP, Cert. IVUSS

**IMAGING
PERFORMED BY**

Adrienne Waffle

HOSPITAL NAME

Torch Lake VC

REFERRING VET

Adrienne Waffle

INVOICE

17362

DATE

9/19/22