**DATE**

9/19/22

**PATIENT**

Madonna Pierre

**SPECIES**

Feline

**BREED**

Domestic Shorthair

**SEX**

Spayed female

**AGE**

3/1/12

**WEIGHT**

5.7 lbs

**INTERPRETED BY**Eric Lindquist, DMV  
DABVP, Cert. IVUSS**HOSPITAL NAME**Aniimal Emergency  
Hospital**REFERRING VET**

Dr. Roper

**INVOICE**

39472

**PRESENTING CLINICAL SIGNS**

For about a month P has not been eating, losing weight, vomiting, and not defecating. P is still urinating. P has had a change in the way she walks. P does usually not get into things. P went to rDVM and bloodwork showed: - hypercalcemia - BUN: 55 - Glob: 5.2 - Crea: 2.2 - Na: 170 rDVM xrays showed possible mass

Current Medications: None listed.

Date of Previous IntraPet Ultrasound: No previous.

Sedation: Not required to complete full diagnostic ultrasound.

Stat Report: Not requested.

Imaging Performed By: Rachel Brilhart, RDMS.

**ULTRASONOGRAPHIC EXAMINATION OF THE ABDOMEN****Urinary System**

The **urinary bladder**, trigone, and pelvic urethra presented normal thicknesses and normal tone. The ureters were not visible which is normal. No uroliths or sediment were visualized and anechoic urine was present. No evidence of inflammatory or neoplastic changes was noted. Ureteral papillae were normal.

The **kidneys** revealed largely normal size and structure, corticomedullary definition and ratio (cortex 1/3 of medulla) were essentially maintained with some age-related loss of curvilinear patterns regarding the capsule and C/M junction. The cortices presented largely uniform texture with some increased echogenicity expected for his age patient. Medullary structure differed distinctly from that of the cortex and no evidence of pelvic dilation was present. Slight pinpoint mineralization was noted. The right kidney measured 3.0 cm. The left kidney measured 2.81 cm with cortical infarcts at the caudal pole. Blood flow to the kidneys appeared subnormal.

**Adrenal Glands**

Both **adrenal glands** were visualized and recognized as having normal shape, size, position and echogenicity for this breed. The phrenic vasculature, glandular echogenicity and detail were unremarkable. Capsule, cortex, and medullary definition were normal for this age patient.

**Spleen**

The **spleen** in this patient was uniform, yet volume contracted. Hydration status should be assessed.

**Liver**

The **liver** was diffusely hyperechoic to the falciform fat. The gallbladder was mildly over distended. This may be owing to anorexia.

**Gastrointestinal**

Examination of the **gastrointestinal tract** revealed a stomach and intestine free of stasis, of normal wall thickness, acceptable curvilinear mural detail, and peristaltic activity. Small and large intestine demonstrated normal luminal chyme and stool consistency respectively. The colon was repleted with fairly hard stool. The ileocecal junction was unremarkable.

**Pancreas**

The base and limbs of the **pancreas** were observed to be largely isoechoic to surrounding omental fat. Some parenchymal remodeling, however, with mild deviation from curvilinear normalcy was observed. Pancreatic duct and capsular irregularities were present consistent with age related changes. If pain upon imaging (+

Murphy sign) was present or if the patient is focally painful in subxiphoid palpation then low-grade smoldering chronic pancreatitis should be suspected.

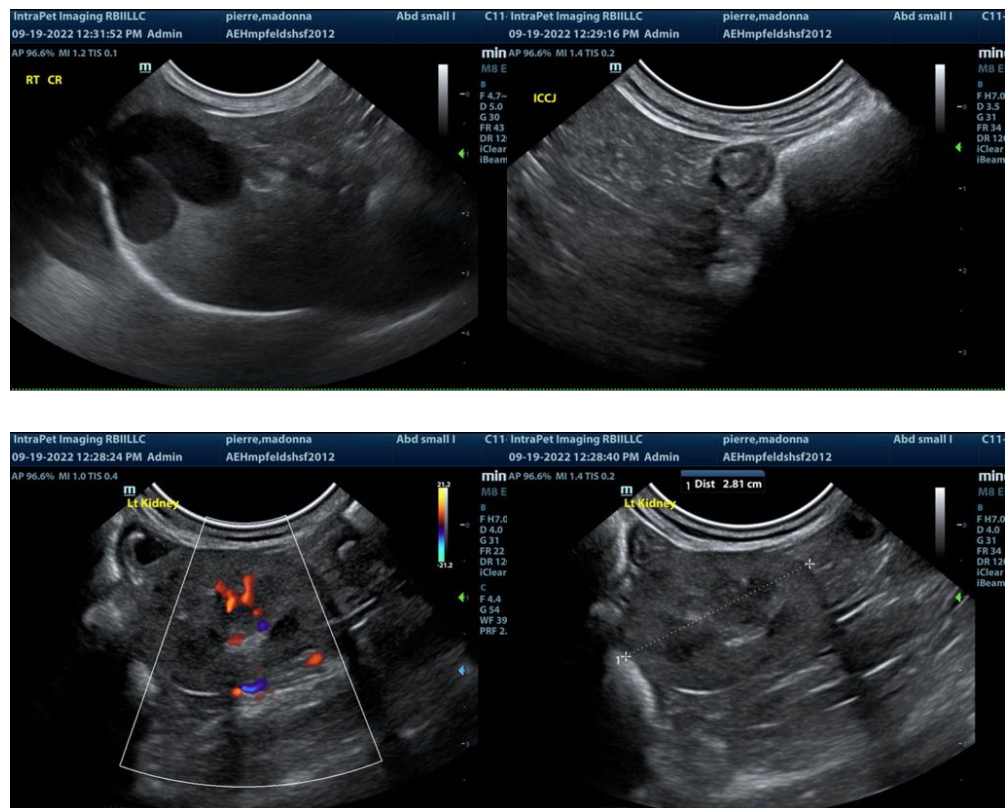
### ULTRASONOGRAPHIC FINDINGS

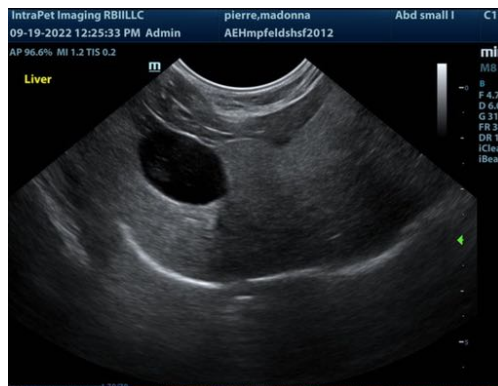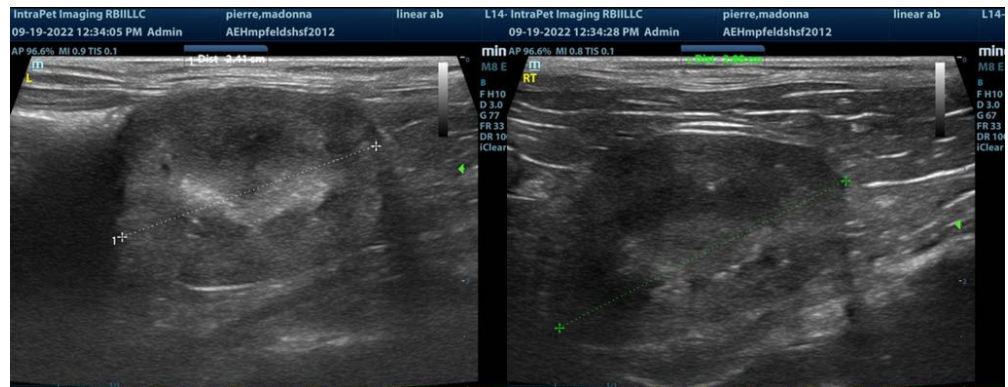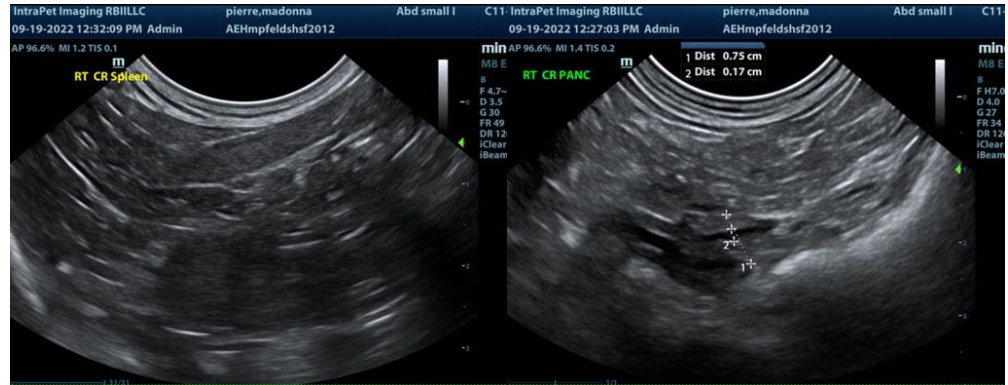
Mild hepatic lipidosis pattern.

Moderate degenerative renal changes, do not subjectively appear end stage.

### INTERPRETATION OF THE FINDINGS & FURTHER RECOMMENDATIONS

Pre renal disease and complicated factors such as hypertension, UTI, infectious or toxic agents should all be considered. There is no evidence of neoplasia. 72 hour VI fluid protocol and supportive renal protocol would be warranted. I recommend reassessment of the clinical profile.





The information and recommendations provided are based on the images presented by the referring veterinarian. No evaluation can be communicated regarding pathology that was not visible in the image/video clips provided.

Thank you for this referral. If the clinical or image interpretation does not parallel your findings or if I can be of any further assistance please contact me.

**Eric Lindquist, DMV, DABVP, Cert. IVUSS, CEO of SonoPath.com**  
 Eric.Lindquist@SonoPath.com