



PATIENT

Gizmo Stringham

PRESENTING CLINICAL SIGNS

History: gallop heart rhythm and abnormal pro BN{ no obvious HM

SPECIES

Feline

BREED

DSH

SEX

Male

AGE

9 Years

WEIGHT

9.8 Pounds

ULTRASONOGRAPHIC EXAMINATION OF THE HEART

FELINE CARDIAC PARAMETERS	BODY WEIGHT (kg)	HR (BPM)	IVSd (cm)	LVIDd (cm)	LVWd (cm)	FS (%)	EF (%)
NORMAL PARAMETER	-----	150-240	0.3-0.6	1.0-2.1	0.25-0.6	35-67	80-100
PATIENT	--	230	0.58	1.6	0.54	30	--
FELINE CARDIAC PARAMETERS	LA/AO (Boon)	LA/AO HEART BASE (Sisson)	LA 2D 4-chamber long axis AS to FW (Sisson) (cm)	LVOT VEL. (m/s)	RVOT VEL. (m/s)	IVRT (m/)	
NORMAL PARAMETER	<1.5	0.88-1.79	0.7-1.7	<1.6	<1.3	40-60	
PATIENT	>2.0	>2.0	2.31	--	1.10	NM	

Adapted from June Boon, Veterinary Echocardiography, 1998
Sisson D et al. JVIM 1991; 5: 232, Jacobs et al. Am J Vet Res 1985; 46:1705

Cardiac Presentation

The cardiac presentation in this patient revealed moderate volume overload of the left atrium and mild volume overload of the left ventricle. Septal and free wall thicknesses were fairly normal to slightly thickened. No pericardial or pleural effusion was present. Contractility appeared adequate. Tachycardia was present

INTERPRETED BY

Eric Lindquist, DMV
DABVP, Cert. IVUSS

IMAGING PERFORMED BY

Jenn

HOSPITAL NAME

Rockaway AH

REFERRING VET

Dr. Kahn

INVOICE

17352

DATE

9/19/22

ULTRASONOGRAPHIC FINDINGS

- Unclassified to hypertrophic cardiomyopathy with left atrial enlargement, emerging left sided heart failure with compensatory tachycardia.

INTERPRETATION OF THE FINDINGS & FURTHER RECOMMENDATIONS

I recommend Ace-inhibitor at 0.5 mg/kg SID, Lasix at 6.25 mg BID and Plavix therapy. Recheck echo in 10-14 days. BUN, creatinine and blood pressures should all be evaluated, as well as sleeping respiratory rate, target <25 p/m. The right atrium, right ventricle and pulmonary outflow were all unremarkable.



PATIENT

Gizmo Stringham

SPECIES

Feline

BREED

DSH

SEX

Male

AGE

9 Years

WEIGHT

9.8 Pounds

INTERPRETED BY

Eric Lindquist, DMV
DABVP, Cert. IVUSS

IMAGING PERFORMED BY

Jenn

HOSPITAL NAME

Rockaway AH

REFERRING VET

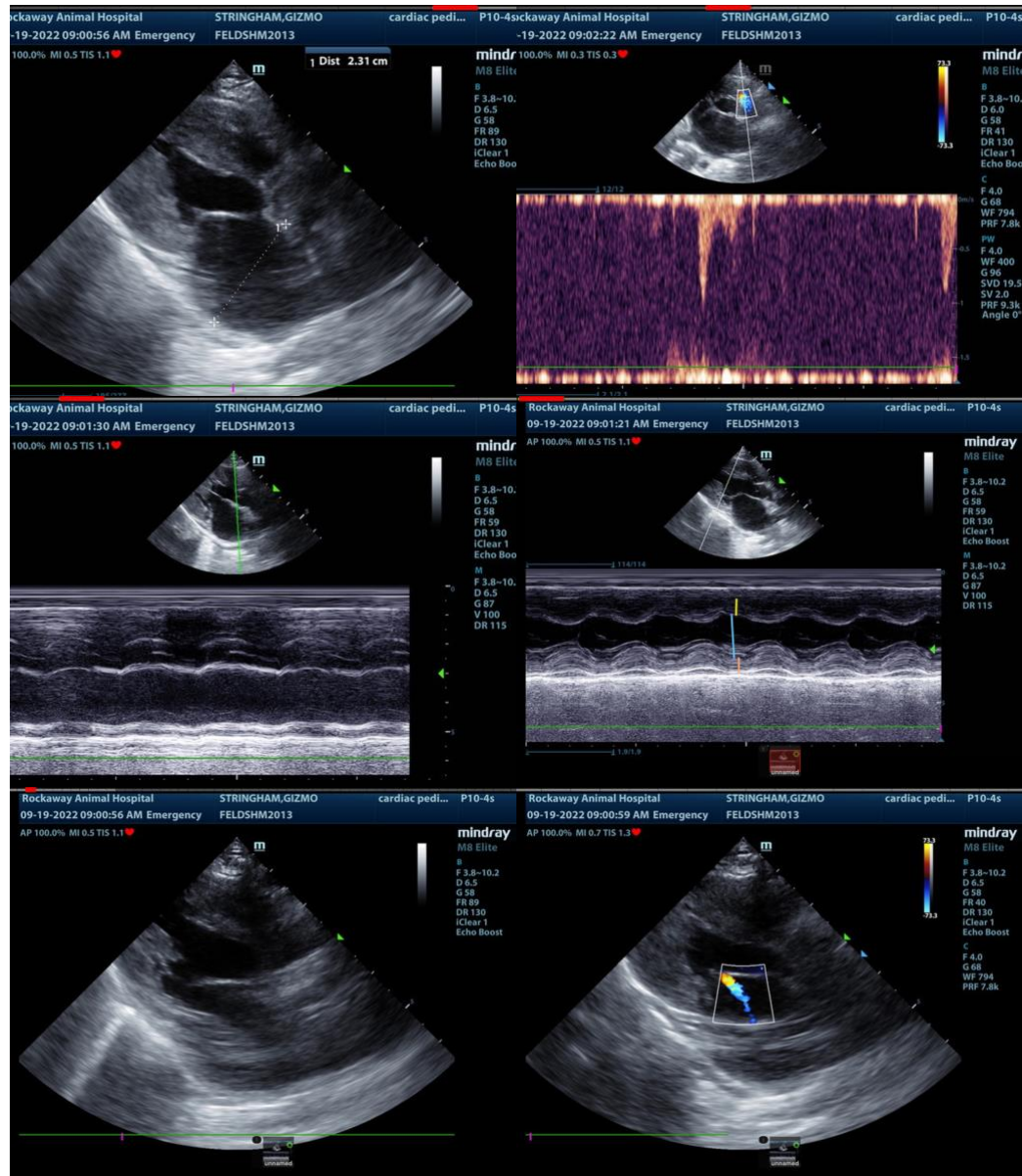
Dr. Kahn

INVOICE

17352

DATE

9/19/22



The information and recommendations provided are based on the images presented by the referring veterinarian. No evaluation can be communicated regarding pathology that was not visible in the image/video clips provided.

Thank you for this referral. If the clinical or image interpretation does not parallel your findings or if I can be of any further assistance please contact me.

Eric Lindquist, DMV, DABVP, Cert. IVUSS, CEO of SonoPath.com
info@SonoPath.com