



PATIENT

Charlie Schulman

PRESENTING CLINICAL SIGNS

History: hepatomegaly elevated liver enzymes

SPECIES

Canine

ULTRASONOGRAPHIC EXAMINATION OF THE ABDOMEN

BREED

Poodle Mix

Urinary System

The **urinary bladder**, trigone, and pelvic urethra presented normal thicknesses and normal tone. The ureters were not visible which is normal. No uroliths or sediment were visualized and anechoic urine was present. No evidence of inflammatory or neoplastic changes were noted. Ureteral papillae were normal. The pelvic urethra was imaged 2.0 cm beyond the cystourethral junction.

SEX

Neutered Male

The **kidneys** revealed normal size and structure, corticomedullary definition and ratio for this age. The cortices presented largely uniform texture with normal echogenic relationship to liver and spleen. Medullary structure differed distinctly from the cortex and no evidence of pelvic dilation was present. The capsules were acceptably uniform without significant irregularities. The right kidney measured 7.62 cm. The left kidney measured 6.63 cm.

AGE

8 Years

Adrenal Glands

Both **adrenal glands** were visualized and recognized as having normal shape, size, position and echogenicity for this breed. The phrenic vasculature, glandular echogenicity and detail were unremarkable. Capsule, cortex, and medullary definition were normal for this age patient. The left adrenal gland measured 2.65 cm x 0.74 cm at the caudal pole and 0.82 cm at the cranial pole. The right adrenal gland measured 0.6 cm at the cranial pole and 0.4 cm at the caudal pole.

WEIGHT

98.5 Pounds

Spleen

The **spleen** presented a smooth homogeneous parenchyma hyperechoic to liver and renal cortical parenchyma. The capsule was smooth without noticeable expansion or deviation from within the spleen or adjacent pathology. The splenic vasculature demonstrated normal volume without signs of congestion or thrombosis. No sonographic evidence of acute or chronic inflammatory, neoplastic, or infarctual changes were noted.

INTERPRETED BY

Eric Lindquist, DMV
DABVP, Cert. IVUSS

IMAGING PERFORMED BY

Jenn

HOSPITAL NAME

Rockaway AH

Liver

The **liver** presented heterogenous parenchyma with increased portal markings and coarse architecture. Slight undulating capsular contour was noted. The gallbladder and common bile duct were unremarkable. This is a mild change, consistent with chronic inflammatory hepatopathy.

Gastrointestinal

REFERRING VET

Dr. Maniar

Examination of the **gastrointestinal tract** revealed a stomach and intestine free of stasis, of normal wall thickness, acceptable curvilinear mural detail, and peristaltic activity. Small and large intestine demonstrated normal luminal chyme and stool consistency respectively. No obstructive or overt infiltrative disease was noted. No associated abnormal lymphatic activity was noted.

INVOICE

17351

Pancreas

The base and limbs of the **pancreas** were observed to be largely isoechoic to surrounding omental fat. Pancreatic duct and capsular contour were acceptably normal and parenchyma respected normal curvilinear patterns. No overt evidence of active inflammatory or neoplastic disease was noted.

DATE

9/19/22



PATIENT

Charlie Schulman

ULTRASONOGRAPHIC FINDINGS

- Structurally unremarkable abdomen
- Nonspecific mild hepatic remodeling

SPECIES

Canine

INTERPRETATION OF THE FINDINGS & FURTHER RECOMMENDATIONS

FNA could be considered for further definition.

BREED

Poodle Mix

SEX

Neutered Male

AGE

8 Years

WEIGHT

98.5 Pounds

INTERPRETED BY

Eric Lindquist, DMV
DABVP, Cert. IVUSS

IMAGING PERFORMED BY

Jenn

HOSPITAL NAME

Rockaway AH

REFERRING VET

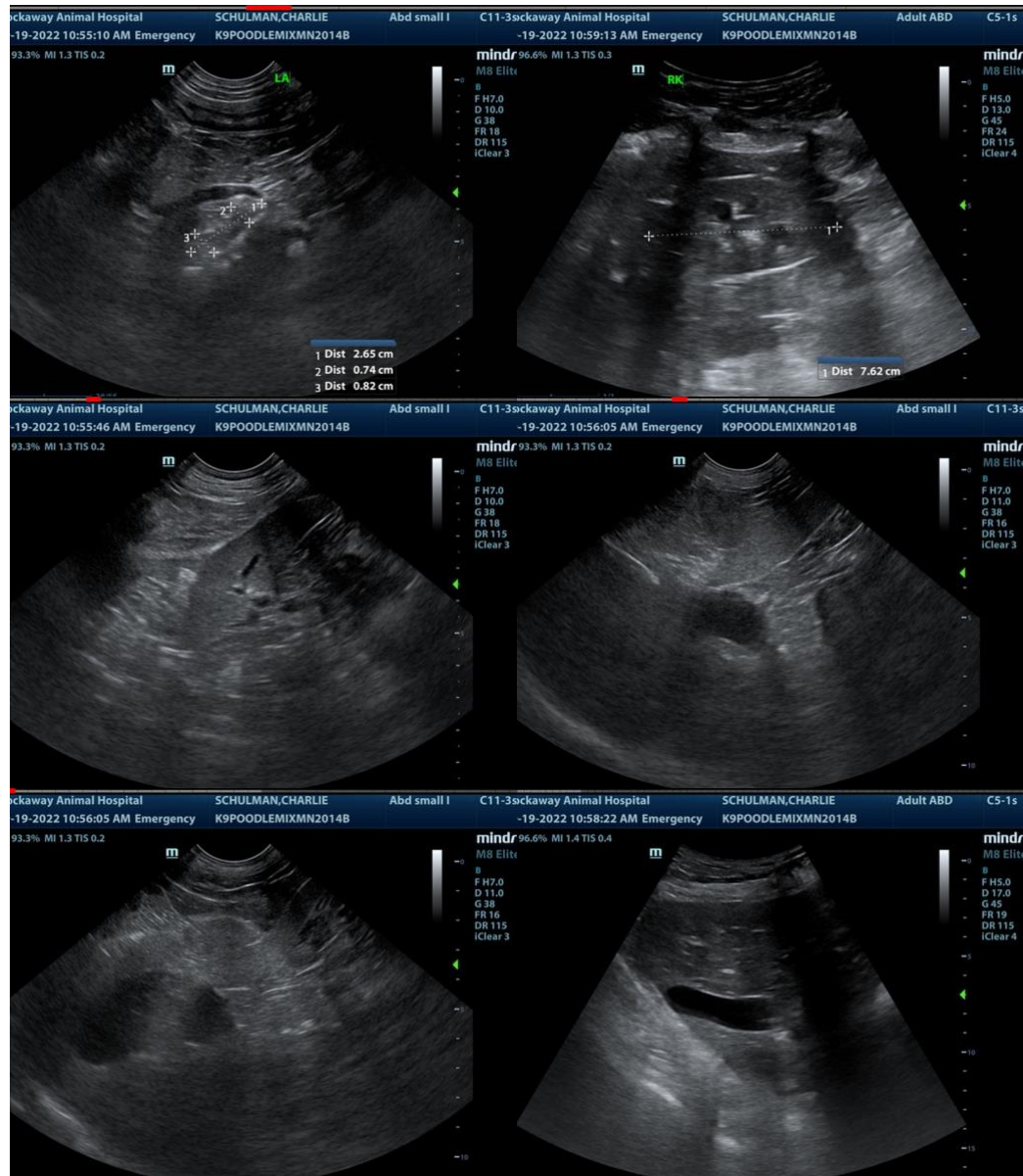
Dr. Maniar

INVOICE

17351

DATE

9/19/22



The information and recommendations provided are based on the images presented by the referring veterinarian. No evaluation can be communicated regarding pathology that was not visible in the image/video clips provided.

Thank you for this referral. If the clinical or image interpretation does not parallel your findings or if I



PATIENT

can be of any further assistance please contact me.

Charlie Schulman

SPECIES

Eric Lindquist, DMV, DABVP, Cert. IVUSS, CEO of SonoPath.com
info@SonoPath.com

Canine

BREED

Poodle Mix

SEX

Neutered Male

AGE

8 Years

WEIGHT

98.5 Pounds

INTERPRETED BY

Eric Lindquist, DMV
DABVP, Cert. IVUSS

**IMAGING
PERFORMED BY**

Jenn

HOSPITAL NAME

Rockaway AH

REFERRING VET

Dr. Maniar

INVOICE

17351

DATE

9/19/22