


PATIENT

Lily Minardi

PRESENTING CLINICAL SIGNS

Pre-sx for dental and echo also requested by ophthalmologist. Horner's syndrome. Heart murmur. Prev. report attached from 5/2020. Current meds: Vetmedin, Enalapril, Furosemide

SPECIES

Canine

Radiographs: Mild right-sided cardiac enlargement.

BREED

Coton De Tulear

ULTRASONOGRAPHIC EXAMINATION OF THE HEART
SEX

Spayed Female

AGE

10 Years

WEIGHT

Not Given

CANINE CARDIAC PARAMETERS	MR VMAX (m/s)	TR VMAX (m/s)	LA/AO (Boon method)	LA/AO (Heart Base; Swe)	FS (%)	EF (%)	EPSS (cm)
NORMAL PARAMETER	4.5-5.5	<2.7	1.3	<1.6	28-40	40-100	<0.6
PATIENT	5.68	2.51	1.6	1.62	43	76	0.16
CANINE CARDIAC PARAMETERS	HR (BPM)	AV VMAX (m/s)	PV MAX (m/s)	BODY WEIGHT (kg)	LA 2D short axis Base view (cm)	LVIDd Avg; 2D and m-mode short axis (cm)	LVIDs Avg; 2D and m-mode short axis (cm)
NORMAL PARAMETER	50-100	0.7-1.7	0.7-1.6				
PATIENT	100	1.9	0.99		3.15	2.72	

INTERPRETED BY

 Eric Lindquist, DMV
 DABVP, Cert. IVUSS

Cardiac Presentation

The echocardiogram in this patient presented slight prolapse of the anterior mitral valve leaflet. Left atrial size was relatively normal. Contractility and left ventricular internal diameters normal. Tricuspid insufficiency also present. Pericardial and pleural spaces were unremarkable. The right heart was unremarkable regarding volume.

IMAGING PERFORMED BY

Shari Reffi, CVT

ULTRASONOGRAPHIC FINDINGS

- Stable mitral and tricuspid insufficiency under current protocol

HOSPITAL NAME

Parsippany Troy Hills

INTERPRETATION OF THE FINDINGS & FURTHER RECOMMENDATIONS

No significant anesthetic risk. The cardiac presentation is unlikely to be playing a role in the Horner's syndrome. Brain CT would be ideal in this patient. Recommend continuation of the current protocol, as the heart appear to be stable. Blood pressure measurements recommended. If anesthesia is necessary, Torbutrol pre-med, Propofol induction, Isoflurane maintenance recommended as suggested protocol.

REFERRING VET

Dr. Dulude

INVOICE

25682

DATE

9/17/21



PATIENT

Lily Minardi

SPECIES

Canine

BREED

Coton De Tulear

SEX

Spayed Female

AGE

10 Years

WEIGHT

Not Given

INTERPRETED BY

Eric Lindquist, DMV
DABVP, Cert. IVUSS

IMAGING PERFORMED BY

Shari Reffi, CVT

HOSPITAL NAME

Parsippany Troy Hills

REFERRING VET

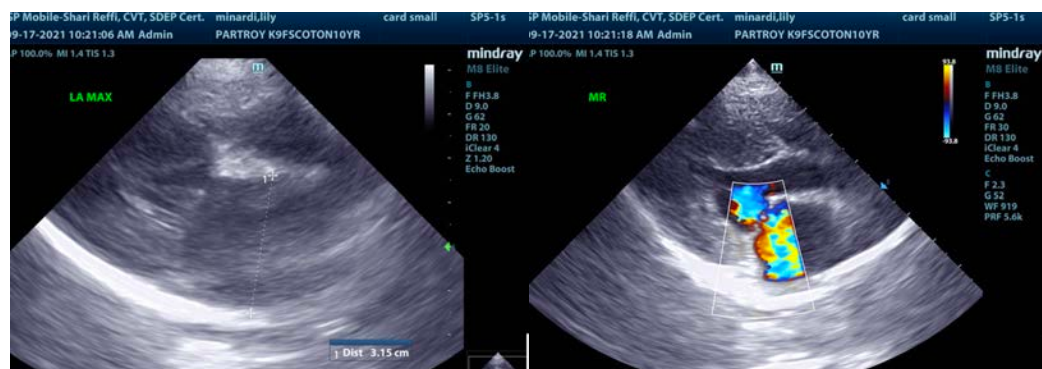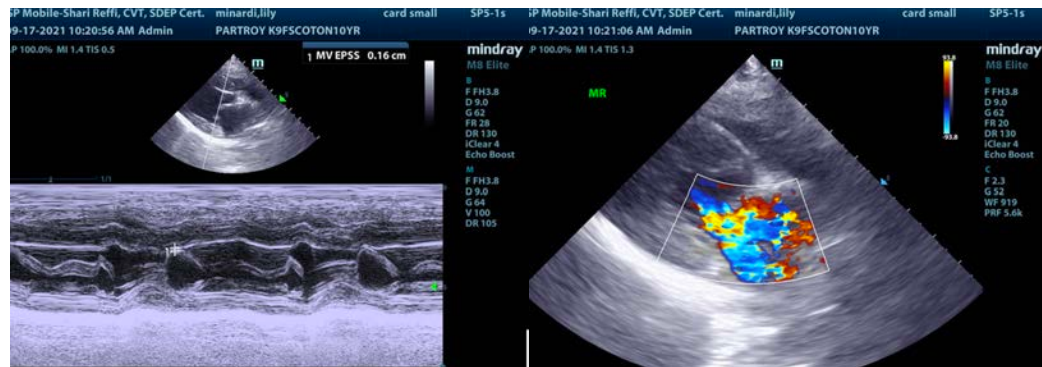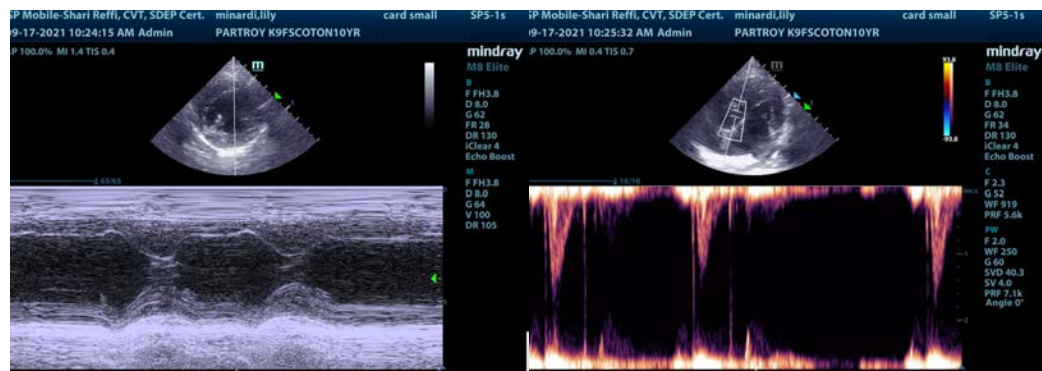
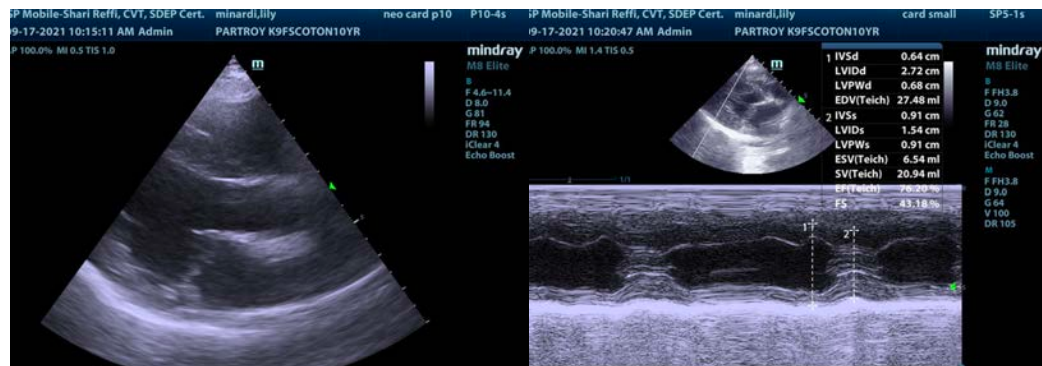
Dr. Dulude

INVOICE

25682

DATE

9/17/21





PATIENT

Lily Minardi

SPECIES

Canine

BREED

Coton De Tulear

SEX

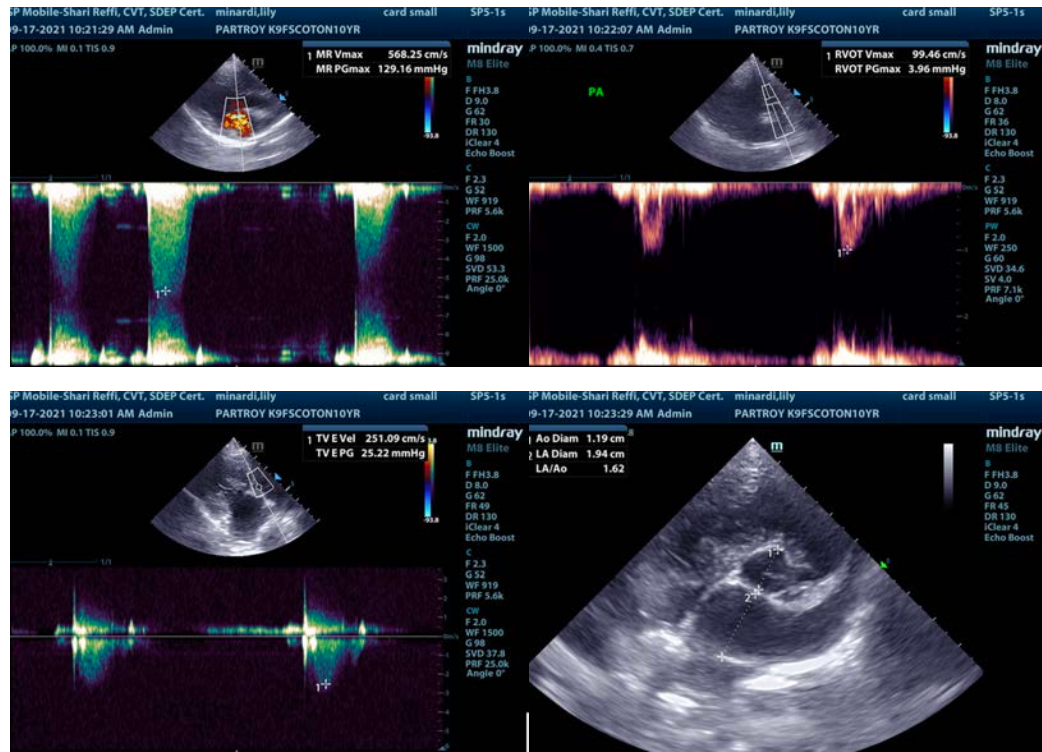
Spayed Female

AGE

10 Years

WEIGHT

Not Given



INTERPRETED BY

Eric Lindquist, DMV
DABVP, Cert. IVUSS

IMAGING PERFORMED BY

Shari Reffi, CVT

HOSPITAL NAME

Parsippany Troy Hills

REFERRING VET

Dr. Dulude

INVOICE

25682

DATE

9/17/21

The information and recommendations provided are based on the images presented by the referring veterinarian. No evaluation can be communicated regarding pathology that was not visible in the image/video clips provided.

Thank you for this referral. If the clinical or image interpretation does not parallel your findings or if I can be of any further assistance please contact me.

Eric Lindquist, DMV, DABVP, Cert. IVUSS, CEO of SonoPath.com
info@SonoPath.com