



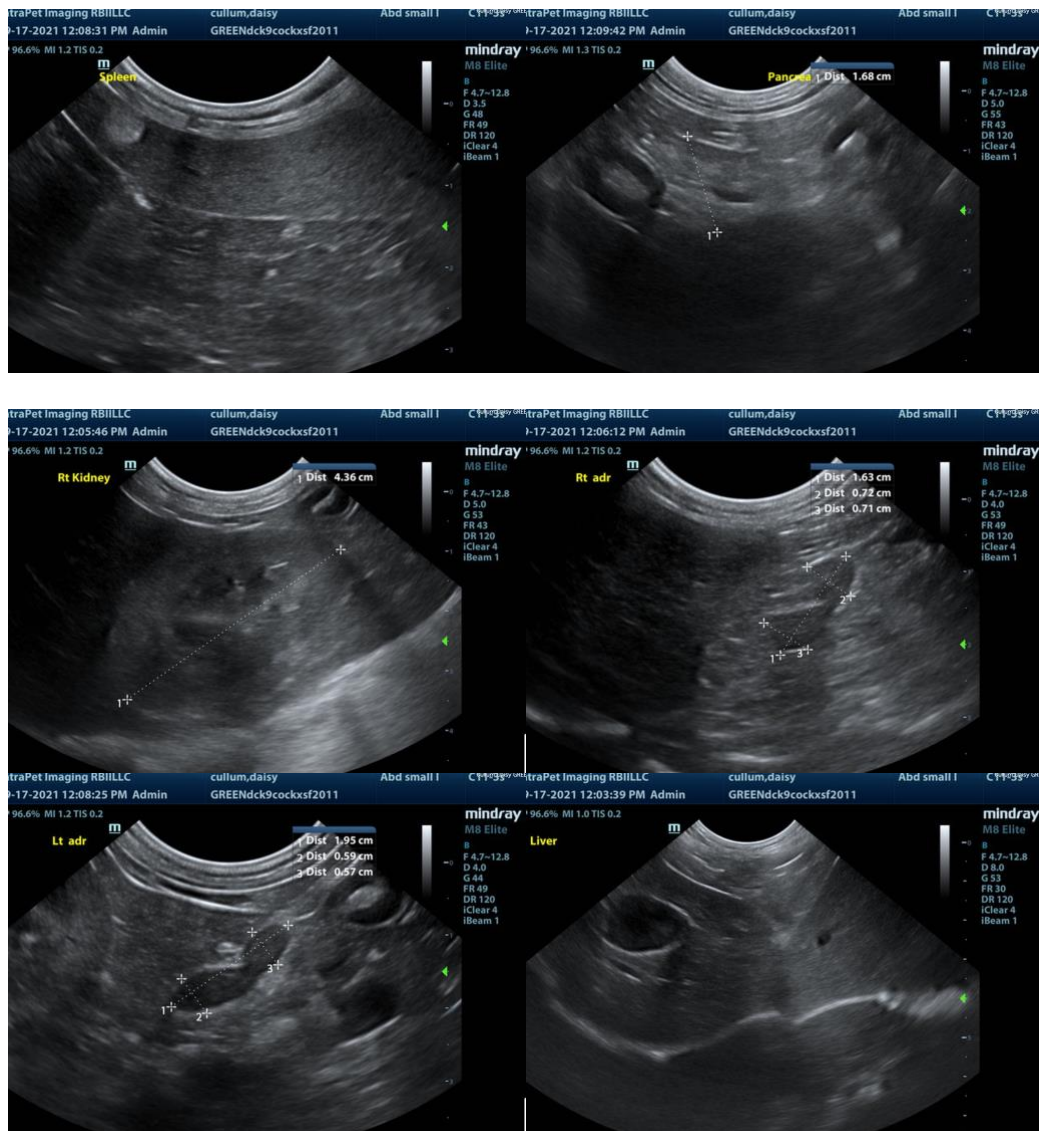
DATE	PRESENTING CLINICAL SIGNS
9/17/21	History: Hx of CCL injury. On routine lab work, noted elevated ALT and ALP in July. Recheck of those values in September revealed continued increases. Clinically patient is otherwise normal. Does have a history of periodic UTI's but no recent ones.
PATIENT	Current Medications: in July, was on Rimadyl 32.5mg SID x 10 days, Tramadol 25mg BID PRN, Dasuquin Advanced. Currently, Dasuquin Advanced, Gabapentin 100mg BID PRN for pain.
Daisy Cullum	Lab Results: 7/29: ALT=138, ALP=599, 9/2: ALT=185, ALP=940.
SPECIES	Radiographs: Not provided by the veterinarian.
Canine	Date of Previous IntraPet Ultrasound: No previous IntraPet scans.
	Sedation: not needed
	Stat Report: not requested
BREED	ULTRASONOGRAPHIC EXAMINATION OF THE ABDOMEN
Cockapoo	<i>Urinary System</i>
SEX	The urinary bladder , trigone, and pelvic urethra presented normal thicknesses and normal tone. The ureters were not visible which is normal. No uroliths or sediment were visualized and anechoic urine was present.
Spayed Female	No evidence of inflammatory or neoplastic changes were noted. Ureteral papillae were normal.
AGE	The kidneys revealed largely normal size and structure, corticomedullary definition and ratio (cortex 1/3 of medulla) were essentially maintained with some minor age-related loss of curvilinear patterns regarding the capsule and C/M junction. The cortices presented largely uniform texture with some increased echogenicity expected for his age patient. Medullary structure differed distinctly from that of the cortex and no evidence of pelvic dilation was present. The right kidney measured 4.36 cm. The left kidney measured 4.34 cm. Slight pinpoint mineralizations were noted in the kidneys, non-obstructive.
3/27/11	<i>Adrenal Glands</i>
WEIGHT	Both adrenal glands were visualized and recognized as having normal shape, size, position and echogenicity for this breed. The phrenic vasculature, glandular echogenicity and detail were unremarkable. Capsule, cortex, and medullary definition were normal for this age patient. The left adrenal gland measured 1.95 cm x 0.59 cm at the cranial pole and 0.57 cm at the caudal pole. The right adrenal gland measured 1.63 cm x 0.72 cm at the caudal pole and 0.71 cm at the cranial pole.
22 lbs	<i>Spleen</i>
INTERPRETED BY	Hyperechoic lipogranulomatous changes noted in the cranial pole of the spleen , measuring 5.0 mm.
Eric Lindquist, DMV DABVP, Cert. IVUSS	<i>Liver</i>
HOSPITAL NAME	The liver presented heterogenous parenchyma with minor increased portal markings and coarse architecture. Slight undulating capsular contour was noted. The gallbladder and common bile duct were unremarkable. This is consistent with chronic inflammatory hepatopathy.
Greenbrier VC	<i>Gastrointestinal</i>
REFERRING VET	Examination of the gastrointestinal tract revealed a stomach and intestine free of stasis, of normal wall thickness, acceptable curvilinear mural detail, and peristaltic activity. Small and large intestine demonstrated normal luminal chyme and stool consistency respectively. No obstructive or overt infiltrative disease was noted. No associated abnormal lymphatic activity was noted.
Dr. Street, III	<i>Pancreas</i>
INVOICE	The pancreas revealed a mild amount of remodeling. The pancreas measured 1.68 cm at the right limb. No evidence of overt active inflammation.
13127	

ULTRASONOGRAPHIC FINDINGS

- Non-specific low grade inflammatory hepatopathy-FNA warranted for further definition
- Lipogranulomatous splenic nodule
- Pancreatic remodeling
- Kidneys, slight pinpoint mineralization, non-obstructive
- Age-related abdominal changes otherwise

INTERPRETATION OF THE FINDINGS & FURTHER RECOMMENDATIONS

Periodic pancreatitis and inflammatory hepatopathy likely in this patient yet no evidence of any significantly active disease.



The information and recommendations provided are based on the images presented by the referring

veterinarian. No evaluation can be communicated regarding pathology that was not visible in the image/video clips provided.

Thank you for this referral. If the clinical or image interpretation does not parallel your findings or if I can be of any further assistance please contact me.

Eric Lindquist, DMV, DABVP, Cert. IVUSS, CEO of SonoPath.com
Eric.Lindquist@SonoPath.com