

## PATIENT

Ava Danielewicz

## SPECIES

Feline

## BREED

Domestic Shorthair

## SEX

Spayed Female

## AGE

5 ½ years

## WEIGHT

11 ½ lbs

## INTERPRETED BY

Eric Lindquist, DMV  
DABVP, Cert. IVUSS

## IMAGING PERFORMED BY

Dr. Todd

## HOSPITAL NAME

Lambs Gap AH

## REFERRING VET

Dr. Knouse

## INVOICE

13112

## DATE

9/17/21

## PRESENTING CLINICAL SIGNS

History: Ava is a five-year-old, FS, DSH cat who was presented 7/7/21 with a history of vomiting partially digested food once weekly since April 2021. Her diet is Science Diet indoor. There is no history of diarrhea. CBC, chemistry and T4 were normal on 7/7/21. fPL=35.3 on 7/7/21. Gabapentin and cerenia were prescribed. On 8/20/21 fPL was rechecked=7.5 Since July, Ava has lost 0.8 pounds. Ava was not fasted, so next week, TLI, folate, cobalamin bloodwork is scheduled.  
7/7/21 fPL=35.3 8/20/21 fPL=7.5

## ULTRASONOGRAPHIC EXAMINATION OF THE ABDOMEN

### Urinary System

The **urinary bladder**, trigone, and pelvic urethra presented normal thicknesses and normal tone. The ureters were not visible which is normal. No uroliths or sediment were visualized and anechoic urine was present. No evidence of inflammatory or neoplastic changes was noted. Ureteral papillae were normal. The pelvic urethra was imaged 2.0 cm beyond the cystourethral junction.

The **kidneys** revealed normal size and structure, corticomedullary definition and ratio for this age. The cortices presented largely uniform texture with normal echogenic relationship to liver and spleen. Medullary structure differed distinctly from the cortex and no evidence of pelvic dilation was present. The capsules were acceptably uniform without significant irregularities. The right kidney measured 4.07 cm. The left kidney measured 3.98 cm.

### Adrenal Glands

Both **adrenal glands** were visualized and recognized as having normal shape, size, position and echogenicity for this breed. The phrenic vasculature, glandular echogenicity and detail were unremarkable. Capsule, cortex, and medullary definition were normal for this age patient. The left adrenal gland measured 0.16 cm. The right adrenal gland measured 0.2 cm.

### Spleen

The **spleen** presented a smooth homogeneous parenchyma hyperechoic to liver and renal cortical parenchyma. The capsule was smooth without noticeable expansion or deviation from within the spleen or adjacent pathology. The splenic vasculature demonstrated normal volume without signs of congestion or thrombosis. No sonographic evidence of acute or chronic inflammatory, neoplastic, or infarctual changes was noted.

### Liver

The **liver** images submitted revealed subjectively normal liver size, contour, and structure. Parenchymal echogenicity was naturally coarse and hypoechoic to the spleen. Vascular and biliary tracts were of normal volume with no evidence of congestion. The gallbladder presented acceptably thin walls with primarily anechoic content. The cystic and common bile ducts were normal. No pathological hepatic lymphadenopathy was evident. No overt structural evidence of inflammatory, infiltrative or regenerative pathology was evident.

### Gastrointestinal

The **stomach** revealed soft shadowing material consistent with hair ball accumulation, measuring approximately 2.0-3.0 cm. The pylorus was free of evident pathology. The small intestine and colon were unremarkable.



**PATIENT**

**Pancreas**

Ava Danielewicz

The base and limbs of the **pancreas** were observed to be largely isoechoic to surrounding omental fat. Pancreatic duct and capsular contour were acceptably normal and parenchyma respected normal curvilinear patterns. No overt evidence of active inflammatory or neoplastic disease was noted.

**SPECIES**

Feline

**ULTRASONOGRAPHIC FINDINGS**

- Hairball density in the stomach
- Unremarkable abdomen otherwise

**BREED**

**INTERPRETATION OF THE FINDINGS & FURTHER RECOMMENDATIONS**

Domestic Shorthair

Medical management should prove effective with recheck sonogram in 3-4 weeks or earlier if clinical signs persist. It is doubtful that surgical intervention would be necessary in this patient.

**SEX**

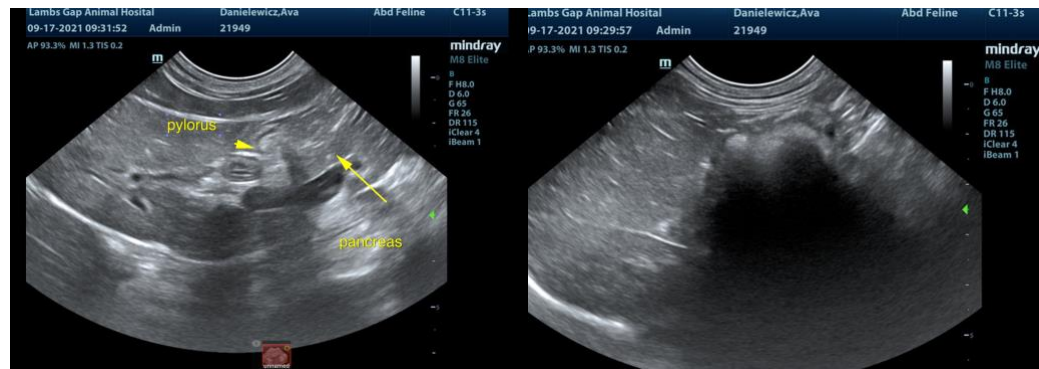
Spayed Female

**AGE**

5 ½ years

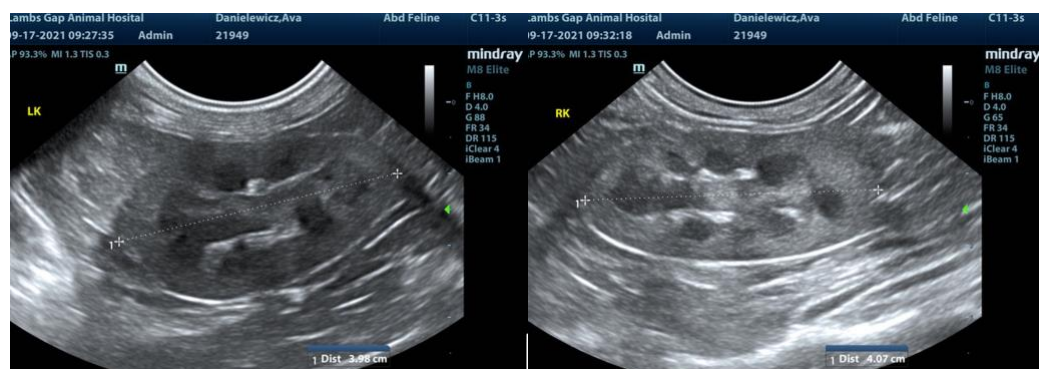
**WEIGHT**

11 ½ lbs



**INTERPRETED BY**

Eric Lindquist, DMV  
DABVP, Cert. IVUSS



**IMAGING PERFORMED BY**

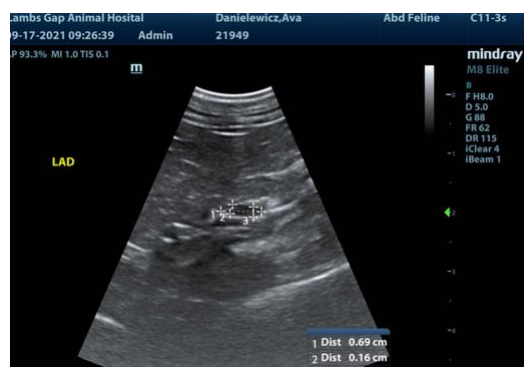Dr. Todd

**HOSPITAL NAME**

Lambs Gap AH

**REFERRING VET**

Dr. Knouse



**INVOICE**

13112

**DATE**

9/17/21



**PATIENT**

Ava Danielewicz

The information and recommendations provided are based on the images presented by the referring veterinarian. No evaluation can be communicated regarding pathology that was not visible in the image/video clips provided.

**SPECIES**

Feline

Thank you for this referral. If the clinical or image interpretation does not parallel your findings or if I can be of any further assistance please contact me.

**BREED**

Domestic Shorthair

**Eric Lindquist**, DMV, DABVP, Cert. IVUSS, CEO of SonoPath.com  
info@SonoPath.com

**SEX**

Spayed Female

**AGE**

5 ½ years

**WEIGHT**

11 ½ lbs

**INTERPRETED BY**

Eric Lindquist, DMV  
DABVP, Cert. IVUSS

**IMAGING  
PERFORMED BY**

Dr. Todd

**HOSPITAL NAME**

Lambs Gap AH

**REFERRING VET**

Dr. Knouse

**INVOICE**

13112

**DATE**

9/17/21