

**PATIENT**

Marvel Stewart

SPECIES

Feline

BREED

Domestic Shorthair

SEX

Neutered Male

AGE

4 years

WEIGHT

13.7 Pounds

INTERPRETED BYEric Lindquist, DMV
DABVP, Cert. IVUSS**IMAGING PERFORMED BY**

Amy Mayhew LVT

HOSPITAL NAME

SVS Imaging Michigan

REFERRING VET

Roadside VC

INVOICE

39450

DATE

9/16/22

PRESENTING CLINICAL SIGNS

History: Came in 9/13 after not eating or drinking for 2 days, fever, and an asthma recheck. We saw him again on 9/15 after having minimal to no improvement.

Abnormal PE/Chem/CBC/UA Results: Bloodwork was run 9/13. Per Dr results were unremarkable and ruled out major problems such as kidney/liver disease. Radiographs taken 9/15 show some calcification, which was noted prior to hernia repair last year. Thickening of the intestines also noted. Question you want answered with an ultrasound: We would like the intestines evaluated.

ULTRASONOGRAPHIC EXAMINATION OF THE ABDOMEN**Urinary System**

The **urinary bladder**, trigone, and pelvic urethra presented normal thicknesses and normal tone. The ureters were not visible which is normal. The bladder revealed a minor amount of suspended and dependent debris. If not already performed urinalysis is indicated. No evidence of inflammatory or neoplastic changes was noted. Ureteral papillae were normal.

The **kidneys** revealed normal size and structure, corticomedullary definition and ratio for this age. The cortices presented largely uniform texture with normal echogenic relationship to liver and spleen. Medullary structure differed distinctly from the cortex and no evidence of pelvic dilation was present. The capsules were acceptably uniform without significant irregularities. The right kidney measured 5.56 cm. The left kidney measured

Adrenal Glands

Both **adrenal glands** were visualized and recognized as having normal shape, size, position and echogenicity for this breed. The phrenic vasculature, glandular echogenicity and detail were unremarkable. Capsule, cortex, and medullary definition were normal for this age patient. The left adrenal gland measured 0.39 cm. The right adrenal gland measured 0.4 cm.

Spleen

The **spleen** presented a smooth homogeneous parenchyma hyperechoic to liver and renal cortical parenchyma. The capsule was smooth without noticeable expansion or deviation from within the spleen or adjacent pathology. The splenic vasculature demonstrated normal volume without signs of congestion or thrombosis. No sonographic evidence of acute or chronic inflammatory, neoplastic, or infarctual changes was noted. The spleen was normal and measured 1.0 cm.

Liver

The **liver** was largely normal with subtle, multi-focal hyperechoic changes. This is suggestive of lipogranulomas or mineralization. These were somewhat obscure, but not a clinical issue. The gallbladder presented acceptably thin walls with primarily anechoic content. The cystic and common bile ducts were normal. No pathological hepatic lymphadenopathy was evident.

IMAGING PERFORMED BY

SVS Mobile Imaging MI 734-637-7711
svsimagingmi@gmail.com



PATIENT

Marvel Stewart

SPECIES

Feline

BREED

Domestic Shorthair

SEX

Neutered Male

AGE

4 years

WEIGHT

13.7 Pounds

INTERPRETED BY

Eric Lindquist, DMV
DABVP, Cert. IVUSS

IMAGING PERFORMED BY

Amy Mayhew LVT

HOSPITAL NAME

SVS Imaging Michigan

REFERRING VET

Roadside VC

INVOICE

39450

DATE

9/16/22

Gastrointestinal

The **gastrointestinal tract** was empty with normal curvilinear patterns. There was no evidence of foreign bodies or neoplastic criteria. The gastrointestinal layering was maintained throughout the GI tract. Minor hyperperistalsis was noted in the small intestine; however, structurally unremarkable GI tract. The mesenteric lymph nodes were reactive and measured 0.58 cm and 0.62 cm.

Pancreas

The base and limbs of the **pancreas** were observed to be largely isoechoic to surrounding omental fat. Pancreatic duct and capsular contour were acceptably normal and parenchyma respected normal curvilinear patterns. No overt evidence of active inflammatory or neoplastic disease was noted. The pancreatic lymph node was reactive and measured 0.38 cm.

ULTRASONOGRAPHIC FINDINGS

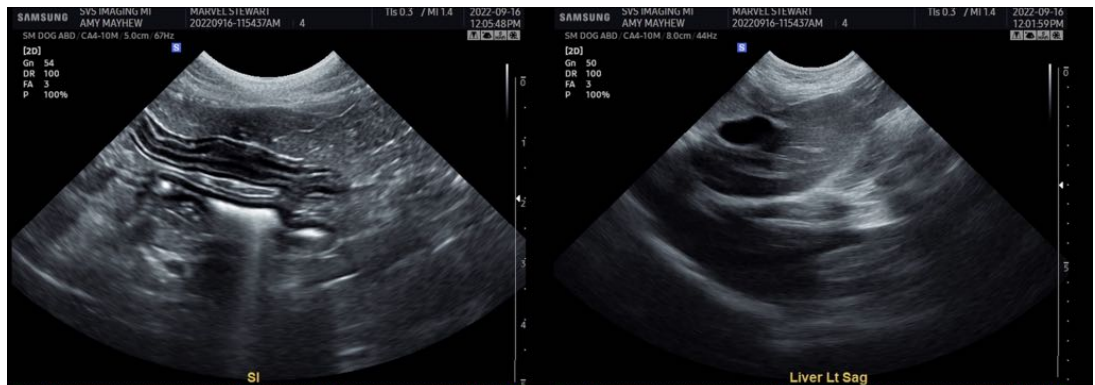
Multifocal hyperechoic hepatic nodules or mineralization, not a clinical issue.

Structurally unremarkable abdomen.

Minor, reactive lymphadenopathy.

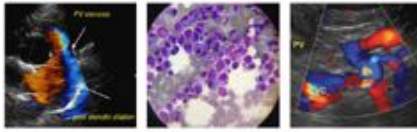
INTERPRETATION OF THE FINDINGS & FURTHER RECOMMENDATIONS

The cause of anorexia is unclear in this patient. There is no evidence of significant visceral disease; however, there is mild, multi-focal reactive lymphadenopathy. Infectious agents, enterotoxins and viral disease should all be considered. Fecal exam is recommended as well. Other causes of anorexia such as pain related disease, CNS, thoracic and orthopedic issues should all be ruled out as potential complicating factors.



IMAGING PERFORMED BY

SVS Mobile Imaging MI 734-637-7711
svsimagingmi@gmail.com



PATIENT

Marvel Stewart

SPECIES

Feline

BREED

Domestic Shorthair

SEX

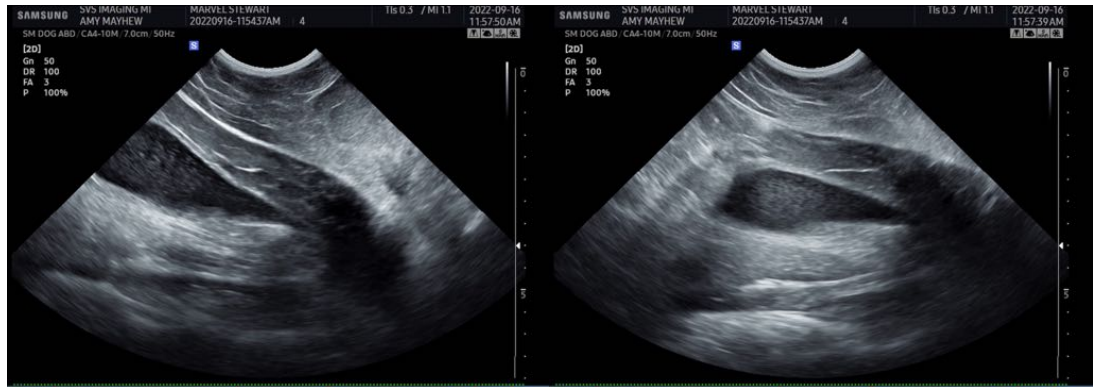
Neutered Male

AGE

4 years

WEIGHT

13.7 Pounds



SEX

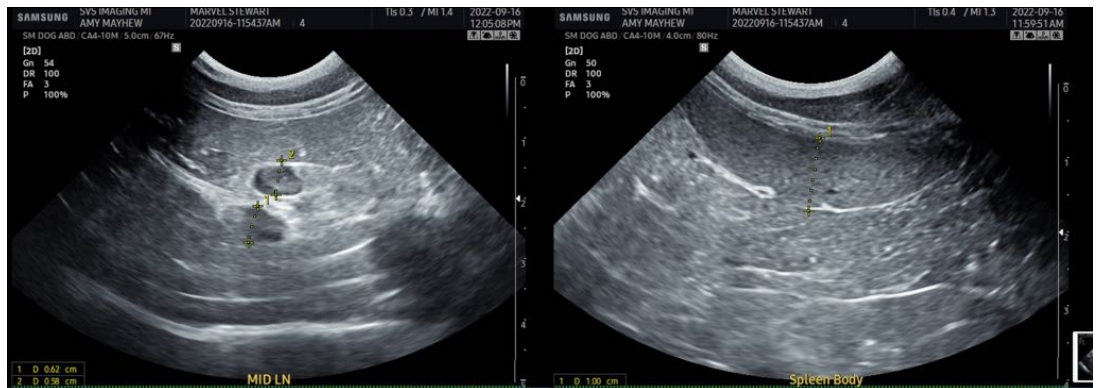
Neutered Male

AGE

4 years

WEIGHT

13.7 Pounds



INTERPRETED BY

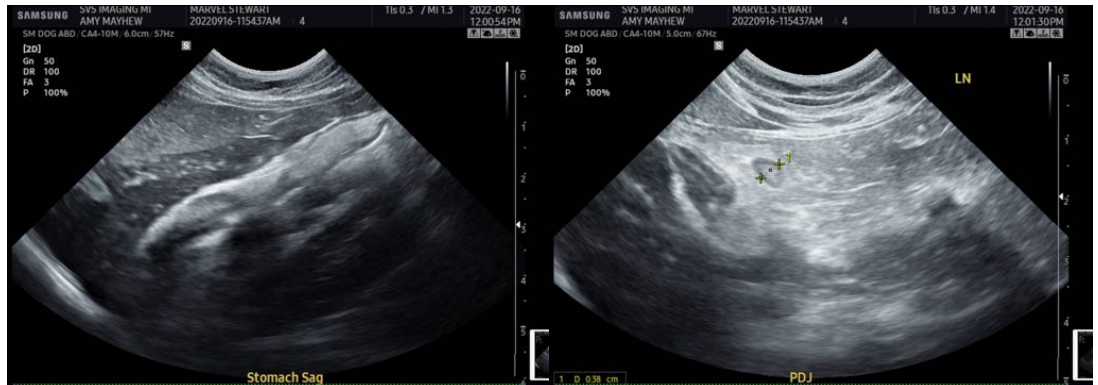
Eric Lindquist, DMV
DABVP, Cert. IVUSS

IMAGING PERFORMED BY

Amy Mayhew LVT

HOSPITAL NAME

SVS Imaging Michigan



REFERRING VET

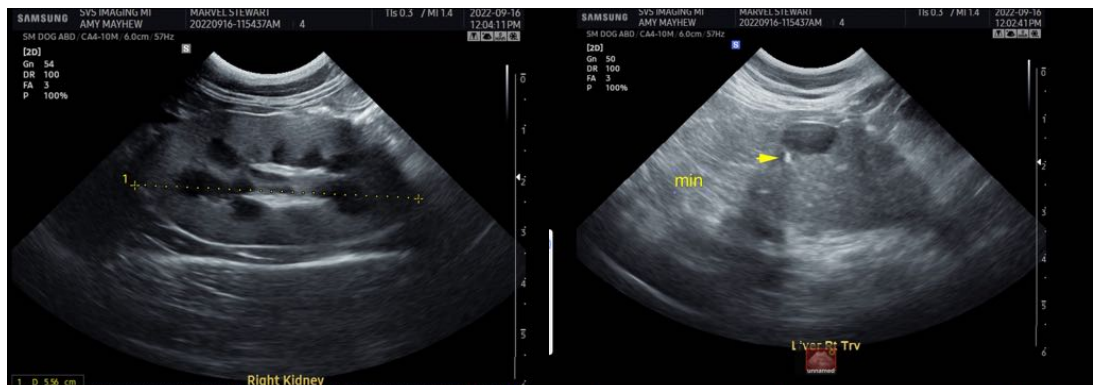
Roadside VC

INVOICE

39450

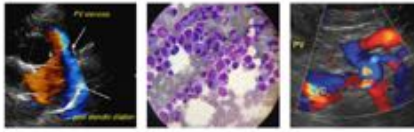
DATE

9/16/22



IMAGING PERFORMED BY

SVS Mobile Imaging MI 734-637-7711
svsimagingmi@gmail.com



PATIENT

Marvel Stewart

The information and recommendations provided are based on the images presented by the referring veterinarian/sonographer. No evaluation can be communicated regarding pathology that was not visible in the image/video clips provided.

SPECIES

Feline

Thank you for this referral. If the clinical or image interpretation does not parallel your findings or if I can be of any further assistance please contact me.

BREED

Domestic Shorthair

Eric Lindquist, DMV, DABVP, Cert. IVUSS, CEO of SonoPath.com
Eric.Lindquist@SonoPath.com

SEX

Neutered Male



The following is an applicable excerpt from the *Curbside Guide to Diagnosis and Treatment of Sonographic Disease* offered by SonoPath.com Lindquist, Fra... Lobetti, and Modler.

AGE

4 years

An essential quick guide for every general practitioner and sonographer.

WEIGHT

13.7 Pounds

<https://sonopath.com/products/curbside-guide-editing-due-release-12012013>

INTERPRETED BY

Eric Lindquist, DMV
DABVP, Cert. IVUSS

Fever of Unknown Origin

<http://www.sonopath.com/FUO>

IMAGING PERFORMED BY

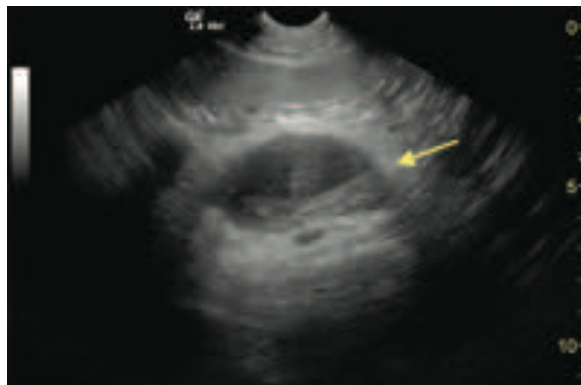
Amy Mayhew LVT

HOSPITAL NAME

SVS Imaging Michigan

REFERRING VET

Roadside VC



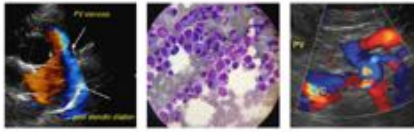
Long axis of the mid-abdomen in a dog with an omental abscess after foreign body penetration from the gastrointestinal tract. The hypoechoic necrotic center of the lesion is surrounded by a thick echogenic capsule and hyperechoic mesenteric fat (arrow) indicating focal peritonitis. The linear echogenic needle (5 cm depth) is barely visible owing to the density of the purulent material contained within the abscess.

INVOICE

39450

DATE

9/16/22

**PATIENT**

Marvel Stewart

SPECIES

Feline

BREED

Domestic Shorthair

SEX

Neutered Male

AGE

4 years

WEIGHT

13.7 Pounds

INTERPRETED BYEric Lindquist, DMV
DABVP, Cert. IVUSS**IMAGING PERFORMED BY**

Amy Mayhew LVT

HOSPITAL NAME

SVS Imaging Michigan

REFERRING VET

Roadside VC

INVOICE

39450

DATE

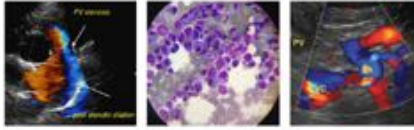
9/16/22

Description: The definition of a fever of unknown origin (FUO) has not been clearly defined for animals. Currently, it is either understood to be a fever that does not resolve within the period one would expect for a “self-limiting infection” being treated with appropriate antimicrobial therapy, or that for which an underlying diagnosis has not been determined despite considerable diagnostic effort. The common causes of FUO were summarized concisely in a presentation at the American College of Veterinary Internal Medicine 2004 Forum. The presenters synthesized information from three veterinary papers on the subject, which suggested the following:

Final Diagnosis	Bennett (dogs & cats)	Dunn and Dunn (dogs only)	Lunn (dogs & one cat)	Total
Infection	21	16	10	47
Immune	18	22	6	46
Bone marrow disease	4	22	2	28
Neoplasia (outside marrow)	0	10	2	12
Miscellaneous	2	12	2	16
No diagnosis	0	19	2	21
TOTALS	45	101	24	170

The types of infection diagnosed in this case series were varied, ranging from discospondylitis (8 cases), blastomycosis (6), and bacterial endocarditis (4), to leishmaniasis (1), prostatitis (1), and *Ehrlichia canis* infection (1); a multitude of other infectious causes also fell within the spectrum. Of the cases in which immune-mediated disease was found, 44% had immune-mediated polyarthritis. Bone marrow diseases included myeloproliferative disease, myelodysplasia (8), lymphocytic leukemia (8), myeloma (3), chronic granulocytic leukemia (3), lymphoblastic leukemia, and malignant histiocytosis. The types of neoplasia located outside the bone marrow included lymphoma (6), metastatic disease (2), and neoplasms of the lung, spleen, and stomach. Finally, miscellaneous diseases included hypertrophic osteodystrophy (6), meningitis (3), portosystemic shunt (3), lymphadenitis (2), panosteitis, and intervertebral disc disease. Overall, the most common causes across all cases were polyarthritis (44), lymphoid neoplasia (15), discospondylitis (8), myelodysplasia (8), hypertrophic osteodystrophy (6), and blastomycosis (6).

Clinical Signs: Animals usually present with either persistent or waxing and waning fevers ranging from 103°F to 106°F. Other clinical signs depend on the underlying cause of the fever. Careful and thorough physical examination is required to assess potential causes.

**PATIENT**

Marvel Stewart

SPECIES

Feline

BREED

Domestic Shorthair

SEX

Neutered Male

AGE

4 years

WEIGHT

13.7 Pounds

INTERPRETED BYEric Lindquist, DMV
DABVP, Cert. IVUSS**IMAGING PERFORMED BY**

Amy Mayhew LVT

HOSPITAL NAME

SVS Imaging Michigan

REFERRING VET

Roadside VC

INVOICE

39450

DATE

9/16/22

Diagnosics: FEO etiologies are partly related to geography, and thus locale or travel history should factor into a practitioner's diagnostic approach. A patient's lifestyle may also provide clues regarding exposure to certain etiologic agents. Therefore, conducting a thorough history can unveil important pieces of the diagnostic puzzle. Physical examination is especially important and should include an inspection of all accessible lymph nodes, palpation and movement of the joints, a fundic examination, a neurological evaluation, spinal and limb palpation and range of motion tests, and a rectal examination.

A minimum database should include a CBC reviewed by a clinical pathologist, as well as a biochemical profile and urinalysis. Retroviral testing should also be considered in cats. In areas where tick-borne disease is prevalent, in-house testing should be performed early. Advanced laboratory work can include: urine culture, blood culture, and infectious disease panels (PCR and/or serology). In dogs, one may screen for the following infectious agents: *Ehrlichia* spp., *Borrelia burgdorferi*, Rock Mountain Spotted Fever, *Bartonella* spp. (culture and PCR), and *Leptospira* spp. in cases of hepatic or renal involvement. In cats, one should evaluate for FeLV, FIV, feline infectious peritonitis (FIP) virus, toxoplasmosis, *Hemoplasma* spp. (*Mycoplasma*), and *Bartonella* spp. (culture and PCR). Testing for *Ehrlichia* spp., *Rickettsia* spp., and *Anaplasma phagocytophilum* can also be considered. A fungal assay is indicated if the patient lives in or has had exposure to a region with a higher incidence of fungal disease. Other infectious disease tests may be performed depending on the geographical location of the pet. Screening for *Brucella* should be done in breeding dogs. Immune-mediated disease screening can include a Coomb's test, a slide agglutination test (if the patient is anemic), and an antinuclear antibody (ANA) test. Immune disease is often a diagnosis of exclusion.

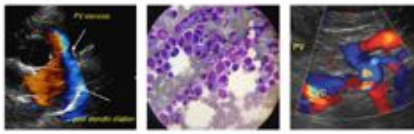
Imaging should include thoracic radiographs, abdominal ultrasound, and/or abdominal radiographs. Ultrasound can be very useful for assessing evidence of cholangiohepatitis, pyelonephritis, chronic urinary tract infection, abscess formation, peritonitis, and neoplasia; it also permits an examination of the intra-abdominal lymph nodes. An echocardiogram can offer assessment for vegetative endocarditis, whereas spinal radiographs offer assessment for discospondylitis. In cases where all other testing has proven negative and the patient has not responded to broad-spectrum antibiotics and supportive care, arthrocentesis should be considered to evaluate for septic joint disease, immune-mediated polyarthritis, and infectious disease. Finally, one can consider assessing the cerebrospinal fluid for meningoencephalitis, GME, and meningitis/arteritis. A bone marrow exam should be performed if blood dyscrasias are noted on the CBC.

Treatment: Treatment of the fever depends entirely on the underlying cause. Ideally, a thorough diagnostic plan will yield a diagnosis that will guide the appropriate therapeutic course. However, if an exhaustive approach has not produced a definitive diagnosis and there is no response to broad-spectrum antibiotics, trial therapy with immunosuppressive agents such as prednisolone can be considered to treat presumed immune-mediated diseases. Given the potential for negative sequelae should an underlying infection be present, one must be certain that the investigation is thorough and monitor the patient's response carefully.

Conclusion: If a documented fever has not responded to antibiotics, antipyretics, or general nursing care, it is important to obtain a diagnosis to guide more specific treatment. A systematic

IMAGING PERFORMED BY

SVS Mobile Imaging MI 734 - 637 - 7711
svsimagingmi@gmail.com



PATIENT

Marvel Stewart

physical examination and thorough history-taking will help inform further diagnostics in addition to what is revealed by the minimum database.

SPECIES

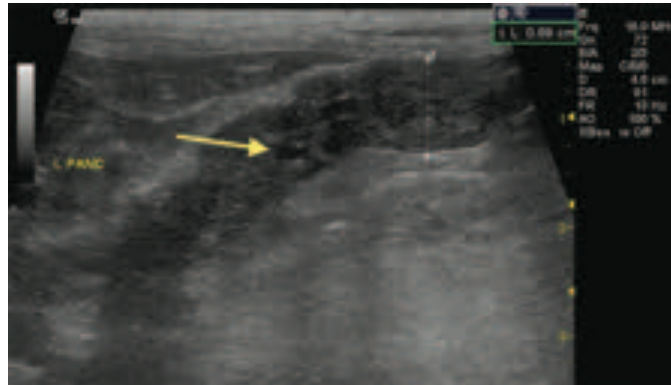
Feline

BREED

Domestic Shorthair

SEX

Neutered Male



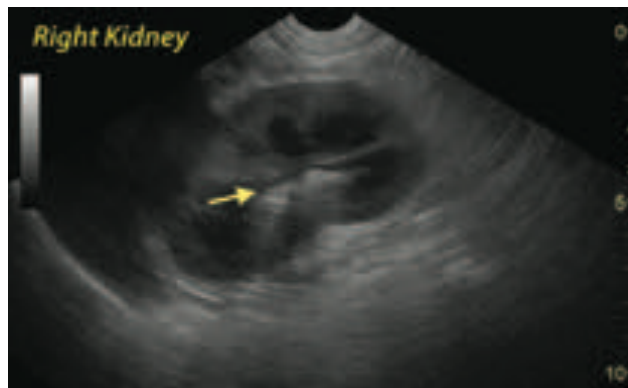Long axis of the left pancreatic limb (between calipers) in a cat with pancreatitis after undergoing a renal transplant. Note the decrease in echogenicity and mild loss of regular echotexture of the swollen and irregularly contoured pancreas. Also note the mild dilation of the pancreatic duct (arrow). Focal peritonitis is evident by increased echogenicity and loss of the linear echotexture of the surrounding mesentery.

AGE

4 years

WEIGHT

13.7 Pounds



Long axis of the right kidney in a dog with pyelonephritis. Note the increased echogenicity and irregular outline of the renal crest and diverticuli and the mild dilation of the renal pelvis (arrow).

INTERPRETED BY

Eric Lindquist, DMV
DABVP, Cert. IVUSS

IMAGING PERFORMED BY

Amy Mayhew LVT

HOSPITAL NAME

SVS Imaging Michigan

REFERRING VET

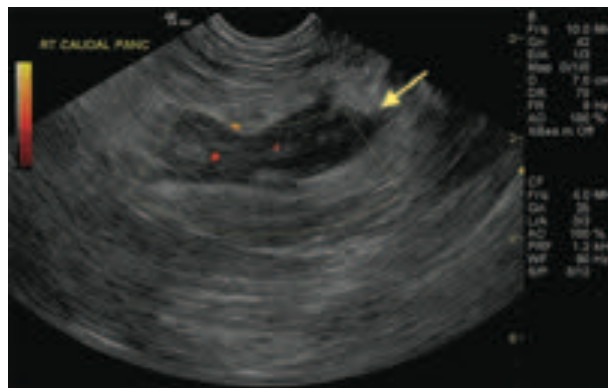Roadside VC

INVOICE

39450

DATE

9/16/22

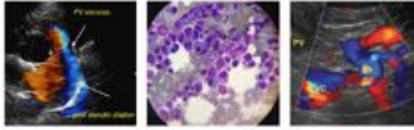


Long axis of the right pancreatic limb in a dog with acute pancreatitis. The swollen hypoechoic pancreas is embedded in hyperechoic mesenteric fat (arrow). Note the regional differences in blood flow intensity within the parenchyma as demonstrated by Power Doppler interrogation compatible with multifocal disruption of vascularization as a sequela of the severe inflammation.

References:

IMAGING PERFORMED BY

SVS Mobile Imaging MI 734-637-7711
svsimagingmi@gmail.com



PATIENT

Marvel Stewart

Bennet D. Diagnosis of pyrexia of unknown origin. *In Practice* 1995;17(10):470-81.

Dunn KJ, Dunn JK. Diagnostic investigations in 101 dogs with pyrexia of unknown origin. *J Sm Anim Pract* 1998;39(12):574-80.

SPECIES

Feline

Flood J. The diagnostic approach to fever of unknown origin in cats. *Compend Contin Educ Vet* 2009;31(1):26-31.

BREED

Domestic Shorthair

Flood J. The diagnostic approach to fever of unknown origin in dogs. *Compend Contin Educ Vet* 2009;31(1):14-21.

SEX

Neutered Male

Lappin MR. The role of blood borne pathogens in feline fever of unknown origin. Proceedings from the American College of Veterinary Internal Medicine, Denver, CO, June 15-18, 2011.

AGE

4 years

Lunn KF. Fever of unknown origin: a systematic approach to diagnosis. *Compend Contin Educ Vet* 2001;23(11):976-92.

Lunn KF. Fever of unknown origin: appropriate choice of diagnostic tests. Proceedings from the American College of Veterinary Internal Medicine, Minneapolis, MN, June 9-12, 2004.

WEIGHT

13.7 Pounds

INTERPRETED BY

Eric Lindquist, DMV
DABVP, Cert. IVUSS

IMAGING PERFORMED BY

Amy Mayhew LVT

HOSPITAL NAME

SVS Imaging Michigan

REFERRING VET

Roadside VC

INVOICE

39450

DATE

9/16/22