



PATIENT

Harper Lambert

SPECIES

Canine

BREED

Dachshund Mix

SEX

Spayed female

AGE

7 years

WEIGHT

9.6 lbs

INTERPRETED BY

Eric Lindquist, DMV
DABVP, Cert. IVUSS

IMAGING PERFORMED BY

Jill Rumachik

HOSPITAL NAME

Clarity Imaging LLC

REFERRING VET

Dr. Sheldon

PRESENTING CLINICAL SIGNS

History of heartworm disease; new onset arrhythmia that doesn't seem related to respirations (ECG not done)

ULTRASONOGRAPHIC EXAMINATION OF THE HEART

The echocardiogram in this patient demonstrated normal **left atrial** size based on 3 separate methods of LA evaluation. The **mitral** valve was slightly thickened. The **left ventricle** presented normal thicknesses with linear contour and was not dilated nor restricted. The **myocardium** presented normal echogenicity without subjective evidence of significant fibrotic or ischemic disease. **Contractility** of the ventricular walls was adequate and in normal range for this patient evidenced by the fractional shortening measurement and subjective evaluation of the different regions of the myocardium. The **left ventricular outflow** tract demonstrated normal laminar flow and subjective structural integrity. The **right atrium** and auricle revealed normal size, structure and content. No evidence of masses was noted. **Tricuspid** valvular assessment demonstrated adequate linear morphology and kinesis. The **right ventricle** was of normal size (1/3 diameter of LV), chordae structure, myocardial echogenicity and thickness. **Pulmonary outflow** tract assessment revealed normal valve structure, laminar flow, and diameter (approx.1:1 pa/ao ratio). No visible **pericardial** or free pleura fluid was noted. The cranial **mediastinum and pericardial and extra-cardiac regions** were free of masses in the visible window.

CANINE CARDIAC PARAMETERS	MR VMAX (m/s)	TR VMAX (m/s)	LA/AO (Boon method)	LA/AO (Heart Base; Swe)	FS (%)	EF (%)	EPSS (cm)
NORMAL PARAMETER	4.5-5.5	<2.7	1.3	<1.6	28-40	40-100	<0.6
PATIENT	-	-	1.15	1.3	35	-	NM
CANINE CARDIAC PARAMETERS	HR (BPM)	AV VMAX (m/s)	PV MAX (m/s)	BODY WEIGHT	LA 2D short axis Base view (cm)	LVIDd Avg; 2D and m- mode short axis (cm)	LVIDs Avg; 2D and m- mode short axis (cm)
NORMAL PARAMETER	50-100	0.7-1.7	0.7-1.6	BELOW	BELOW	BELOW	BELOW
PATIENT	80	1.3	0.5	9.6 lbs	1.9	1.8	

ULTRASONOGRAPHIC FINDINGS

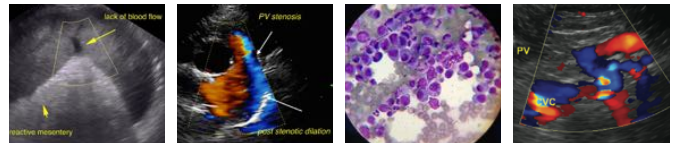
Vegetative mitral valve.
Stage B1 valvular disease.

INVOICE

39447

DATE

9/16/22



PATIENT

Harper Lambert

SPECIES

Canine

BREED

Dachshund Mix

SEX

Spayed female

AGE

7 years

WEIGHT

9.6 lbs

INTERPRETED BY

Eric Lindquist, DMV
DABVP, Cert. IVUSS

IMAGING PERFORMED BY

Jill Rumachik

HOSPITAL NAME

Clarity Imaging LLC

REFERRING VET

Dr. Sheldon

INVOICE

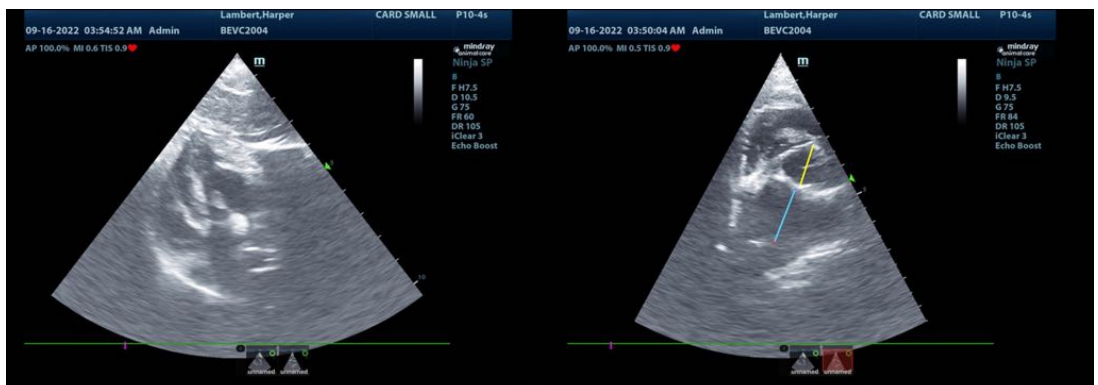
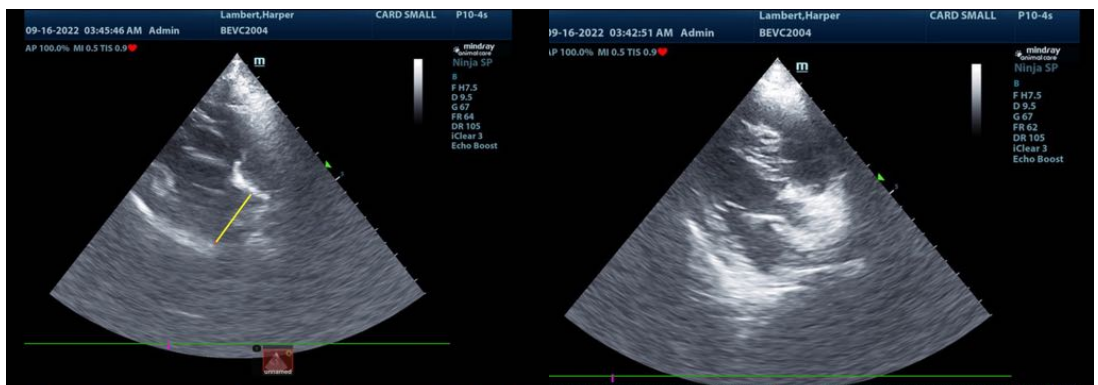
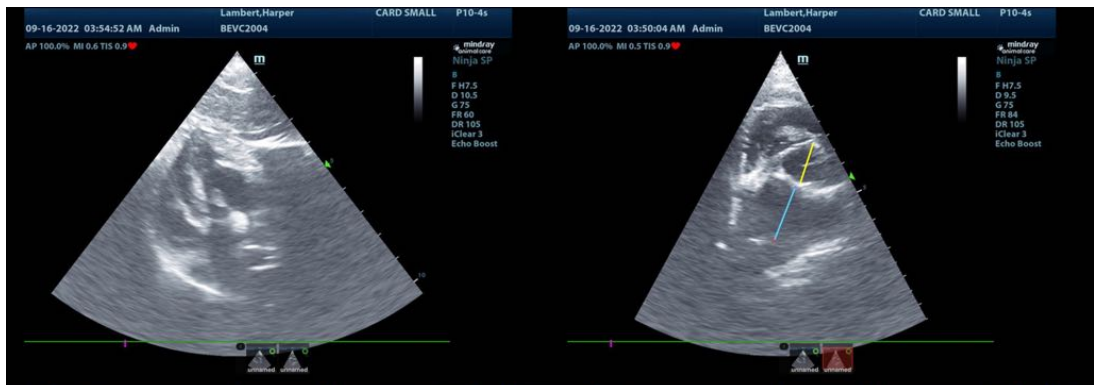
39447

DATE

9/16/22

INTERPRETATION OF THE FINDINGS & FURTHER RECOMMENDATIONS

This is not clinically significant. There was no evidence of heartworm or other disease. Trivial mitral insufficiency was noted on color flow and pulse wave Doppler. No arrhythmogenic activity was noted during the echocardiogram. No therapy is warranted. There was no evidence of macroscopic heartworms.





PATIENT

Harper Lambert

SPECIES

Canine

BREED

Dachshund Mix

SEX

Spayed female

AGE

7 years

WEIGHT

9.6 lbs

INTERPRETED BY

Eric Lindquist, DMV
DABVP, Cert. IVUSS

IMAGING PERFORMED BY

Jill Rumachik

HOSPITAL NAME

Clarity Imaging LLC

REFERRING VET

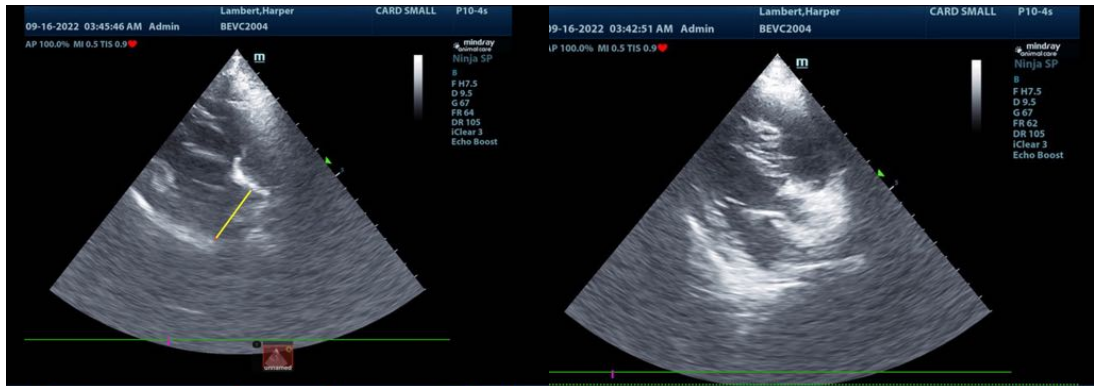Dr. Sheldon

INVOICE

39447

DATE

9/16/22



The information and recommendations provided are based on the images presented by the referring veterinarian/sonographer. No evaluation can be communicated regarding pathology that was not visible in the image/video clips provided.

Thank you for this referral. If the clinical or image interpretation does not parallel your findings or if I can be of any further assistance please contact me.

Eric Lindquist, DMV, DABVP, Cert. IVUSS, CEO of SonoPath.com
info@SonoPath.com