



**PATIENT**

Ares Engelhart

**SPECIES**

Canine

**BREED**

Belgian Malinois

**SEX**

Male

**AGE**

3 years

**WEIGHT**

80.4 lbs

**INTERPRETED BY**

Eric Lindquist, DMV  
DABVP, Cert. IVUSS

**IMAGING PERFORMED BY**

Dr. Brenner

**HOSPITAL NAME**

Riverside Animal Clinic

**REFERRING VET**

Dr. Brenner

**INVOICE**

39462

**DATE**

9/17/22

**PRESENTING CLINICAL SIGNS**

History: Working police dog originated from Mexico. August 2021 bloody drainage after urination seen twice. Rectal normal prostate palpation. Treated Clavamox 250mg 2 BID for 10 days. Infection cleared via urinalysis. October 7, 2021 stranguria, interrupted urine stream, urine in police truck. Cytocentesis sample negative culture. Improved without intervention. August 19, 2022 history of once every 3 months stranguria comes and goes.  
Abnormal PE/Chem/CBC/UA Results: August 20, 2021 UA USG 1.048, pH 8.5, RBC3+, WBC 1+. August 30, 2021 UA USG 1.024, pH 8.0, no RBC, WBC 1+. October 7, 2021 UA USG 1.040, pH 8.5 WBC TNTC, Culture negative. November 29, 2021 UA USG 1.011, pH 7.0, rare WBC.

**ULTRASONOGRAPHIC EXAMINATION OF THE ABDOMEN**

**Urinary System**

The **urinary bladder**, trigone, and pelvic urethra presented normal thicknesses and normal tone. The ureters were not visible which is normal. No uroliths or sediment were visualized and anechoic urine was present. No evidence of inflammatory or neoplastic changes was noted. Ureteral papillae were normal.

The prostate revealed large cystic structures measuring approximately 4.0 cm on the left lobe and 2.0 cm on the right. Echogenic debris was noted in the cystic structures. The prostate itself measured 6.0 cm in width and was consistent with BPH with abscessation or benign cysts.

The **kidneys** revealed normal size and structure, corticomedullary definition and ratio for this age. The cortices presented largely uniform texture with normal echogenic relationship to liver and spleen. Medullary structure differed distinctly from the cortex and no evidence of pelvic dilation was present. The capsules were acceptably uniform without significant irregularities. The right kidney measured 8.04 cm. The left kidney measured 7.38 cm.

**Adrenal Glands**

Both **adrenal glands** were visualized and recognized as having normal shape, size, position and echogenicity for this breed. The phrenic vasculature, glandular echogenicity and detail were unremarkable. Capsule, cortex, and medullary definition were normal for this age patient. The left adrenal gland measured 1.8 x 0.59 cm at the caudal pole and 0.59 cm at the cranial pole. The right adrenal gland measured 1.33 x 0.72 cm.

**ULTRASONOGRAPHIC FINDINGS**

BPH with abscessation or benign cysts.

**INTERPRETATION OF THE FINDINGS & FURTHER RECOMMENDATIONS**

Ultrasound-guided drainage of the cystic structures +/- injection of Enrofloxacin if the material is purulent followed by neutering is indicated.



**PATIENT**

Ares Engelhart

**SPECIES**

Canine

**BREED**

Belgian Malinois

**SEX**

Male

**AGE**

3 years

**WEIGHT**

80.4 lbs

**INTERPRETED BY**

Eric Lindquist, DMV  
DABVP, Cert. IVUSS

**IMAGING PERFORMED BY**

Dr. Brenner

**HOSPITAL NAME**

Riverside Animal Clinic

**REFERRING VET**

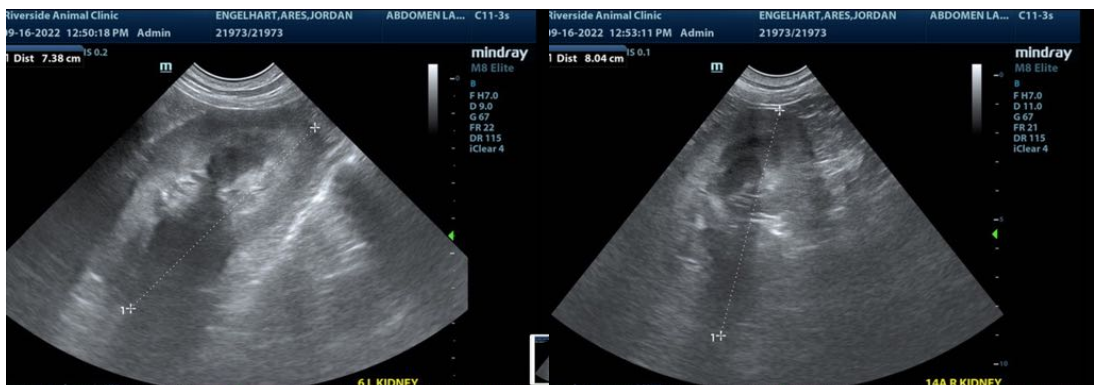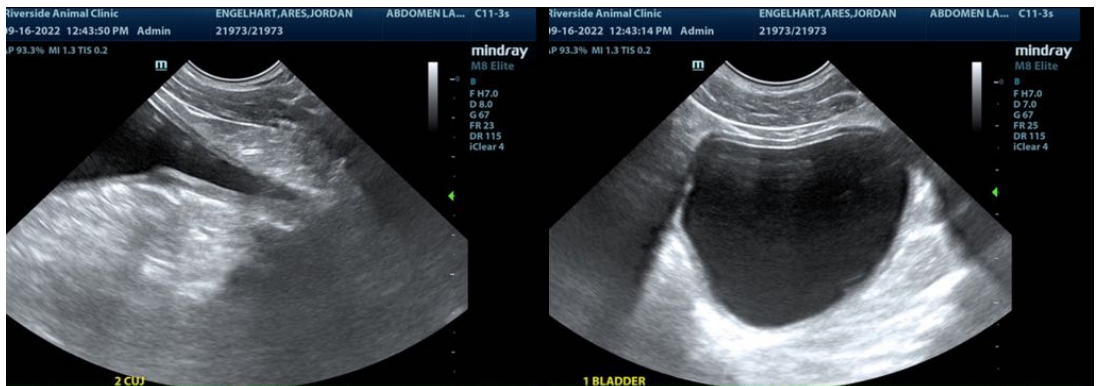
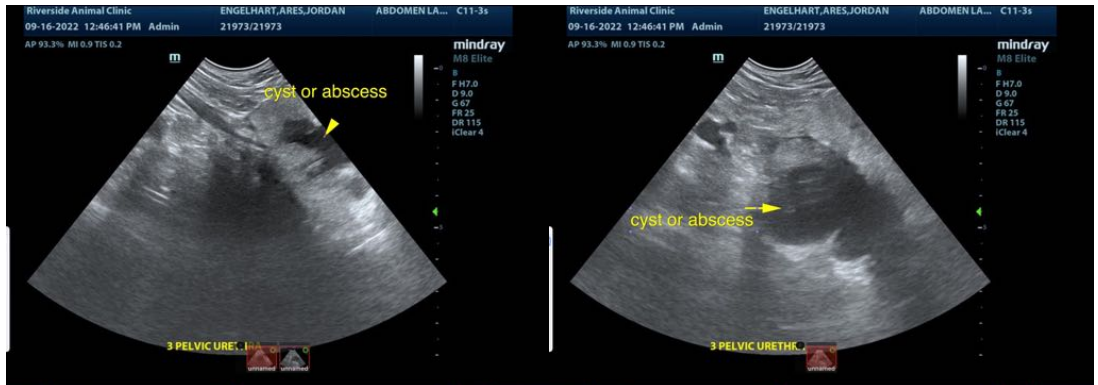Dr. Brenner

**INVOICE**

39462

**DATE**

9/17/22





**PATIENT**

Ares Engelhart

**SPECIES**

Canine

**BREED**

Belgian Malinois

**SEX**

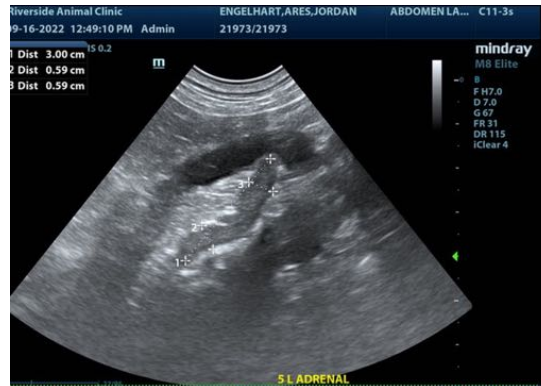Male

**AGE**

3 years

**WEIGHT**

80.4 lbs



The information and recommendations provided are based on the images presented by the referring veterinarian/sonographer. No evaluation can be communicated regarding pathology that was not visible in the image/video clips provided.

Thank you for this referral. If the clinical or image interpretation does not parallel your findings or if I can be of any further assistance please contact me.

**Eric Lindquist**, DMV, DABVP, Cert. IVUSS, CEO of SonoPath.com  
info@SonoPath.com

**INTERPRETED BY**

Eric Lindquist, DMV  
DABVP, Cert. IVUSS

**IMAGING PERFORMED BY**

Dr. Brenner

**HOSPITAL NAME**

Riverside Animal Clinic

**REFERRING VET**

Dr. Brenner

**INVOICE**

39462

**DATE**

9/17/22