



PATIENT

Hilderbrand Sammy
Mack

SPECIES

Canine

BREED

Terrier Mix

SEX

Neutered male

AGE

9 years

WEIGHT

15 lbs

INTERPRETED BY

Eric Lindquist, DMV
DABVP, Cert. IVUSS

IMAGING PERFORMED BY

Dr. Mack

HOSPITAL NAME

Northside VC

REFERRING VET

Dr. Mack

INVOICE

91874

DATE

9/16/21

PRESENTING CLINICAL SIGNS

History: Hx of chronic pancreatitis, Currently anorexic
Abnormal PE/Chem/CBC/UA Results: ALP 1500 UA unremarkable

ULTRASONOGRAPHIC EXAMINATION OF THE ABDOMEN

Urinary System

The **urinary bladder**, trigone, and pelvic urethra presented normal thicknesses and normal tone. The ureters were not visible which is normal. No uroliths or sediment were visualized and anechoic urine was present. No evidence of inflammatory or neoplastic changes was noted. Ureteral papillae were normal.

The **kidneys** revealed largely normal size and structure, corticomedullary definition and ratio (cortex 1/3 of medulla) were essentially maintained with some age-related loss of curvilinear patterns regarding the capsule and C/M junction. The cortices presented largely uniform texture with some increased echogenicity expected for this age patient. Medullary structure differed distinctly from that of the cortex and no evidence of pelvic dilation was present. The right kidney measured 4.5 cm.

Adrenal Glands

The left **adrenal gland** was visualized and recognized as having normal shape, size, position and echogenicity for this breed. The phrenic vasculature, glandular echogenicity and detail were unremarkable. Capsule, cortex, and medullary definition were normal for this age patient. The left adrenal gland measured 0.5 cm. The region of the right adrenal gland was imaged with no evidence of pathology.

Spleen

The **spleen** presented a smooth homogeneous parenchyma hyperechoic to liver and renal cortical parenchyma. The capsule was smooth without noticeable expansion or deviation from within the spleen or adjacent pathology. The splenic vasculature demonstrated normal volume without signs of congestion or thrombosis. No sonographic evidence of acute or chronic inflammatory, neoplastic, or infarctual changes was noted.

Liver

The **liver** was uniformly swollen with minor, excessive gallbladder debris and over distension with dependent and suspended bile without evidence of overt mucocele formation. However, excessive sludge was present. The liver presented coarse architecture with mildly increased portal markings and subtle, mixed echogenic changes. This is consistent with vacuolar hepatopathy and some level of remodeling and history of inflammatory component. There was no overt suspicion of neoplasia.



PATIENT

Hilderbrand Sammy
Mack

SPECIES

Canine

BREED

Terrier Mix

SEX

Neutered male

AGE

9 years

WEIGHT

15 lbs

INTERPRETED BY

Eric Lindquist, DMV
DABVP, Cert. IVUSS

IMAGING PERFORMED BY

Dr. Mack

HOSPITAL NAME

Northside VC

REFERRING VET

Dr. Mack

INVOICE

91874

DATE

9/16/21

Gastrointestinal

Examination of the **gastrointestinal tract** revealed a stomach and intestine free of stasis, of normal wall thickness, acceptable curvilinear mural detail, and peristaltic activity. Small and large intestine demonstrated normal luminal chyme and stool consistency respectively. No obstructive or overt infiltrative disease was noted.

Pancreas

The **pancreas** revealed heterogenous parenchymal changes with regional lymphadenopathy.

Free Abdomen

Multi-focal, hypoechoic lymph nodes were enlarged, rounded and measured up to 1.5 cm with peripheral inflammation. Reactive mesentery was noted around the lymph nodes.

ULTRASONOGRAPHIC FINDINGS

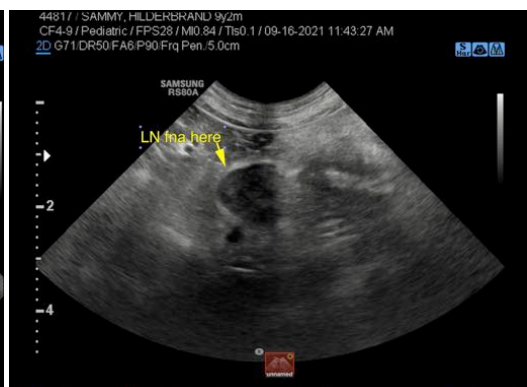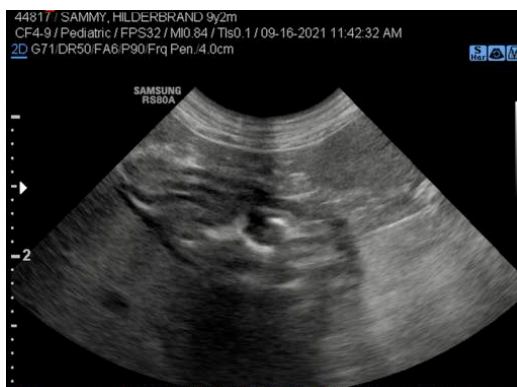Multi-centric lymphadenopathy with heterogenous pancreatic changes.

Chronic active pancreatitis.

Otherwise, geriatric abdomen with benign hepatopathy.

INTERPRETATION OF THE FINDINGS & FURTHER RECOMMENDATIONS

I recommend ultrasound-guided FNA of the most accessible lymph nodes as well as the liver. Reactive lymphadenitis versus emerging round cell neoplasia are the primary concerns.





PATIENT

Hilderbrand Sammy
Mack

SPECIES

Canine

BREED

Terrier Mix

SEX

Neutered male

AGE

9 years

WEIGHT

15 lbs

INTERPRETED BY

Eric Lindquist, DMV
DABVP, Cert. IVUSS

IMAGING PERFORMED BY

Dr. Mack

HOSPITAL NAME

Northside VC

REFERRING VET

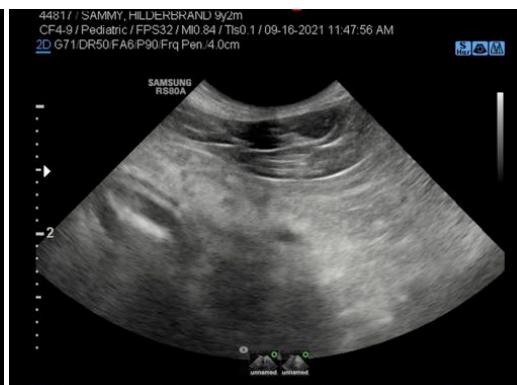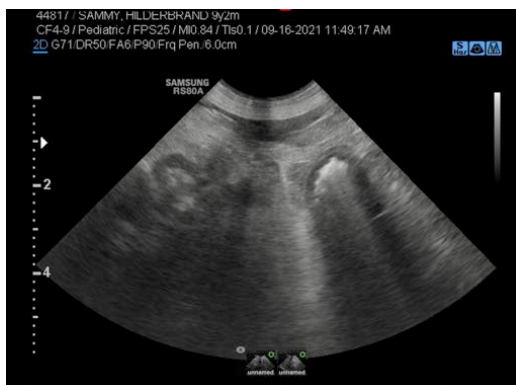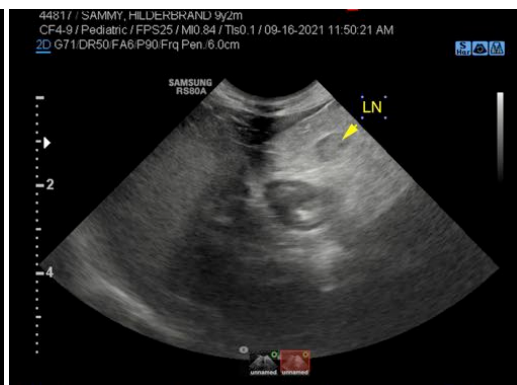
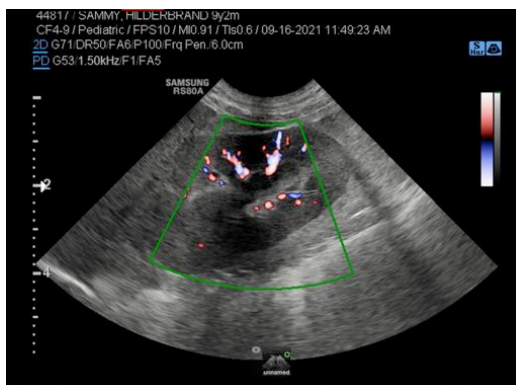
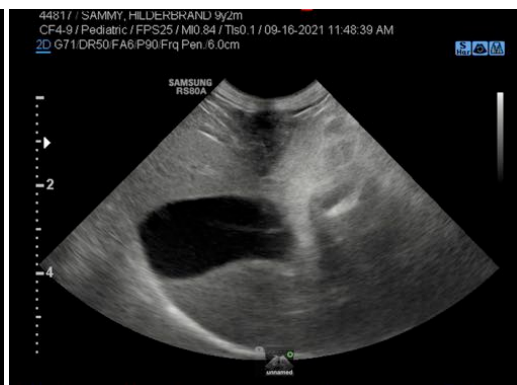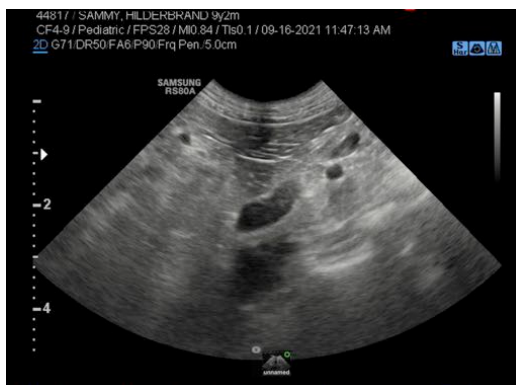Dr. Mack

INVOICE

91874

DATE

9/16/21



The information and recommendations provided are based on the images presented by the referring veterinarian. No evaluation can be communicated regarding pathology that was not visible in the image/video clips provided.

Thank you for this referral. If the clinical or image interpretation does not parallel your findings or if I can be of any further assistance please contact me.

Eric Lindquist, DMV, DABVP, Cert. IVUSS, CEO of SonoPath.com
info@SonoPath.com