



**PATIENT PRESENTING CLINICAL SIGNS**

Little Miss Green

History: History of progressively loud heart murmur, systolic. Asymptomatic. Sleeping respiratory rate normal. History of seizures - on phenobarbital.

**SPECIES**

Abnormal PE/Chem/CBC/UA Results: CHEMISTRY normal

Canine

**ULTRASONOGRAPHIC EXAMINATION OF THE HEART**

**BREED**

Poodle Cross

The echocardiogram in this patient demonstrated an enlarged **left atrial** size based on 3 different LA measurement methods. Chamber volumes and echogenicity were normal. The cranial and caudal **mitral** valve leaflets presented vegetative thickening consistent with endocardiosis. Prolapse of the anterior mitral valve leaflet was noted. Doppler indicated measurable insufficiency. The **left ventricle** presented normal thicknesses with linear contour and was not dilated nor restricted. The **myocardium** presented normal echogenicity without subjective evidence of significant fibrotic or ischemic disease.

**SEX**

Spayed female

**Contractility** of the ventricular walls was adequate and in normal range for this patient evidenced by the fractional shortening measurement and subjective evaluation of the different regions of the myocardium. The **left ventricular outflow** tract demonstrated normal laminar flow and subjective structural integrity. The **right atrium** and auricle revealed normal size, structure and content. No evidence of masses was noted or chamber overload. **Tricuspid** valvular assessment demonstrated adequate linear morphology. The **right ventricle** was of normal size (1/3 diameter of LV), chordae structure, myocardial echogenicity and thickness. **Pulmonic** tract assessment revealed normal valve structure, laminar flow, and diameter (approx.1:1 pa/ao ratio). No visible **pericardial** or free pleura fluid was noted. No echographically detectable evidence of infiltrative disease was visible. The cranial **mediastinum and pericardial regions** were free of masses in the visible window.

**AGE**

14 years

**WEIGHT**

8.8 lbs

**INTERPRETED BY**

Eric Lindquist, DMV  
DABVP, Cert. IVUSS

CANINE CARDIAC PARAMETERS	MR VMAX (m/s)	TR VMAX (m/s)	LA/AO (Boon method)	LA/AO (Heart Base; Swe)	FS (%)	EF (%)	EPSS (cm)
NORMAL PARAMETER	4.5-5.5	<2.7	1.3	<1.6	28-40	40-100	<0.6
PATIENT	6.0		2.0	2.2	65	91	0.1
CANINE CARDIAC PARAMETERS	HR (BPM)	AV VMAX (m/s)	PV MAX (m/s)	BODY WEIGHT	LA 2D short axis Base view (cm)	LVIDd Avg; 2D and m- mode short axis (cm)	LVIDs Avg; 2D and m- mode short axis (cm)
NORMAL PARAMETER	50-100	0.7-1.7	0.7-1.6	BELOW	BELOW	BELOW	BELOW
PATIENT		1.5	0.8	8.8 lbs	3.5	2.76	

**IMAGING PERFORMED BY**

Dr. Gunther

**HOSPITAL NAME**

New Frontier AMC

**REFERRING VET**

Dr. Gunther

**INVOICE**

32939

**DATE**

9/15/22

**ULTRASONOGRAPHIC FINDINGS**

Stage B2 valvular disease.



**PATIENT**

Little Miss Green

**SPECIES**

Canine

**BREED**

Poodle Cross

**SEX**

Spayed female

**AGE**

14 years

**WEIGHT**

8.8 lbs

**INTERPRETED BY**

Eric Lindquist, DMV  
DABVP, Cert. IVUS

**IMAGING PERFORMED BY**

Dr. Gunther

**HOSPITAL NAME**

New Frontier AMC

**REFERRING VET**

Dr. Gunther

**INVOICE**

32939

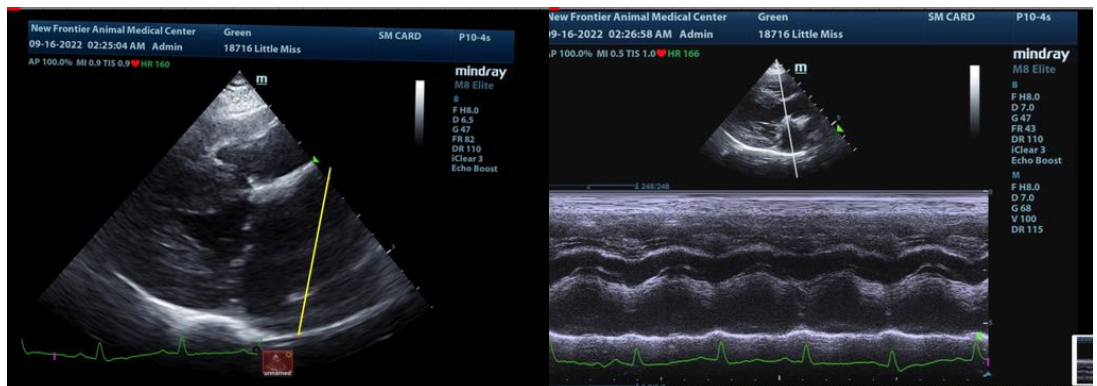
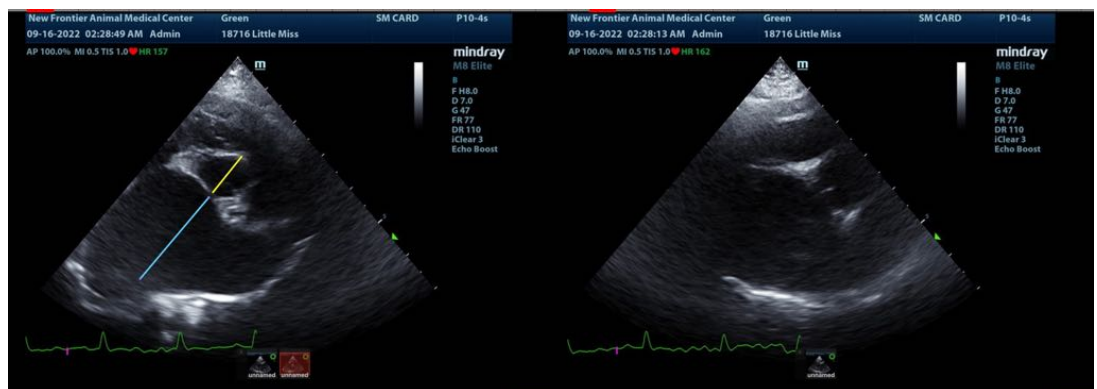
**DATE**

9/15/22

**INTERPRETATION OF THE FINDINGS & FURTHER RECOMMENDATIONS**

Blood pressure measurements are warranted. If systolic pressure is > 160 then ace inhibitor is indicated. Chest radiographs are warranted to assess for any signs of early pulmonary edema. Pimobendan is recommended at 0.3 mg/kg is warranted +/- ace inhibitor and Spironolactone deepening on blood pressure measurements.

The heart has some volume overload and is working to compensate for the valvular insufficiency. Target respiratory rate is < 20 resp/minute after therapy. After initiating therapy, I recommend recheck on the clinical exam, BUN, Creatinine, USG, Chest radiographs & Blood pressure in 5-7 days. Recheck echo in 1 month. Earlier if clinical decompensation is occurring. I do not recommend anesthesia at this time until stabilization has occurred on the recommended medications. Repeat preanesthetic echo is ideal if anesthesia is eventually necessary





**PATIENT**

Little Miss Green

**SPECIES**

Canine

**BREED**

Poodle Cross

**SEX**

Spayed female

**AGE**

14 years

**WEIGHT**

8.8 lbs

**INTERPRETED BY**

Eric Lindquist, DMV  
DABVP, Cert. IVUS

**IMAGING PERFORMED BY**

Dr. Gunther

**HOSPITAL NAME**

New Frontier AMC

**REFERRING VET**

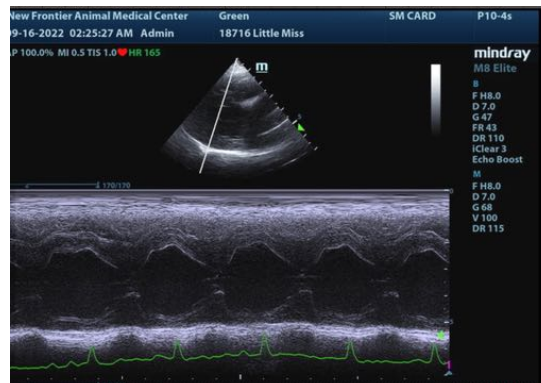
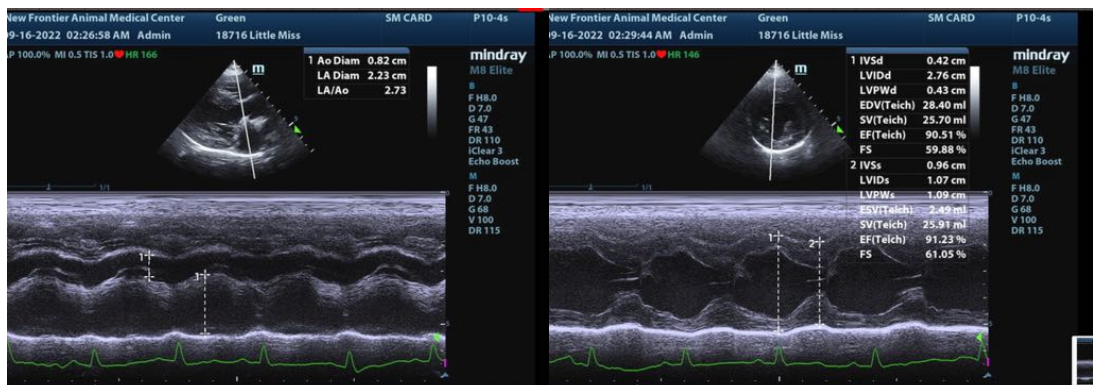
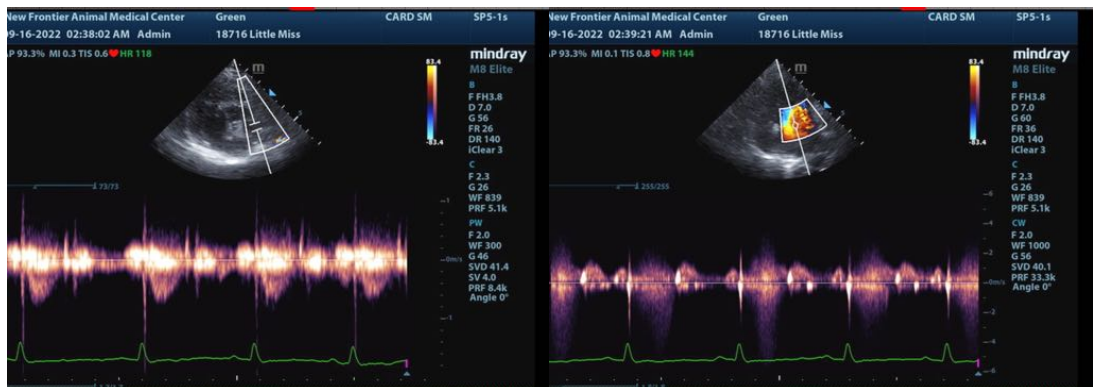
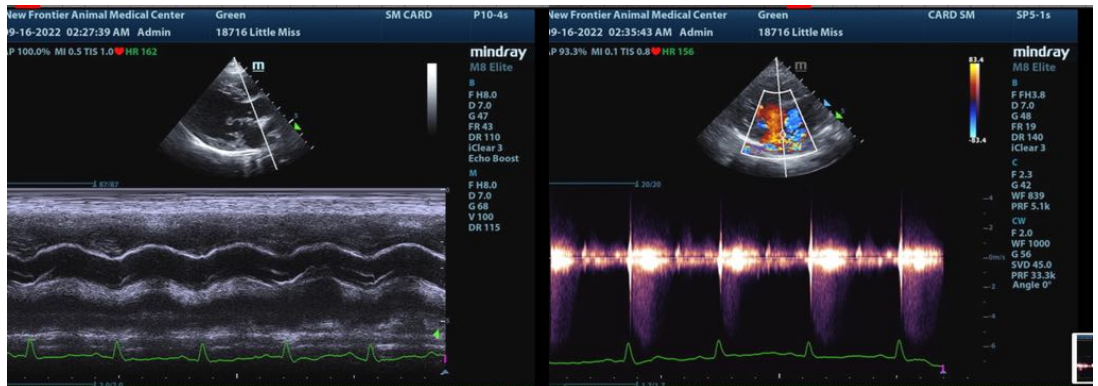
Dr. Gunther

**INVOICE**

32939

**DATE**

9/15/22





**PATIENT**

Little Miss Green

**SPECIES**

Canine

**BREED**

Poodle Cross

**SEX**

Spayed female

**AGE**

14 years

**WEIGHT**

8.8 lbs

**INTERPRETED BY**

Eric Lindquist, DMV  
DABVP, Cert. IVUSS

**IMAGING  
PERFORMED BY**

Dr. Gunther

**HOSPITAL NAME**

New Frontier AMC

**REFERRING VET**

Dr. Gunther

**INVOICE**

32939

**DATE**

9/15/22

**The information and recommendations provided are based on the images presented by the referring veterinarian/sonographer. No evaluation can be communicated regarding pathology that was not visible in the image/video clips provided.**

Thank you for this referral. If the clinical or image interpretation does not parallel your findings or if I can be of any further assistance please contact me.

**Eric Lindquist**, DMV, DABVP, Cert. IVUSS, CEO of SonoPath.com  
info@SonoPath.com