



PATIENT PRESENTING CLINICAL SIGNS

Ren Myers History: New murmur; VHS 11.7

SPECIES Lateral and VD radiographs were submitted from 9/10/21 and revealed minor chronic bronchial changes with slightly prominent cranial waste in the heart. No evidence of cardiac overload.

Canine

BREED ULTRASONOGRAPHIC EXAMINATION OF THE HEART

Pomeranian

SEX

Neutered male

AGE

7 years

WEIGHT

13 lbs

The echocardiogram in this patient demonstrated normal **left atrial** size based on 3 different LA measurement methods. Chamber volumes and echogenicity were normal. The cranial and caudal **mitral** valve leaflets presented vegetative thickening consistent with endocardiosis. Doppler indicated measurable insufficiency. The **left ventricle** presented thicknesses with linear contour and was not dilated nor restricted. The **myocardium** presented normal echogenicity without subjective evidence of significant fibrotic or ischemic disease. **Contractility** of the ventricular walls was adequate and in normal range for this patient evidenced by the fractional shortening measurement and subjective evaluation of the different regions of the myocardium. The **left ventricular outflow** tract demonstrated normal laminar flow and subjective structural integrity. The **right atrium** and auricle revealed normal size, structure and content. No evidence of masses was noted or chamber overload. Trivial **tricuspid** insufficiency was noted. The **right ventricle** was of normal size (1/3 diameter of LV), chordae structure, myocardial echogenicity and thickness. **Pulmonic** tract assessment revealed normal valve structure, laminar flow, and diameter (approx. 1:1 pa/ao ratio). No visible **pericardial** or free pleura fluid was noted. No echographically detectable evidence of infiltrative disease was visible. The cranial **mediastinum and pericardial regions** were free of masses in the visible window.

INTERPRETED BY

Eric Lindquist, DMV DABVP, Cert. IVUSS

IMAGING PERFORMED BY

Tasha

HOSPITAL NAME

Dillsburg VC

REFERRING VET

Dr. Jacobs

CANINE CARDIAC PARAMETERS	MR VMAX (m/s)	TR VMAX (m/s)	LA/AO (Boon method)	LA/AO (Heart Base; Swe)	FS (%)	EF (%)	EPSS (cm)
NORMAL PARAMETER	4.5-5.5	<2.7	1.3	<1.6	28-40	40-100	<0.6
PATIENT			1.15	1.3	50		0.1
CANINE CARDIAC PARAMETERS	HR (BPM)	AV VMAX (m/s)	PV MAX (m/s)	BODY WEIGHT (kg)	LA (2D short axis Base view) (cm)	LVIDd (Avg; 2D and m-mode short axis) (cm)	LVIDs (Avg; 2D and m-mode short axis) (cm)
NORMAL PARAMETER	50-100	0.7-1.7	0.7-1.6				
PATIENT				13 lbs	2.4 max	2.5	

INVOICE

91847

DATE

9/15/21

ULTRASONOGRAPHIC FINDINGS

Stage B1 valvular disease.



PATIENT

Ren Myers

INTERPRETATION OF THE FINDINGS & FURTHER RECOMMENDATIONS

There was no evidence of volume overload. No therapy is recommended. If any clinical respiratory signs are present they are not cardiogenic in nature.

SPECIES

Canine

BREED

Pomeranian

SEX

Neutered male

AGE

7 years

WEIGHT

13 lbs

INTERPRETED BY

Eric Lindquist, DMV
DABVP, Cert. IVUSS

IMAGING PERFORMED BY

Tasha

HOSPITAL NAME

Dillsburg VC

REFERRING VET

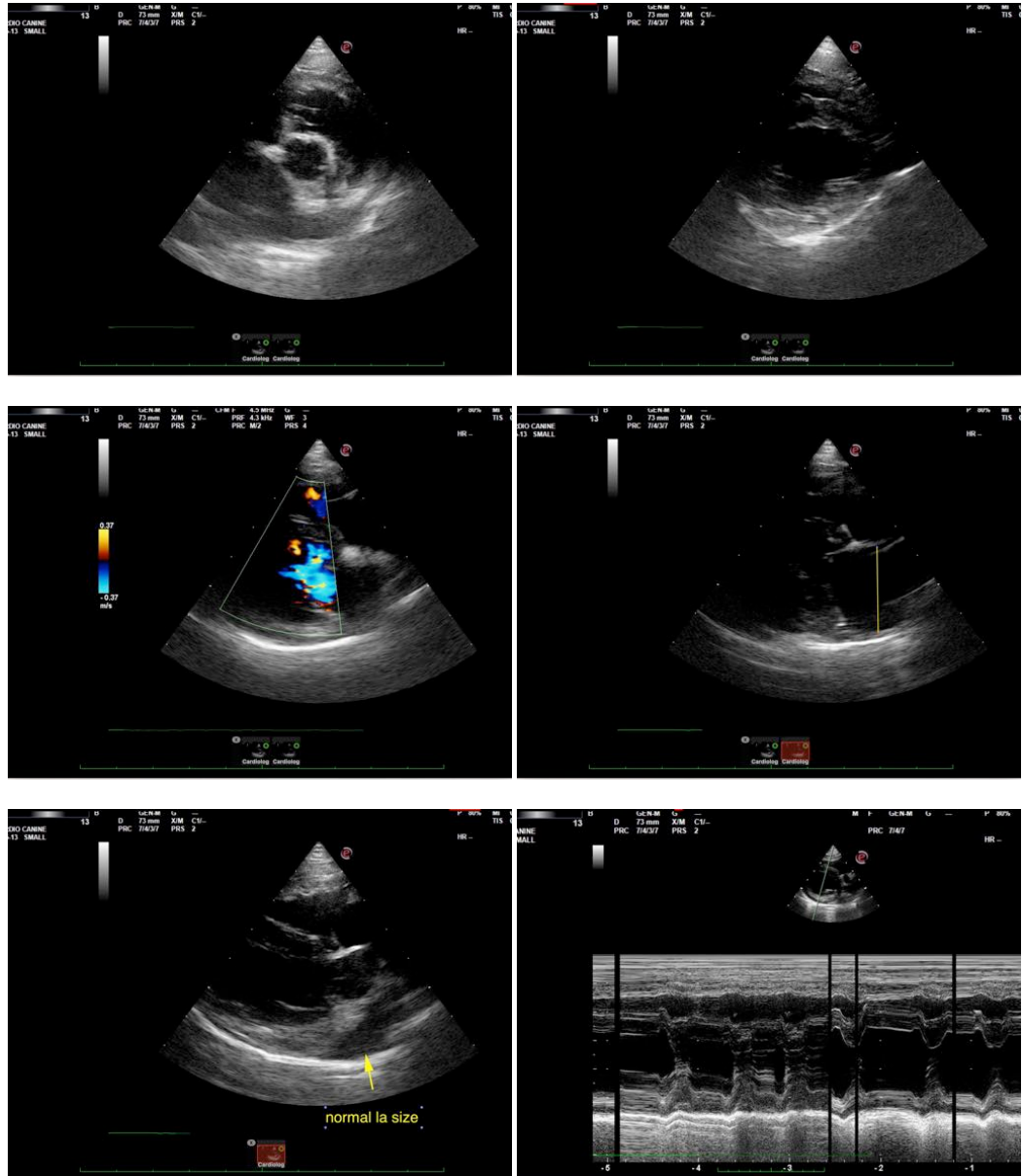
Dr. Jacobs

INVOICE

91847

DATE

9/15/21



The information and recommendations provided are based on the images presented by the referring veterinarian. No evaluation can be communicated regarding pathology that was not visible in the image/video clips provided.

Thank you for this referral. If the clinical or image interpretation does not parallel your findings or if I can be of any further assistance please contact me.

Eric Lindquist, DMV, DABVP, Cert. IVUSS, CEO of SonoPath.com



PATIENT info@SonoPath.com

Ren Myers

SPECIES

Canine

BREED

Pomeranian

SEX

Neutered male

AGE

7 years

WEIGHT

13 lbs

INTERPRETED BY

Eric Lindquist, DMV
DABVP, Cert. IVUSS

**IMAGING
PERFORMED BY**

Tasha

HOSPITAL NAME

Dillsburg VC

REFERRING VET

Dr. Jacobs

INVOICE

91847

DATE

9/15/21