



PATIENT

Tipsy Koebel

SPECIES

Feline

BREED

Domestic Shorthair

SEX

Neutered male

AGE

15 years

WEIGHT

14 lbs

INTERPRETED BY

Eric Lindquist, DMV
DABVP, Cert. IVUSS

IMAGING PERFORMED BY

Dr. Kitz

HOSPITAL NAME

Woodlands AH

PRESENTING CLINICAL SIGNS

History: Patient has history of elevated respiratory rate while resting at home per owner. He has been hyperthyroid for a while and is managed well with methimazole. I started Tipsy on Furosemide 12.5 mg - 1/2 tab BID - today -pending results of testing as he is currently stable but was afraid he could decompensate while waiting for reports....

Abnormal PE/Chem/CBC/UA Results: No murmur definitively ausculted on exam. Normal BP Elevated Cardiac BNP snap test Xrays show interstitial pattern with pleural effusion - xrays taken today with echo so specialist review pending ECG shows no obvious arrhythmia

ULTRASONOGRAPHIC EXAMINATION OF THE HEART

The echocardiogram in this patient revealed a hypokinetic left ventricular free wall with mild excessive left ventricular free wall thickening. The septum appeared normal in thickness. Right and left atrial enlargement was noted with mitral and tricuspid insufficiency. A trace amount of **pericardial and pleural** effusion was noted.

FELINE CARDIAC PARAMETERS	BODY WEIGHT (kg)	HR (BPM)	IVSd (cm)	LVIDd (cm)	LWVd (cm)	FS (%)	EF (%)
NORMAL PARAMETER	-----	150-240	0.3-0.6	1.0-2.1	0.25-0.6	35-67	80-100
PATIENT		230	0.49	1.43	0.76	52	
FELINE CARDIAC PARAMETERS	LA/AO (Boon)	LA/AO HEART BASE (Sisson)	LA 2D 4-chamber long axis AS to FW (Sisson) (cm)	LVOT VEL. (m/s)	RVOT VEL. (m/s)	IVRT (m/)	
NORMAL PARAMETER	<1.5	0.88-1.79	0.7-1.7	<1.6	<1.3	40-60	
PATIENT	2.3	2.8	2.27	-	0.85	NM	
Adapted from June Boon, Veterinary Echocardiography, 1998 Sisson D et al. JVIM 1991; 5: 232, Jacobs et al. Am J Vet Res 1985; 46:1705							

ULTRASONOGRAPHIC FINDINGS

Left-sided heart failure.

Unclassified cardiomyopathy.

REFERRING VET

Dr. Kitz

INVOICE

32916

DATE

9/14/22

INTERPRETATION OF THE FINDINGS & FURTHER RECOMMENDATIONS

Quadro therapy is warranted in this patient. I recommend continuation of Lasix at 6.25-12.5 mg b.i.d., ace inhibitor at 0.5 mg/kg s.i.d., off label Pimobendan at 0.3 mg/kg b.i.d. and Plavix therapy is all recommended. A recheck echocardiogram is recommended in 2-4 weeks depending upon clinical progression.



PATIENT

Tipsy Koebel

SPECIES

Feline

BREED

Domestic Shorthair

SEX

Neutered male

AGE

15 years

WEIGHT

14 lbs

INTERPRETED BY

Eric Lindquist, DMV
DABVP, Cert. IVUS

IMAGING PERFORMED BY

Dr. Kitz

HOSPITAL NAME

Woodlands AH

REFERRING VET

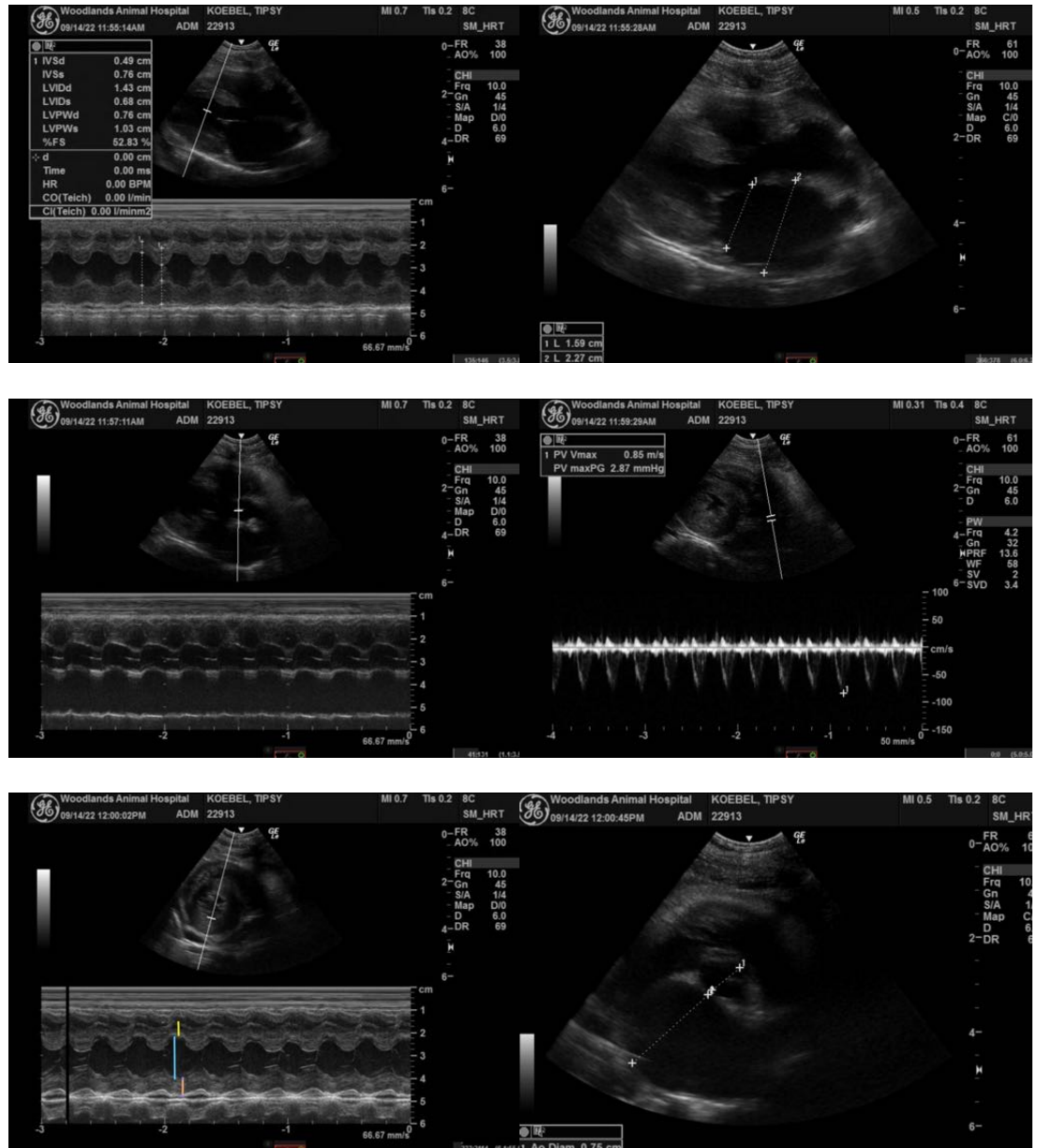
Dr. Kitz

INVOICE

32916

DATE

9/14/22



The information and recommendations provided are based on the images presented by the referring veterinarian/sonographer. No evaluation can be communicated regarding pathology that was not visible in the image/video clips provided.

Thank you for this referral. If the clinical or image interpretation does not parallel your findings or if I can be of any further assistance please contact me.



PATIENT

Tipsy Koebel

Eric Lindquist, DMV, DABVP, Cert. IVUSS, CEO of SonoPath.com
info@SonoPath.com

SPECIES

Feline

BREED

Domestic Shorthair

SEX

Neutered male

AGE

15 years

WEIGHT

14 lbs

INTERPRETED BY

Eric Lindquist, DMV
DABVP, Cert. IVUSS

**IMAGING
PERFORMED BY**

Dr. Kitz

HOSPITAL NAME

Woodlands AH

REFERRING VET

Dr. Kitz

INVOICE

32916

DATE

9/14/22