



PATIENT

Nala Braga

PRESENTING CLINICAL SIGNS

History: recheck from yesterday ate corn slices, seeing if needs surgery

SPECIES

Canine

ULTRASONOGRAPHIC EXAMINATION

Gastrointestinal

The upper **gastrointestinal tract** revealed persistent shadowing material. The structures had strong acoustic shadowing measuring up to 2.0 cm in the pyloric outflow. The small intestines and colon were unremarkable.

BREED

Mix

SEX

Spayed female

ULTRASONOGRAPHIC FINDINGS

Persistent gastric foreign bodies.

AGE

4 years

INTERPRETATION OF THE FINDINGS & FURTHER RECOMMENDATIONS

Gastrotomy, evacuation and GI biopsies are indicated to rule out underlying disease. Otherwise, unremarkable abdomen.

WEIGHT

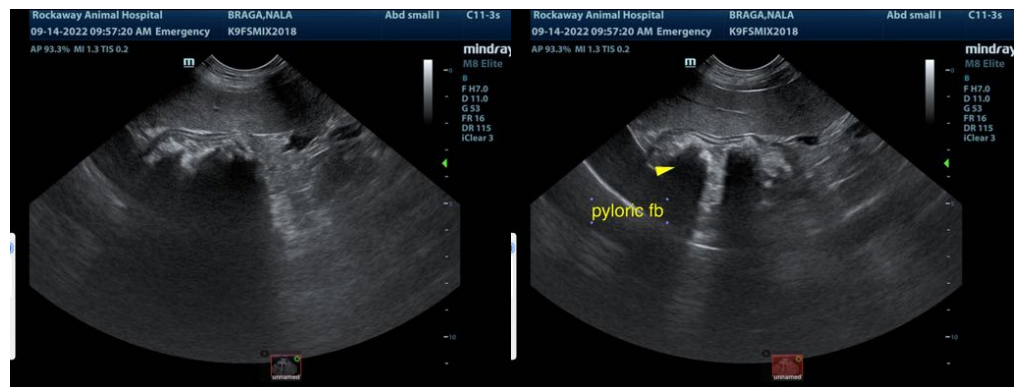
50 lbs

INTERPRETED BY

Eric Lindquist, DMV
DABVP, Cert. IVUSS

IMAGING PERFORMED BY

Jenn



HOSPITAL NAME

Rockaway AH

The information and recommendations provided are based on the images presented by the referring veterinarian/sonographer. No evaluation can be communicated regarding pathology that was not visible in the image/video clips provided.

REFERRING VET

Dr. Maniar

Thank you for this referral. If the clinical or image interpretation does not parallel your findings or if I can be of any further assistance please contact me.

INVOICE

32886

Eric Lindquist, DMV, DABVP, Cert. IVUSS, CEO of SonoPath.com
info@SonoPath.com

DATE

9/14/22