



**PATIENT**

Sasha Alexander

**PRESENTING CLINICAL SIGNS**

History: ALK doubled in the past year  
USG: 1.05, Ca Oxalates, Prot/creat ratio: 0.2, ALK: 534, GGT: 5

**SPECIES**

Canine

**ULTRASONOGRAPHIC EXAMINATION OF THE ABDOMEN**

**Urinary System**

**BREED**

Lhasa Apso Mix

The **urinary bladder**, trigone, and pelvic urethra presented normal thicknesses and normal tone. The pelvic urethra was imaged 3.0 cm beyond the cystourethral junction. The ureters were not visible which is normal. Sand accumulation and debris was noted with chronic cystitis pattern. There was a minimal amount of urine present at the time of the sonogram. No evidence of inflammatory or neoplastic changes was noted. Ureteral papillae were normal.

**SEX**

Spayed Female

**AGE**

12 ½ years

The **kidneys** revealed largely normal size and structure, corticomedullary definition and ratio (cortex 1/3 of medulla) were essentially maintained with some age-related loss of curvilinear patterns regarding the capsule and C/M junction. The cortices presented largely uniform texture with some increased echogenicity expected for this age patient. Medullary structure differed distinctly from that of the cortex and no evidence of pelvic dilation was present. Pinpoint mineralization was noted in the kidneys. The left kidney measured 4.77 cm. The right kidney measured 4.38 cm.

**WEIGHT**

18 lbs

**Adrenal Glands**

**INTERPRETED BY**

Eric Lindquist, DMV  
DABVP, Cert. IVUSS

Both **adrenal glands** were visualized and recognized as having largely normal shape, size, position and acceptable echogenicity for this age group and breed. Some heterogeneity was noted within the adrenal parenchyma without concerning capsular distortion. These changes are likely age related but should be monitored by sonogram should the patient be suspected of having adrenal disease. The left adrenal gland measured 1.71 x 0.71 cm. The right adrenal gland measured 1.8 x 0.61 cm.

**IMAGING PERFORMED BY**

Dr. Rodriguez

**Spleen**

**HOSPITAL NAME**

Foxfield

The **spleen** presented a smooth homogeneous parenchyma hyperechoic to liver and renal cortical parenchyma. The capsule was smooth without noticeable expansion or deviation from within the spleen or adjacent pathology. The splenic vasculature demonstrated normal volume without signs of congestion or thrombosis. No sonographic evidence of acute or chronic inflammatory, neoplastic, or infarctual changes was noted.

**REFERRING VET**

Dr. Rodriguez

**Liver**

**INVOICE**

91812

The **liver** images from right and left intercostal as well as subcostal views revealed subjectively normal liver size, contour, and structure. Some age-related parenchymal remodeling was noted but likely not clinically significant at this time. Vascular and biliary tracts were of normal volume and no evidence of congestion was noted. The gallbladder presented some dependent debris with essentially normal contour. The cystic and common bile ducts were normal. No overt evidence of active inflammatory, infiltrative or regenerative pathology was noted but should be paired with current or past LE elevations regarding any clinical significance to this presentation. The hepatic lymph nodes were unremarkable.

**DATE**

9/14/21



**PATIENT**

**Gastrointestinal**

Sasha Alexander

Examination of the **gastrointestinal tract** revealed a stomach and intestine free of stasis, of normal wall thickness, acceptable curvilinear mural detail, and peristaltic activity. Small and large intestine demonstrated normal luminal chyme and stool consistency respectively. No obstructive or overt infiltrative disease was noted. No associated abnormal lymphatic activity was noted.

**SPECIES**

Canine

**BREED**

Lhasa Apso Mix

**Pancreas**

The base and limbs of the **pancreas** were observed to be largely isoechoic to surrounding omental fat. Pancreatic duct and capsular contour were acceptably normal and parenchyma respected normal curvilinear patterns. No overt evidence of active inflammatory or neoplastic disease was noted.

**SEX**

Spayed Female

**ULTRASONOGRAPHIC FINDINGS**

**AGE**

12 ½ years

Bladder sand.

Renal calculi. Mild degenerative renal changes.

Structurally unremarkable adrenal glands. However, emerging PDH is a potential if clinical signs are present.

**WEIGHT**

18 lbs

Structurally unremarkable liver with largely expected changes for this age patient.

**INTERPRETED BY**

**INTERPRETATION OF THE FINDINGS & FURTHER RECOMMENDATIONS**

Eric Lindquist, DMV  
DABVP, Cert. IVUSS

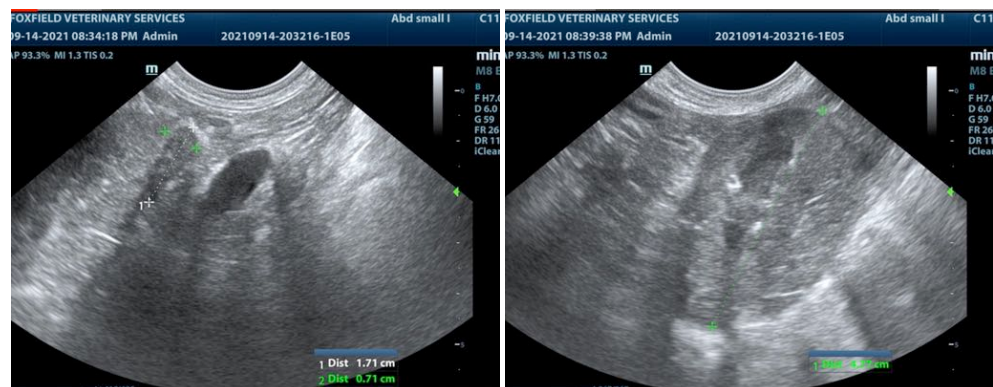
I recommend urinary work-up and medical management of the bladder presentation. However, the patient is likely passing calculi from the kidneys to the bladder. This may be playing a role in the hyposthenuria issue with underlying urinary tract infection and secondary washout. If Cushingoid parameters are persistently present then work-up for PDH is warranted even though structurally the adrenal glands appear normal, a small percentage of normal adrenal glands can be found in PDH patients.

**IMAGING PERFORMED BY**

Dr. Rodriguez

**HOSPITAL NAME**

Foxfield



**REFERRING VET**

Dr. Rodriguez

**INVOICE**

91812

**DATE**

9/14/21



**PATIENT**

Sasha Alexander

**SPECIES**

Canine

**BREED**

Lhasa Apso Mix

**SEX**

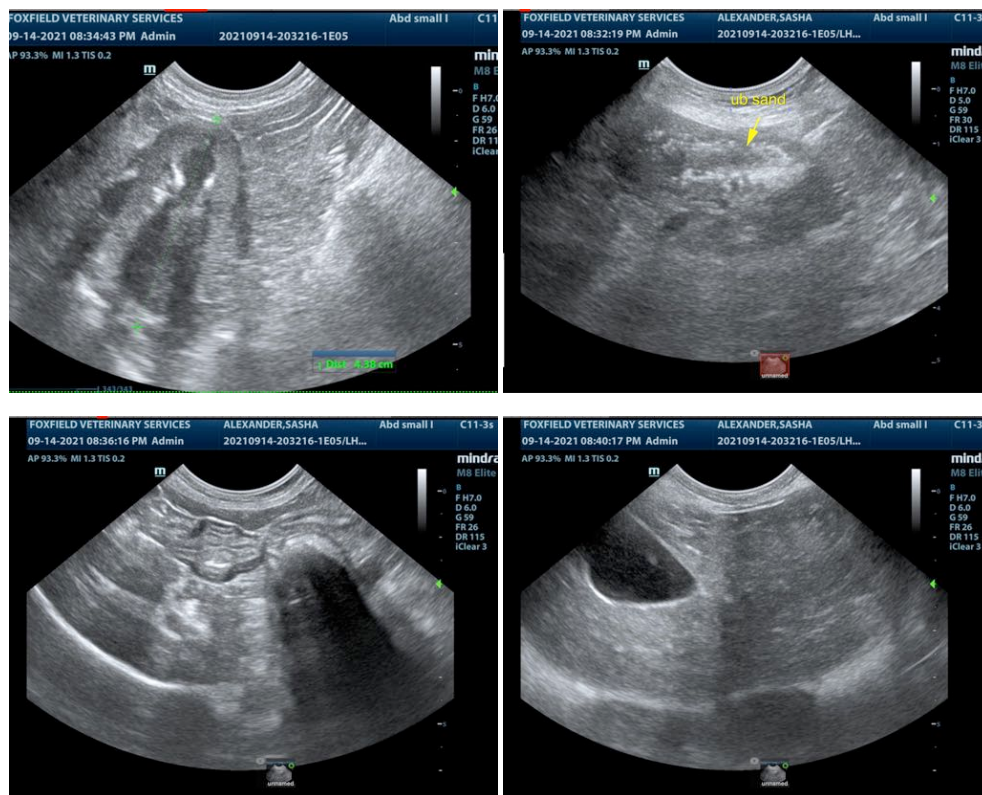
Spayed Female

**AGE**

12 ½ years

**WEIGHT**

18 lbs



**INTERPRETED BY**

Eric Lindquist, DMV  
DABVP, Cert. IVUSS

**IMAGING PERFORMED BY**

Dr. Rodriguez

**HOSPITAL NAME**

Foxfield

**REFERRING VET**

Dr. Rodriguez

**INVOICE**

91812

**DATE**

9/14/21

The information and recommendations provided are based on the images presented by the referring veterinarian. No evaluation can be communicated regarding pathology that was not visible in the image/video clips provided.

Thank you for this referral. If the clinical or image interpretation does not parallel your findings or if I can be of any further assistance please contact me.

Eric Lindquist, DMV, DABVP, Cert. IVUSS, CEO of SonoPath.com  
info@SonoPath.com