

**DATE**

9/14/21

PRESENTING CLINICAL SIGNS

Has bouts of inappetence (June 4th, July 17th and now). Lethargy.
Current Medications: Convenia on 9-10-21. Metronidazole
Lab Results: Nothing specific noted on bloodwork
Radiographs: Nothing specific noted on radiographs
Date of Previous IntraPet Ultrasound: No previous
Sedation: declined, not needed
Stat Report: not requested

PATIENT

Poe Genovese

SPECIES

Feline

BREED

Domestic Shorthair

SEX

Neutered male

AGE

2015

WEIGHT

10 lbs

INTERPRETED BYEric Lindquist, DMV
DABVP, Cert. IVUSS**HOSPITAL NAME**

Madonna VC

REFERRING VET

Dr. Brockett

INVOICE

91829

ULTRASONOGRAPHIC EXAMINATION OF THE ABDOMEN**Urinary System**

The **urinary bladder**, trigone, and pelvic urethra presented normal thicknesses and normal tone. The ureters were not visible which is normal. No uroliths or sediment were visualized and anechoic urine was present. No evidence of inflammatory or neoplastic changes was noted. Ureteral papillae were normal.

The **kidneys** revealed normal size and structure, corticomedullary definition and ratio for this age. The cortices presented largely uniform texture with normal echogenic relationship to liver and spleen. Medullary structure differed distinctly from the cortex and no evidence of pelvic dilation was present. The capsules were acceptably uniform without significant irregularities. The left kidney measured 3.63 cm. The right kidney measured 3.72 cm.

Adrenal Glands

Both **adrenal glands** were visualized and recognized as having normal shape, size, position and echogenicity for this breed. The phrenic vasculature, glandular echogenicity and detail were unremarkable. Capsule, cortex, and medullary definition were normal for this age patient.

Spleen

The **spleen** presented a smooth homogeneous parenchyma hyperechoic to liver and renal cortical parenchyma. The capsule was smooth without noticeable expansion or deviation from within the spleen or adjacent pathology. The splenic vasculature demonstrated normal volume without signs of congestion or thrombosis. No sonographic evidence of acute or chronic inflammatory, neoplastic, or infarctual changes was noted.

Liver

The **liver** images submitted revealed subjectively normal liver size, contour, and structure. Parenchymal echogenicity was naturally coarse and hypoechoic to the spleen. Vascular and biliary tracts were of normal volume with no evidence of congestion. The gallbladder presented acceptably thin walls with primarily anechoic content. The cystic and common bile ducts were normal. No pathological hepatic lymphadenopathy was evident. No overt structural evidence of inflammatory, infiltrative or regenerative pathology was evident.

Gastrointestinal

The **gastrointestinal** presentation revealed mild uniform prominence of the gastric mucosa as well as areas of "ropey" small intestinal wall. The muscularis layer was hypertrophied inverting the normal ratio (1:3). There were areas of inversion of the muscularis to mucosal ratio noted. The wall thickness measured up to 0.34 cm. The intestinal submucosa was slightly irregular, thickened and hyperechoic suggestive of low grade, chronic inflammation. Minor fluid filled cecum was noted. No evidence of obstruction was present. Chronic inflammatory bowel disease is probable with a low possibility of an early neoplastic event such as lymphoma or, less likely, dry form FIP can at times be found on biopsy of these presentations. Full thickness tissue biopsies via open laparotomy, ideally guided by intraoperative ultrasound in order to obtain the most representative mural sample, would be necessary to rule more significant disease than IBD.

Pancreas

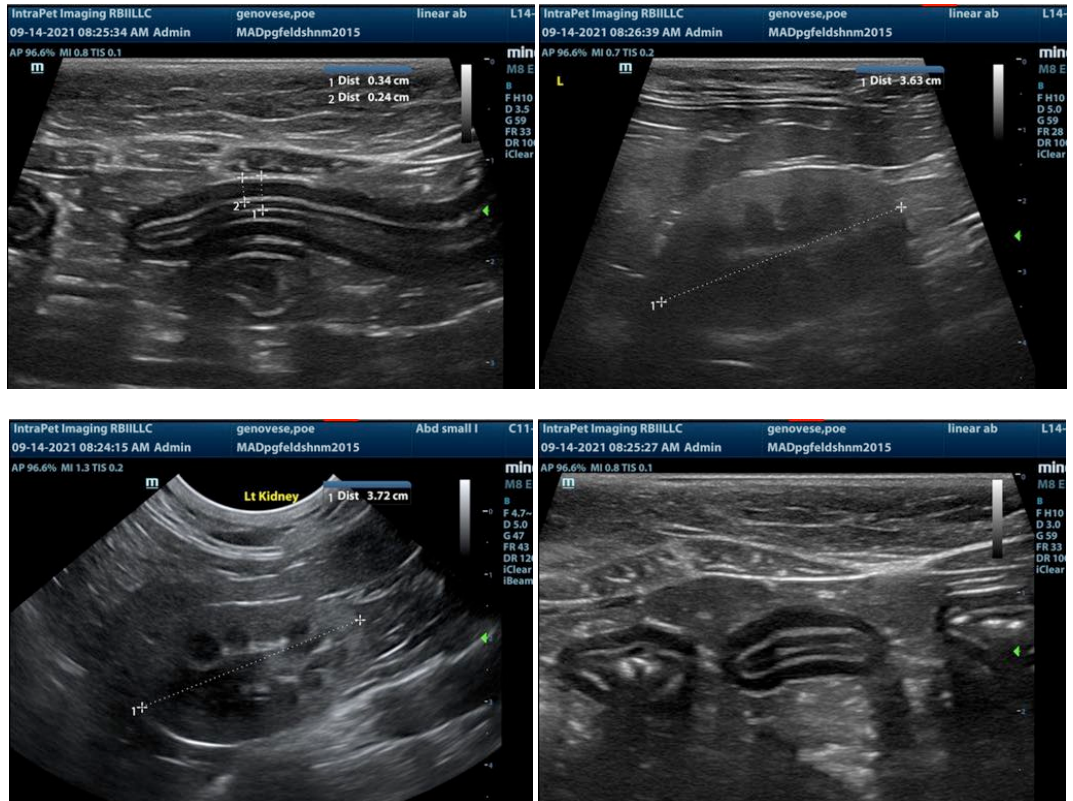
The base and limbs of the **pancreas** were observed to be largely isoechoic to surrounding omental fat. Pancreatic duct and capsular contour were acceptably normal and parenchyma respected normal curvilinear patterns. No overt evidence of active inflammatory or neoplastic disease was noted.

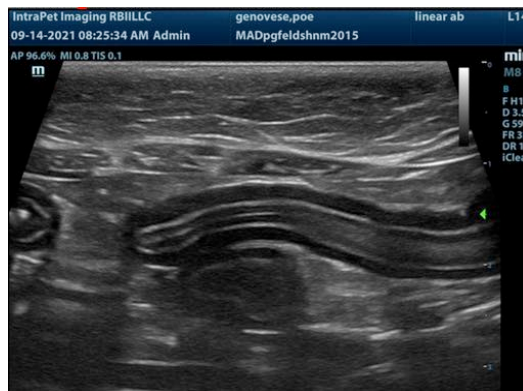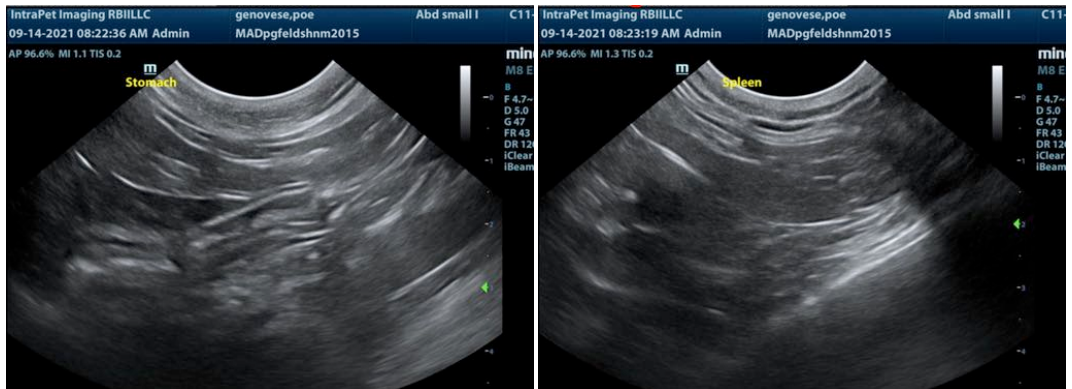
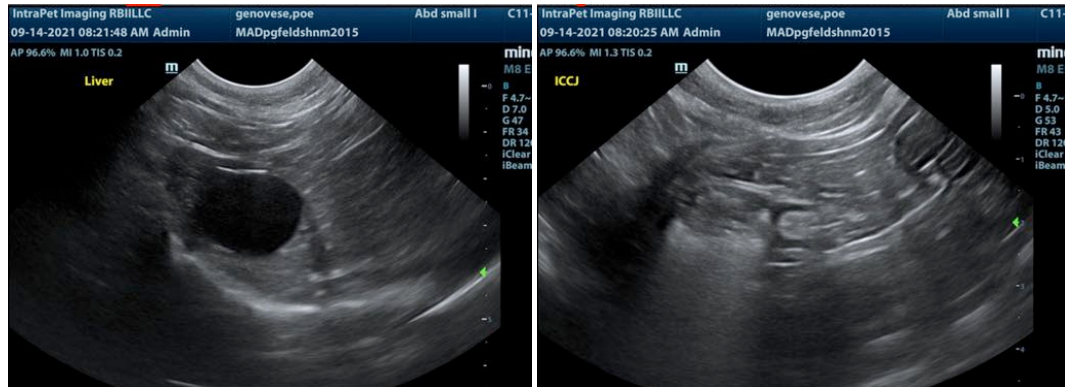
ULTRASONOGRAPHIC FINDINGS

Unremarkable abdomen except for diffuse intestinal thickening with hypertrophied muscularis.

INTERPRETATION OF THE FINDINGS & FURTHER RECOMMENDATIONS

Neoplastic criteria is not present; however, inflammatory bowel with muscularis hypertrophy is likely. Emerging round cell neoplasia cannot be entirely ruled out. Full thickness intestinal biopsies are necessary. There was no evidence of significant inflammatory disease noted. Other causes of inappetence such as orthopedic pain/spinal, CNS or thoracic disease should all be considered.





The information and recommendations provided are based on the images presented by the referring veterinarian. No evaluation can be communicated regarding pathology that was not visible in the image/video clips provided.

Thank you for this referral. If the clinical or image interpretation does not parallel your findings or if I can be

of any further assistance please contact me.

Eric Lindquist, DMV, DABVP, Cert. IVUSS, CEO of SonoPath.com
Eric.Lindquist@SonoPath.com