



PATIENT PRESENTING CLINICAL SIGNS

Matty Alimi History: Heart murmur III/VI. Asymptomatic
Abnormal PE/Chem/CBC/UA Results: WNL. Ty- 2.6

SPECIES

Feline

BREED

Domestic Shorthair

SEX

Neutered male

AGE

10 years

WEIGHT

14.9 lbs

INTERPRETED BY

Eric Lindquist, DMV
DABVP, Cert. IVUSS

IMAGING PERFORMED BY

Jessica Miller, RDMS

HOSPITAL NAME

Whippany VH

REFERRING VET

Dr. Smith

INVOICE

91818

DATE

9/14/21

ULTRASONOGRAPHIC EXAMINATION OF THE HEART

The echocardiogram in this patient demonstrated normal **left atrial** size based on 3 separate LA measurements. Trivial **mitral** valve insufficiency was noted. The **left ventricle** presented normal thicknesses with linear contour and was not dilated nor restricted. The **myocardium** presented normal echogenicity without subjective evidence of significant fibrotic or ischemic disease. **Contractility** of the ventricular walls was adequate and in normal range for this patient evidenced by the fractional shortening measurement and subjective evaluation of the different regions and angles of the myocardium. The **left ventricular outflow** tract demonstrated normal laminar flow and subjective structural integrity. The **right atrium** and auricle revealed normal size, structure and content. No evidence of masses was noted or chamber overload. **Tricuspid** insufficiency was noted. The **right ventricle** was of normal size (1/3 diameter of LV), chordae structure, myocardial echogenicity and thickness. **Pulmonic** tract assessment revealed normal valve structure, laminar flow, and diameter (approx. 1:1 pa/ao ratio). No visible **pericardial** or free pleura fluid was noted or extra cardiac pathology in the visible planes. The cranial **mediastinum and pericardial regions** were free of masses in the visible window.

FELINE CARDIAC PARAMETERS	BODY WEIGHT (kg)	HR (BPM)	IVSd (cm)	LVIDd (cm)	LVWd (cm)	FS (%)	EF (%)
NORMAL PARAMETER	-----	150-240	0.3-0.6	1.0-2.1	0.25-0.6	35-67	80-100
PATIENT		NM	0.5	1.2	0.5	35	
FELINE CARDIAC PARAMETERS	LA/AO (Boon)	LA/AO HEART BASE (Sisson)	LA 2D 4-chamber long axis AS to FW (Sisson) (cm)	LVOT VEL. (m/s)	RVOT VEL. (m/s)	IVRT (m/)	
NORMAL PARAMETER	<1.5	0.88-1.79	0.7-1.7	<1.6	<1.3	40-60	
PATIENT	1.2	1.2	1.3 max	1.0	0.54	NM	
Adapted from June Boon, Veterinary Echocardiography, 1998 Sisson D et al. JVIM 1991; 5: 232, Jacobs et al. Am J Vet Res 1985; 46:1705							

ULTRASONOGRAPHIC FINDINGS

Normal echocardiogram with trivial mitral and tricuspid insufficiency, not clinically significant.



PATIENT

Matty Alimi

INTERPRETATION OF THE FINDINGS & FURTHER RECOMMENDATIONS

There is no contraindication to anesthetic procedure if necessary in this patient.

SPECIES

Feline

BREED

Domestic Shorthair

SEX

Neutered male

AGE

10 years

WEIGHT

14.9 lbs

INTERPRETED BY

Eric Lindquist, DMV
DABVP, Cert. IVUSS

IMAGING PERFORMED BY

Jessica Miller, RDMS

HOSPITAL NAME

Whippany VH

REFERRING VET

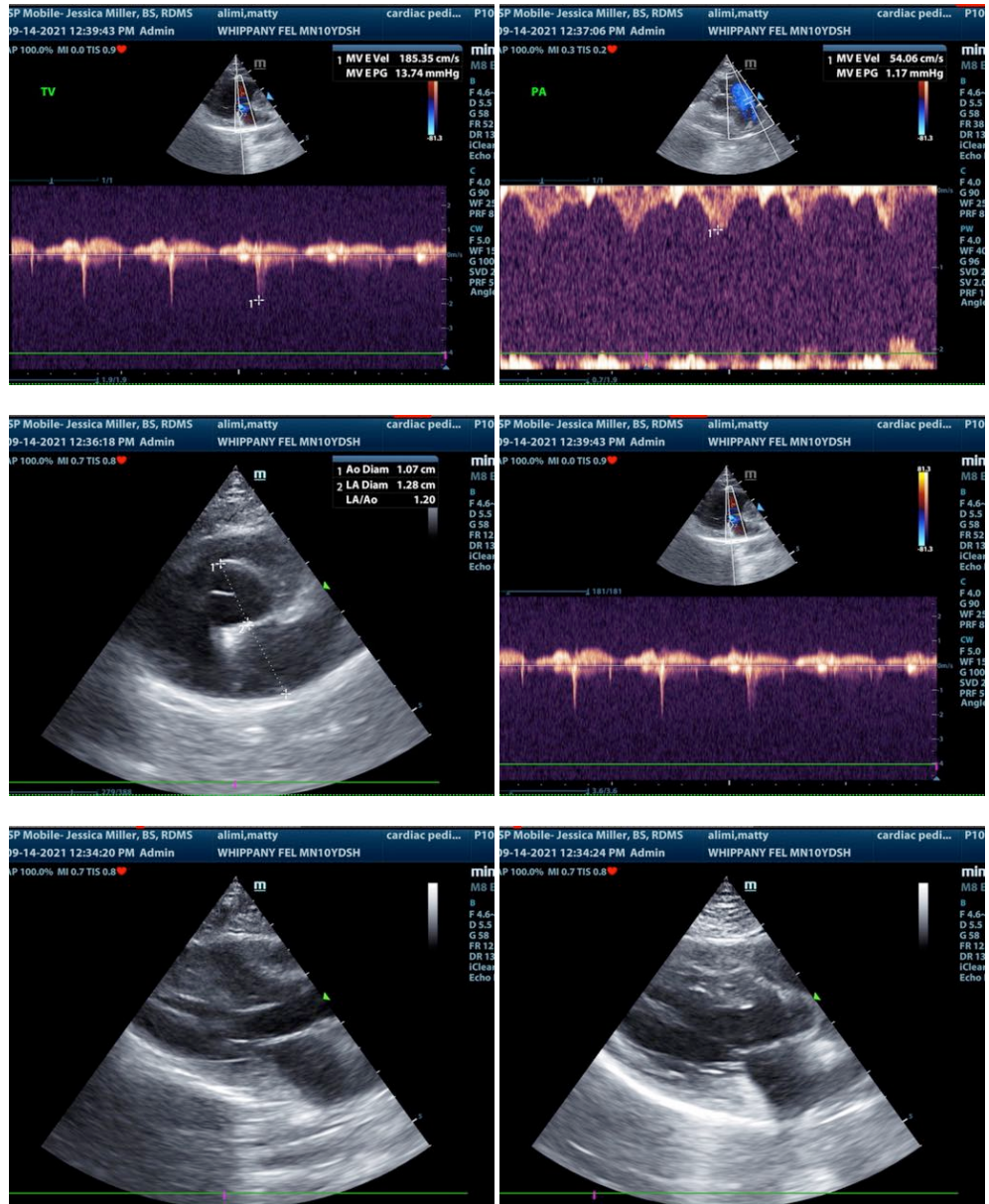
Dr. Smith

INVOICE

91818

DATE

9/14/21





PATIENT

Matty Alimi

SPECIES

Feline

BREED

Domestic Shorthair

SEX

Neutered male

AGE

10 years

WEIGHT

14.9 lbs

INTERPRETED BY

Eric Lindquist, DMV
DABVP, Cert. IVUSS

**IMAGING
PERFORMED BY**

Jessica Miller, RDMS

HOSPITAL NAME

Whippany VH

REFERRING VET

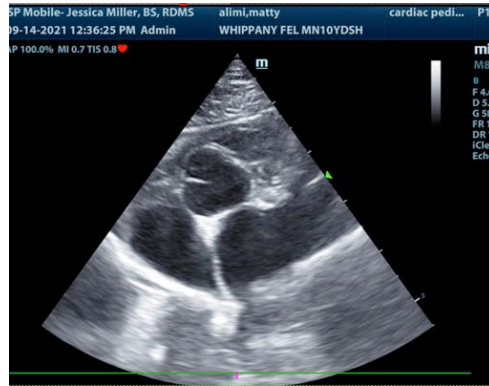
Dr. Smith

INVOICE

91818

DATE

9/14/21



The information and recommendations provided are based on the images presented by the referring veterinarian. No evaluation can be communicated regarding pathology that was not visible in the image/video clips provided.

Thank you for this referral. If the clinical or image interpretation does not parallel your findings or if I can be of any further assistance please contact me.

Eric Lindquist, DMV, DABVP, Cert. IVUSS, CEO of SonoPath.com
info@SonoPath.com