



**PATIENT**

Leela Kendall

**SPECIES**

Canine

**BREED**

Pembroke Welsh Corgi

**SEX**

Spayed Female

**AGE**

13 years

**WEIGHT**

13.1 kg

**INTERPRETED BY**

Eric Lindquist, DMV  
DABVP, Cert. IVUSS

**IMAGING PERFORMED BY**

Dr. Biederbeck

**HOSPITAL NAME**

Lomsnes VH

**REFERRING VET**

Dr. Biederbeck

**INVOICE**

91827

**DATE**

9/14/21

**PRESENTING CLINICAL SIGNS**

History: Acute collapse, fever, severe diarrhea with blood, markedly dehydrated. Had a great day yesterday, lots of energy. Fever went down after IV amp and metro this morning but non responsive, very pale and listless. Suspect renal elevations secondary to hyper filtration effect from mass  
Abnormal PE/Chem/CBC/UA Results: CBC: nsf- Hct 46.6% due to dehydration concern she is actually anemic CHEM:Mildly Elevated: SDMA 15 (N: 0-14), BUN 30 (N: 7-27), Creat 1.5 (normal but has poor muscle mass) Globulins 4.6 (N:2.5-4.5) ELEC: wnl T4: wnl Urinalysis: nsf SG 1.026 Chemstrip: 4+ protein Opted to run UPC due to inactive sediment UCRE: 96 mg/dL UPRO: >400mg/dL UPC: > 4.15

**ULTRASONOGRAPHIC EXAMINATION OF THE ABDOMEN**

**Urinary System**

The **urinary bladder**, trigone, and pelvic urethra presented normal thicknesses and normal tone. The pelvic urethra was imaged 2.0 cm beyond the cystourethral junction. The ureters were not visible which is normal. No uroliths or sediment were visualized and anechoic urine was present. No evidence of inflammatory or neoplastic changes was noted. Ureteral papillae were normal.

The **kidneys** revealed normal size and structure, corticomedullary definition and ratio for this age. The cortices presented largely uniform texture with normal echogenic relationship to liver and spleen. Medullary structure differed distinctly from the cortex. The capsules were acceptably uniform without significant irregularities. Slight pyelectasia was noted in the right kidney.

**Adrenal Glands**

Both **adrenal glands** were visualized and recognized as having normal shape, size, position and echogenicity for this breed. The phrenic vasculature, glandular echogenicity and detail were unremarkable. Capsule, cortex, and medullary definition were normal for this age patient. The right adrenal gland measured 0.6 cm. The left adrenal gland measured 0.6 cm.

**Spleen**

The **spleen** presented a smooth homogeneous parenchyma hyperechoic to liver and renal cortical parenchyma. The capsule was smooth without noticeable expansion or deviation from within the spleen or adjacent pathology. The splenic vasculature demonstrated normal volume without signs of congestion or thrombosis. No sonographic evidence of acute or chronic inflammatory, neoplastic, or infarctual changes was noted.

**Liver**

The **liver** was uniformly enlarged with minor swelling. Slight irregular contour was noted. The gallbladder presented acceptably thin walls with primarily anechoic content. The cystic and common bile ducts were normal. No pathological hepatic lymphadenopathy was evident.



**PATIENT**

**Gastrointestinal**

Leela Kendall

The **stomach** revealed slightly edematous wall with minor retention of ingesta/chyme. Small and large intestine demonstrated normal luminal chyme and stool consistency respectively. The colon was empty with minor mural thickening.

**SPECIES**

Canine

**Pancreas**

**BREED**

The visible **pancreas** was unremarkable. I cannot completely rule out that the cystic structures are not deriving from the pancreas. The pancreas was otherwise unremarkable.

Pembroke Welsh Corgi

**SEX**

**Free Abdomen**

Spayed Female

The midabdomen revealed a multi-focal cystic lymph node that measured up to 3.0 cm in length. This is likely owing to chronic lymphadenitis. Ultrasound-guided drainage, culture and cytology would be appropriate. This is likely non-neoplastic.

**AGE**

13 years

**ULTRASONOGRAPHIC FINDINGS**

**WEIGHT**

13.1 kg

Possible gastritis.

Cystic lymph nodes. Likely non-neoplastic, but may be harboring infection.

Minor hepatic swelling.

**INTERPRETED BY**

Geriatric abdomen.

Eric Lindquist, DMV  
DABVP, Cert. IVUSS

**INTERPRETATION OF THE FINDINGS & FURTHER RECOMMENDATIONS**

**IMAGING PERFORMED BY**

Ultrasound-guided FNA of the liver is warranted along with the cystic lymph node sampling with drainage and cytology is indicated. The cause of collapse is not evident in this patient. Cardiac evaluation would be appropriate as well as assessment for any arrhythmogenic disease, CNS disease or orthopedic disease.

Dr. Biederbeck

**HOSPITAL NAME**

Lomsnes VH

**REFERRING VET**

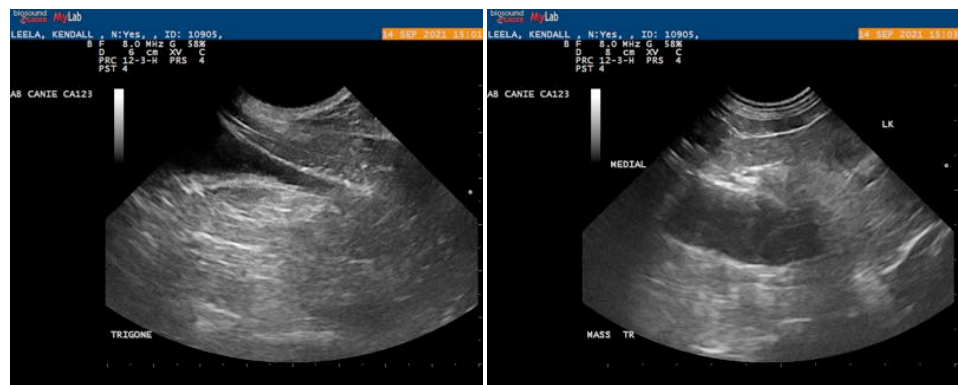
Dr. Biederbeck

**INVOICE**

91827

**DATE**

9/14/21





**PATIENT**

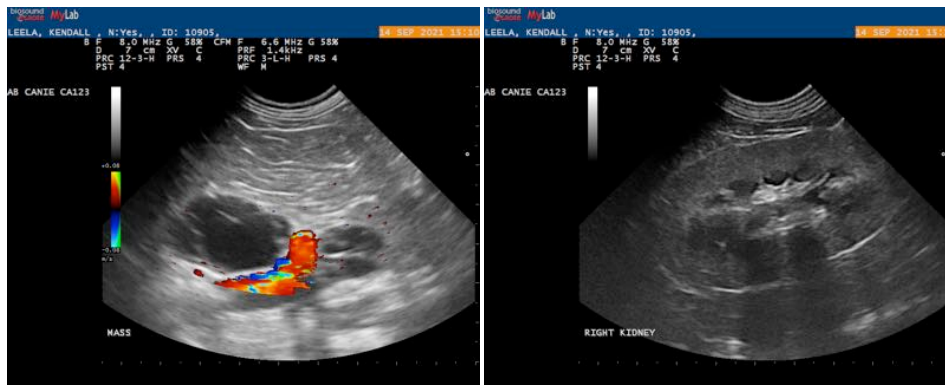
Leela Kendall

**SPECIES**

Canine

**BREED**

Pembroke Welsh Corgi



**SEX**

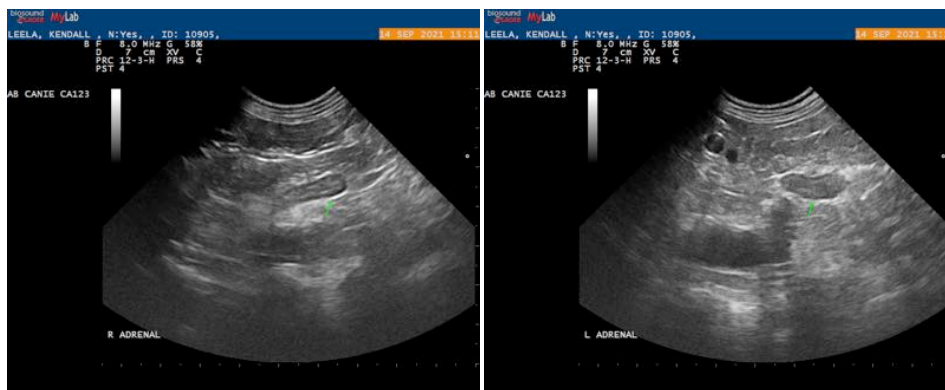
Spayed Female

**AGE**

13 years

**WEIGHT**

13.1 kg



**INTERPRETED BY**

Eric Lindquist, DMV  
DABVP, Cert. IVUSS

**IMAGING PERFORMED BY**

Dr. Biederbeck

**HOSPITAL NAME**

Lomsnes VH


**REFERRING VET**

Dr. Biederbeck

The information and recommendations provided are based on the images presented by the referring veterinarian. No evaluation can be communicated regarding pathology that was not visible in the image/video clips provided.

Thank you for this referral. If the clinical or image interpretation does not parallel your findings or if I can be of any further assistance please contact me.

Eric Lindquist, DMV, DABVP, Cert. IVUSS, CEO of SonoPath.com  
info@SonoPath.com



The following is an applicable excerpt from the *Curbside Guide to Diagnosis & Treatment of Sonographic Disease* offered by [SonoPath.com](http://sonopath.com) Lindquist, Frank, Lobetti, and Modler.

An essential quick guide for every general practitioner and sonographer.

<https://sonopath.com/products/curbside-guide-editing-due-release-12012015>

**INVOICE**

91827

**DATE**

9/14/21

Fever of Unknown Origin

<http://www.sonopath.com/FUO>



**PATIENT**

Leela Kendall

**SPECIES**

Canine

**BREED**

Pembroke Welsh Corgi

**SEX**

Spayed Female

**AGE**

13 years

**WEIGHT**

13.1 kg

**INTERPRETED BY**

Eric Lindquist, DMV  
DABVP, Cert. IVUSS

**IMAGING PERFORMED BY**

Dr. Biederbeck

**HOSPITAL NAME**

Lomsnes VH

**REFERRING VET**

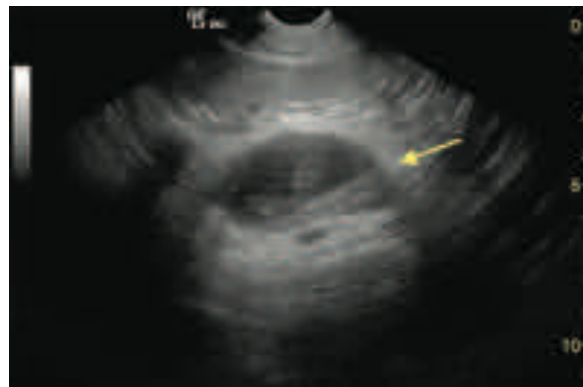Dr. Biederbeck

**INVOICE**

91827

**DATE**

9/14/21



Long axis of the mid-abdomen in a dog with an omental abscess after foreign body penetration from the gastrointestinal tract. The hypoechoic necrotic center of the lesion is surrounded by a thick echogenic capsule and hyperechoic mesenteric fat (arrow) indicating focal peritonitis. The linear echogenic needle (5 cm depth) is barely visible owing to the density of the purulent material contained within the abscess.

Description: The definition of a fever of unknown origin (FUO) has not been clearly defined for animals. Currently, it is either understood to be a fever that does not resolve within the period one would expect for a “self-limiting infection” being treated with appropriate antimicrobial therapy, or that for which an underlying diagnosis has not been determined despite considerable diagnostic effort. The common causes of FUO were summarized concisely in a presentation at the American College of Veterinary Internal Medicine 2004 Forum. The presenters synthesized information from three veterinary papers on the subject, which suggested the following:

Final Diagnosis	Bennett (dogs & cats)	Dunn and Dunn (dogs only)	Lunn (dogs & one cat)	Total	Percent
Infection	21	16	10	47	28
Immune	18	22	6	46	27
Bone marrow disease	4	22	2	28	16
Neoplasia (outside marrow)	0	10	2	12	7
Miscellaneous	2	12	2	16	9
No diagnosis	0	19	2	21	12
<b>TOTALS</b>	<b>45</b>	<b>101</b>	<b>24</b>	<b>170</b>	<b>99</b>



**PATIENT**

Leela Kendall

**SPECIES**

Canine

**BREED**

Pembroke Welsh Corgi

**SEX**

Spayed Female

**AGE**

13 years

**WEIGHT**

13.1 kg

**INTERPRETED BY**

Eric Lindquist, DMV  
DABVP, Cert. IVUSS

**IMAGING PERFORMED BY**

Dr. Biederbeck

**HOSPITAL NAME**

Lomsnes VH

**REFERRING VET**

Dr. Biederbeck

**INVOICE**

91827

**DATE**

9/14/21

The types of infection diagnosed in this case series were varied, ranging from discospondylitis (8 cases), blastomycosis (6), and bacterial endocarditis (4), to leishmaniasis (1), prostatitis (1), and *Ehrlichia canis* infection (1); a multitude of other infectious causes also fell within the spectrum. Of the cases in which immune-mediated disease was found, 44% had immune-mediated polyarthritis. Bone marrow diseases included myeloproliferative disease, myelodysplasia (8), lymphocytic leukemia (8), myeloma (3), chronic granulocytic leukemia (3), lymphoblastic leukemia, and malignant histiocytosis. The types of neoplasia located outside the bone marrow included lymphoma (6), metastatic disease (2), and neoplasms of the lung, spleen, and stomach. Finally, miscellaneous diseases included hypertrophic osteodystrophy (6), meningitis (3), portosystemic shunt (3), lymphadenitis (2), panosteitis, and intervertebral disc disease. Overall, the most common causes across all cases were polyarthritis (44), lymphoid neoplasia (15), discospondylitis (8), myelodysplasia (8), hypertrophic osteodystrophy (6), and blastomycosis (6).

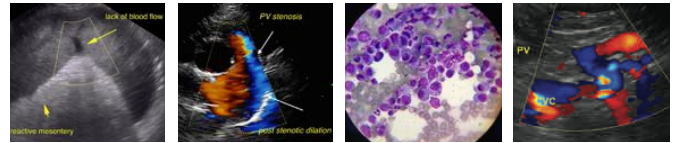
**Clinical Signs:** Animals usually present with either persistent or waxing and waning fevers ranging from 103°F to 106°F. Other clinical signs depend on the underlying cause of the fever. Careful and thorough physical examination is required to assess potential causes.

**Diagnostics:** FUO etiologies are partly related to geography, and thus locale or travel history should factor into a practitioner's diagnostic approach. A patient's lifestyle may also provide clues regarding exposure to certain etiologic agents. Therefore, conducting a thorough history can unveil important pieces of the diagnostic puzzle. Physical examination is especially important and should include an inspection of all accessible lymph nodes, palpation and movement of the joints, a fundic examination, a neurological evaluation, spinal and limb palpation and range of motion tests, and a rectal examination.

A minimum database should include a CBC reviewed by a clinical pathologist, as well as a biochemical profile and urinalysis. Retroviral testing should also be considered in cats. In areas where tick-borne disease is prevalent, in-house testing should be performed early. Advanced laboratory work can include: urine culture, blood culture, and infectious disease panels (PCR and/or serology). In dogs, one may screen for the following infectious agents: *Ehrlichia* spp., *Borrelia burgdorferi*, Rock Mountain Spotted Fever, *Bartonella* spp. (culture and PCR), and *Leptospira* spp. in cases of hepatic or renal involvement. In cats, one should evaluate for FeLV, FIV, feline infectious peritonitis (FIP) virus, toxoplasmosis, *Hemoplasma* spp. (*Mycoplasma*), and *Bartonella* spp. (culture and PCR). Testing for *Ehrlichia* spp., *Rickettsia* spp., and *Anaplasma phagocytophilum* can also be considered. A fungal assay is indicated if the patient lives in or has had exposure to a region with a higher incidence of fungal disease. Other infectious disease tests may be performed depending on the geographical location of the pet. Screening for *Brucella* should be done in breeding dogs. Immune-mediated disease screening can include a Coomb's test, a slide agglutination test (if the patient is anemic), and an antinuclear antibody (ANA) test. Immune disease is often a diagnosis of exclusion.

Imaging should include thoracic radiographs, abdominal ultrasound, and/or abdominal radiographs. Ultrasound can be very useful for assessing evidence of cholangiohepatitis, pyelonephritis, chronic urinary tract infection, abscess formation, peritonitis, and neoplasia; it also permits an examination of the intra-abdominal lymph nodes. An echocardiogram can offer assessment for vegetative endocarditis, whereas spinal radiographs offer assessment for discospondylitis. In cases where all other testing has proven negative and the patient has not responded to broad-spectrum antibiotics and supportive care, arthrocentesis should be considered to evaluate for septic joint disease, immune-mediated polyarthritis, and infectious disease. Finally, one can consider assessing the cerebrospinal fluid for meningoencephalitis, GME, and meningitis/arteritis. A bone marrow exam should be performed if blood dyscrasias are noted on the CBC.

**Treatment:** Treatment of the fever depends entirely on the underlying cause. Ideally, a thorough diagnostic plan will yield a diagnosis that will guide the appropriate therapeutic course. However, if an exhaustive approach has not produced a definitive diagnosis and there is no response to broad-spectrum antibiotics, trial therapy with immunosuppressive agents such as prednisolone can be considered to treat presumed immune-mediated diseases. Given the potential for negative sequelae



**PATIENT**

Leela Kendall

should an underlying infection be present, one must be certain that the investigation is thorough and monitor the patient's response carefully.

**SPECIES**

Canine

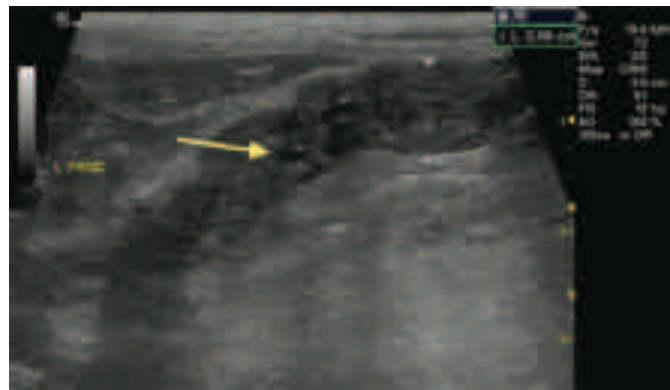
Conclusion: If a documented fever has not responded to antibiotics, antipyretics, or general nursing care, it is important to obtain a diagnosis to guide more specific treatment. A systematic physical examination and thorough history-taking will help inform further diagnostics in addition to what is revealed by the minimum database.

**BREED**

Pembroke Welsh Corgi

**SEX**

Spayed Female



Long axis of the left pancreatic limb (between calipers) in a cat with pancreatitis after undergoing a renal transplant. Note the decrease in echogenicity and mild loss of regular echotexture of the swollen and irregularly contoured pancreas. Also note the mild dilation of the pancreatic duct (arrow). Focal peritonitis is evident by increased echogenicity and loss of the linear echotexture of the surrounding mesentery.

**AGE**

13 years

**WEIGHT**

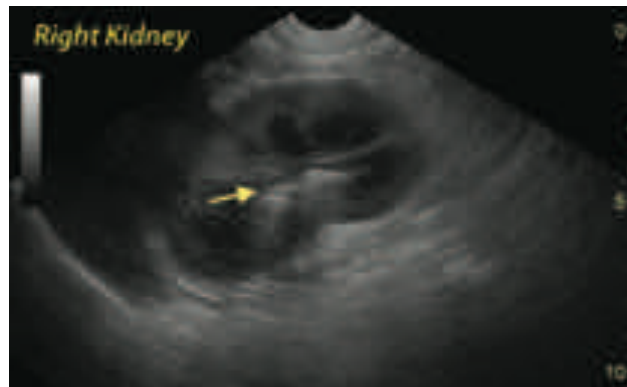13.1 kg

**INTERPRETED BY**

Eric Lindquist, DMV  
DABVP, Cert. IVUSS

**IMAGING PERFORMED BY**

Dr. Biederbeck



Long axis of the right kidney in a dog with pyelonephritis. Note the increased echogenicity and irregular outline of the renal crest and diverticuli and the mild dilation of the renal pelvis (arrow).

**HOSPITAL NAME**

Lomsnes VH

**REFERRING VET**

Dr. Biederbeck

**INVOICE**

91827

**DATE**

9/14/21



**PATIENT**

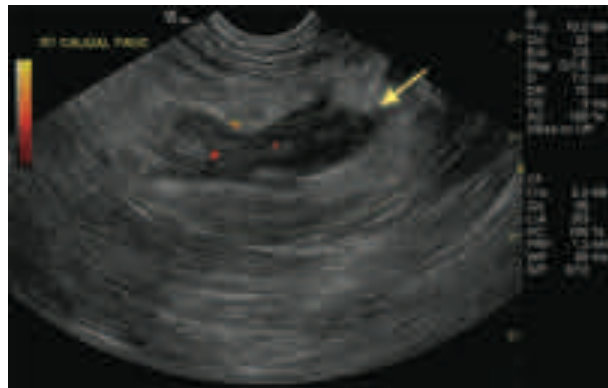Leela Kendall

**SPECIES**

Canine

**BREED**

Pembroke Welsh Corgi



Long axis of the right pancreatic limb in a dog with acute pancreatitis. The swollen hypoechoic pancreas is embedded in hyperechoic mesenteric fat (arrow). Note the regional differences in blood flow intensity within the parenchyma as demonstrated by Power Doppler interrogation compatible with multifocal disruption of vascularization as a sequela of the severe inflammation.

**SEX**

Spayed Female

**AGE**

13 years

**WEIGHT**

13.1 kg

**INTERPRETED BY**

Eric Lindquist, DMV  
DABVP, Cert. IVUSS

**IMAGING PERFORMED BY**

Dr. Biederbeck

**HOSPITAL NAME**

Lomsnes VH

**REFERRING VET**

Dr. Biederbeck

**INVOICE**

91827

**DATE**

9/14/21

References:

Bennet D. Diagnosis of pyrexia of unknown origin. *In Practice* 1995;17(10):470-81.

Dunn KJ, Dunn JK. Diagnostic investigations in 101 dogs with pyrexia of unknown origin. *J Sm Anim Pract* 1998;39(12):574-80.

Flood J. The diagnostic approach to fever of unknown origin in cats. *Compend Contin Educ Vet* 2009;31(1):26-31.

Flood J. The diagnostic approach to fever of unknown origin in dogs. *Compend Contin Educ Vet* 2009;31(1):14-21.

Lappin MR. The role of blood borne pathogens in feline fever of unknown origin. Proceedings from the American College of Veterinary Internal Medicine, Denver, CO, June 15-18, 2011.

Lunn KF. Fever of unknown origin: a systematic approach to diagnosis. *Compend Contin Educ Vet* 2001;23(11):976-92.

Lunn KF. Fever of unknown origin: appropriate choice of diagnostic tests. Proceedings from the American College of Veterinary Internal Medicine, Minneapolis, MN, June 9-12, 2004.