



**PATIENT**

Darby Keating

**SPECIES**

Canine

**BREED**

Cavalier King Charles  
Spaniel

**SEX**

Spayed Female

**AGE**

13 years

**WEIGHT**

23.6 lbs

**INTERPRETED BY**

Eric Lindquist, DMV  
DABVP, Cert. IVUSS

**IMAGING  
PERFORMED BY**

Jessica Miller, RDMS

**HOSPITAL NAME**

Whippany VH

**REFERRING VET**

Dr. Smith

**INVOICE**

91817

**DATE**

9/14/21

**PRESENTING CLINICAL SIGNS**

History: Cough, enlarged heart on radiographs. Current meds: Pimobendan 3mg BID  
Alk Phos 728, Chol 338, PSL 224, SDMA 16, Ty 1.9, p/f decreased (may be normal for her breed) UA:  
protein 2+, WBC 2-3 SG: 1.026

**ULTRASONOGRAPHIC EXAMINATION OF THE ABDOMEN**

**Urinary System**

The **urinary bladder**, trigone, and pelvic urethra presented normal thicknesses and normal tone. The ureters were not visible which is normal. No uroliths or sediment were visualized and anechoic urine was present. No evidence of inflammatory or neoplastic changes was noted. Ureteral papillae were normal.

The **kidneys** revealed largely normal size and structure, corticomedullary definition and ratio (cortex 1/3 of medulla) were essentially maintained with some age-related loss of curvilinear patterns regarding the capsule and C/M junction. The cortices presented largely uniform texture with some increased echogenicity expected for this age patient. Medullary structure differed distinctly from that of the cortex and no evidence of pelvic dilation was present. The left kidney measured 5.5 cm.

**Adrenal Glands**

Both **adrenal glands** were visualized and recognized as having normal shape, size, position and echogenicity for this breed. The phrenic vasculature, glandular echogenicity and detail were unremarkable. Capsule, cortex, and medullary definition were normal for this age patient. The left adrenal gland measured 1.22 x 0.48 cm at the caudal pole and 0.44 cm at the cranial pole.

**Spleen**

The **spleen** presented a smooth homogeneous parenchyma hyperechoic to liver and renal cortical parenchyma. The capsule was smooth without noticeable expansion or deviation from within the spleen or adjacent pathology. The splenic vasculature demonstrated normal volume without signs of congestion or thrombosis. No sonographic evidence of acute or chronic inflammatory, neoplastic, or infarctual changes was noted.

**Liver**

The **liver** images from right and left intercostal as well as subcostal views revealed subjectively normal liver size, contour, and structure. Some age-related parenchymal remodeling was noted but likely not clinically significant at this time. Vascular and biliary tracts were of normal volume and no evidence of congestion was noted. The gallbladder presented some dependent debris with essentially normal contour. The cystic and common bile ducts were normal. No overt evidence of active inflammatory, infiltrative or regenerative pathology was noted but should be paired with current or past LE elevations regarding any clinical significance to this presentation. The hepatic lymph nodes were unremarkable.



**PATIENT**

**Gastrointestinal**

Darby Keating

Examination of the **gastrointestinal tract** revealed a stomach and intestine free of stasis, of normal wall thickness, acceptable curvilinear mural detail, and peristaltic activity. Transit of ingesta was noted in this patient. However, structurally the gastrointestinal tract was unremarkable and this is most consistent with post prandial presentation. Small and large intestine demonstrated normal luminal chyme and stool consistency respectively. No obstructive or overt infiltrative disease was noted. No associated abnormal lymphatic activity was noted.

**SPECIES**

Canine

**BREED**

**Pancreas**

Cavalier King Charles  
Spaniel

The base and limbs of the **pancreas** were observed to be largely isoechoic to surrounding omental fat. Pancreatic duct and capsular contour were acceptably normal and parenchyma respected normal curvilinear patterns. No overt evidence of active inflammatory or neoplastic disease was noted.

**SEX**

Spayed Female

**AGE**

13 years

**ULTRASONOGRAPHIC EXAMINATION OF THE HEART**

**WEIGHT**

23.6 lbs

The echocardiogram in this patient demonstrated enlarged **left atrial** size based on 3 different LA measurement methods. Chamber volumes and echogenicity were normal. The cranial and caudal **mitral** valve leaflets presented vegetative thickening consistent with endocardiosis. Prolapse of the anterior mitral valve was noted. Doppler indicated measurable insufficiency. The **left ventricle** presented thicknesses with linear contour and was not dilated nor restricted. The **myocardium** presented normal echogenicity without subjective evidence of significant fibrotic or ischemic disease. **Contractility** of the ventricular walls was adequate and in normal range for this patient evidenced by the fractional shortening measurement and subjective evaluation of the different regions of the myocardium. The **left ventricular outflow** tract demonstrated normal laminar flow and subjective structural integrity. The **right atrium** and auricle revealed normal size, structure and content. No evidence of masses was noted or chamber overload. **Tricuspid** valvular assessment demonstrated adequate linear morphology. The **right ventricle** was of normal size (1/3 diameter of LV), chordae structure, myocardial echogenicity and thickness. **Pulmonic** tract assessment revealed normal valve structure, laminar flow, and diameter (approx. 1:1 pa/ao ratio). No visible **pericardial** or free pleura fluid was noted. No echographically detectable evidence of infiltrative disease was visible. The cranial **mediastinum** and **pericardial regions** were free of masses in the visible window.

**INTERPRETED BY**

Eric Lindquist, DMV  
DABVP, Cert. IVUSS

**IMAGING  
PERFORMED BY**

Jessica Miller, RDMS

**HOSPITAL NAME**

Whippany VH

**REFERRING VET**

Dr. Smith

**INVOICE**

91817

**DATE**

9/14/21



**PATIENT**

Darby Keating

**SPECIES**

Canine

**BREED**

Cavalier King Charles Spaniel

**SEX**

Spayed Female

**AGE**

13 years

**WEIGHT**

23.6 lbs

**INTERPRETED BY**

Eric Lindquist, DMV  
DABVP, Cert. IVUSS

**IMAGING PERFORMED BY**

Jessica Miller, RDMS

**HOSPITAL NAME**

Whippany VH

**REFERRING VET**

Dr. Smith

**INVOICE**

91817

**DATE**

9/14/21

CANINE CARDIAC PARAMETERS	MR VMAX (m/s)	TR VMAX (m/s)	LA/AO (Boon method)	LA/AO (Heart Base; Swe)	FS (%)	EF (%)	EPSS (cm)
NORMAL PARAMETER	4.5-5.5	<2.7	1.3	<1.6	28-40	40-100	<0.6
PATIENT	5.55		1.5	1.8	39	72	0.22
CANINE CARDIAC PARAMETERS	HR (BPM)	AV VMAX (m/s)	PV MAX (m/s)	BODY WEIGHT	LA (2D short axis Base view) (cm)	LVIDd (Avg; 2D and m-mode short axis) (cm)	LVIDs (Avg; 2D and m-mode short axis) (cm)
NORMAL PARAMETER	50-100	0.7-1.7	0.7-1.6				
PATIENT	121	1.84	0.86	23.6 lbs	4.15 max	2.6	

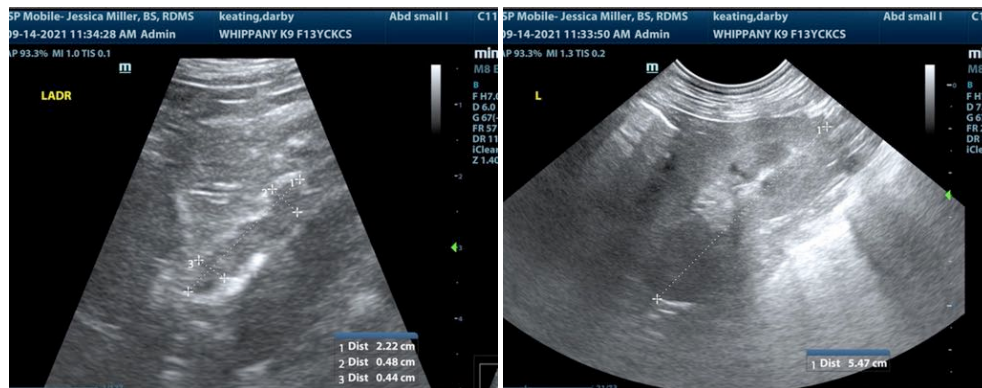
**ULTRASONOGRAPHIC FINDINGS**

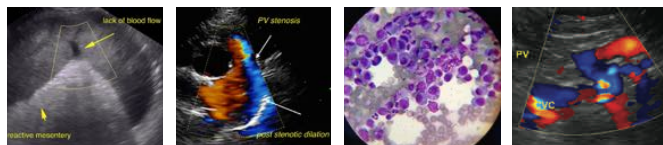
Advanced stage B2 to early C1 valvular disease.

Geriatric abdomen. No evidence of primary pathology.

**INTERPRETATION OF THE FINDINGS & FURTHER RECOMMENDATIONS**

I recommend adding to the current Pimobendan protocol: Lasix 1-2 mg/kg b.i.d., ace inhibitor at 0.5 mg/kg s.i.d. and a recheck echocardiogram in one month. Assessment of BUN, creatinine, USG, chest radiographs and blood pressure as well as clinical exam is ideal in 7-10 days. Basal respiratory rate should be <20/min.





**PATIENT**

Darby Keating

**SPECIES**

Canine

**BREED**

Cavalier King Charles Spaniel

**SEX**

Spayed Female

**AGE**

13 years

**WEIGHT**

23.6 lbs

**INTERPRETED BY**

Eric Lindquist, DMV  
DABVP, Cert. IVUSS

**IMAGING PERFORMED BY**

Jessica Miller, RDMS

**HOSPITAL NAME**

Whippany VH

**REFERRING VET**

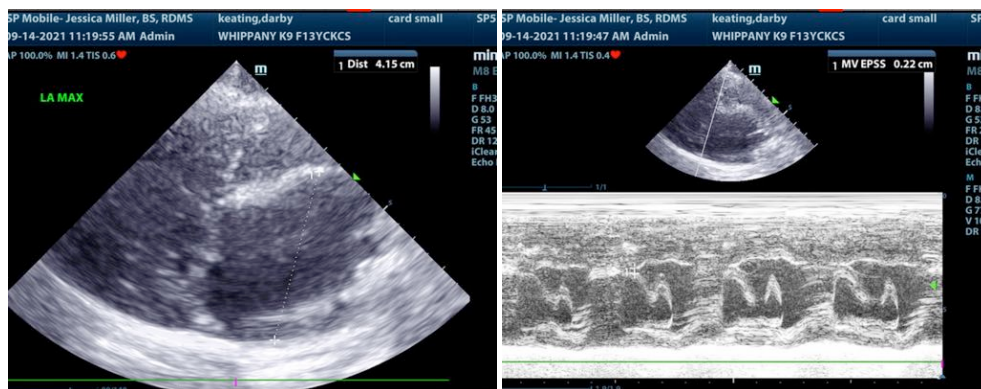
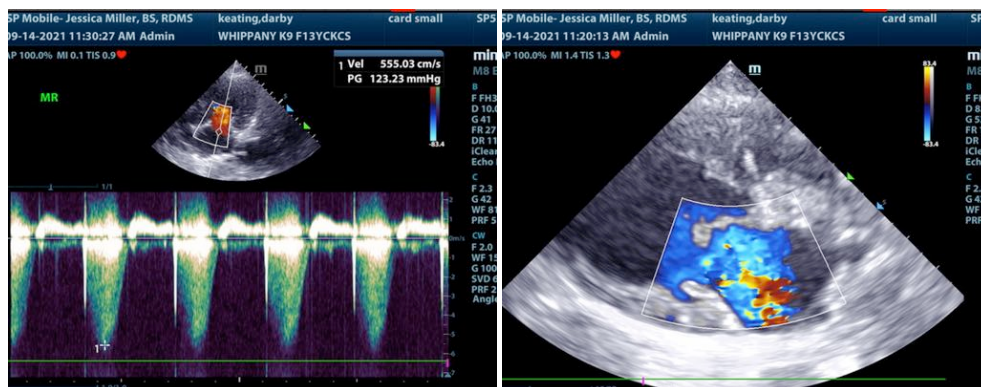
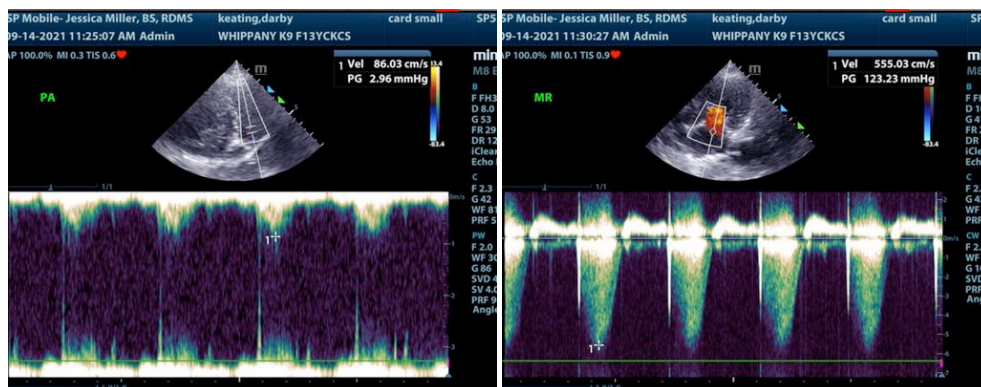
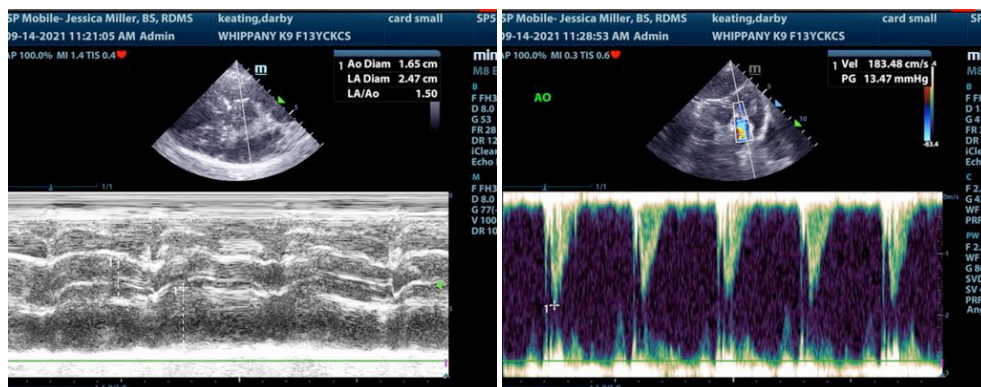
Dr. Smith

**INVOICE**

91817

**DATE**

9/14/21





**PATIENT**

Darby Keating

**SPECIES**

Canine

**BREED**

Cavalier King Charles  
Spaniel

**SEX**

Spayed Female

**AGE**

13 years

**WEIGHT**

23.6 lbs

**INTERPRETED BY**

Eric Lindquist, DMV  
DABVP, Cert. IVUSS

**IMAGING  
PERFORMED BY**

Jessica Miller, RDMS

**HOSPITAL NAME**

Whippany VH

**REFERRING VET**

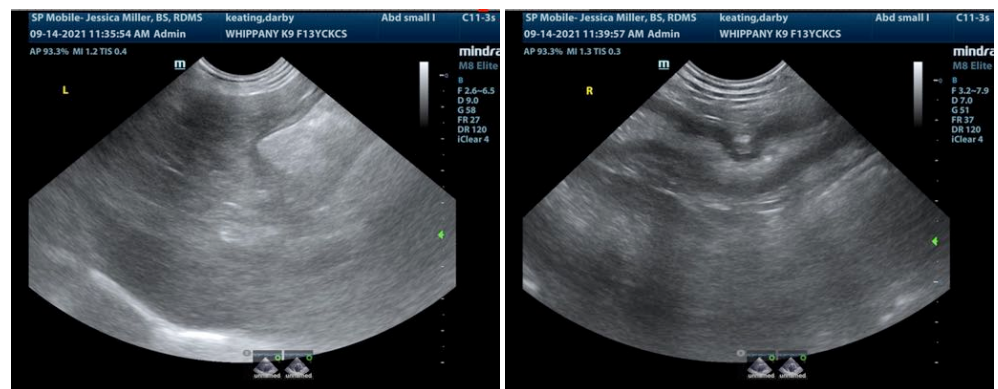
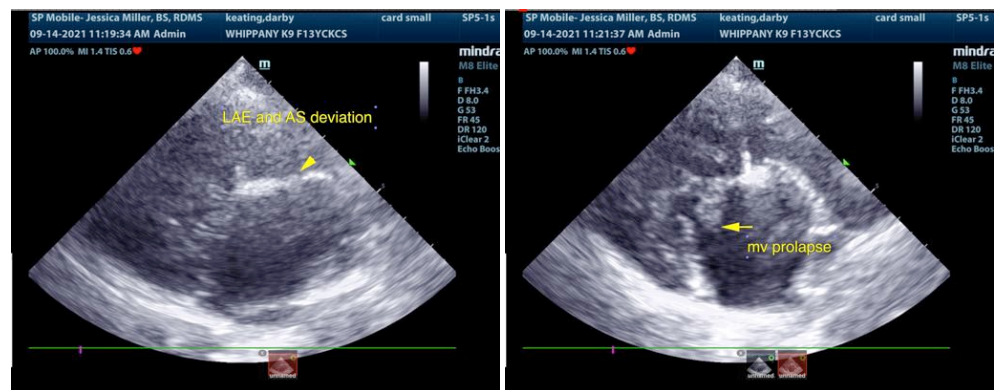
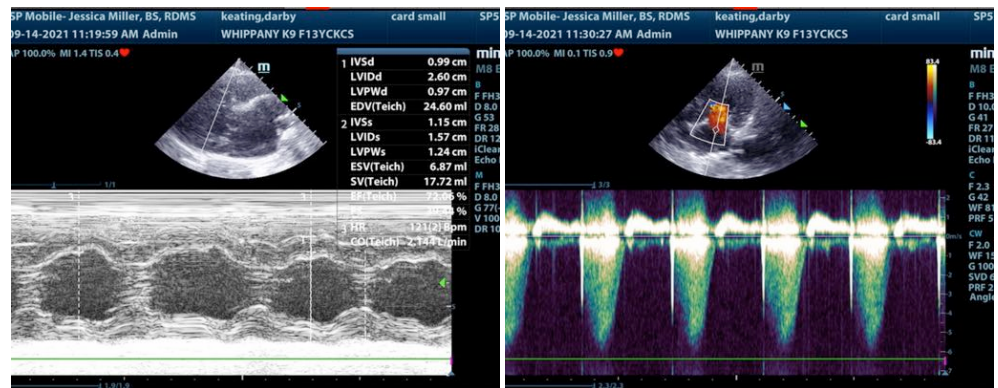
Dr. Smith

**INVOICE**

91817

**DATE**

9/14/21



The information and recommendations provided are based on the images presented by the referring veterinarian. No evaluation can be communicated regarding pathology that was not visible in the image/video clips provided.

Thank you for this referral. If the clinical or image interpretation does not parallel your findings or if I can be of any further assistance please contact me.

Eric Lindquist, DMV, DABVP, Cert. IVUSS, CEO of SonoPath.com  
info@SonoPath.com