

PATIENT

Bruno Lavinio

SPECIES

Canine

BREED

Bernadoodle

SEX

Neutered Male

AGE

2 Years

WEIGHT

86 Pounds

INTERPRETED BY

Eric Lindquist, DMV
DABVP, Cert. IVUSS

IMAGING PERFORMED BY

Dr. Scott

HOSPITAL NAME

Ho Ho Kus VH

REFERRING VET

Dr. Scott

INVOICE

13026

DATE

9/14/21

PRESENTING CLINICAL SIGNS

History: Dry heaving on and off for 4 days (was seen at Bluepearl on Friday night and given cerenia and fluids), doing a bland diet and pepcid AC at home and still no change, will eat well but did vomit up a thick liquid Drooling a lot, eating grass, acting nauseous,

Abnormal PE/Chem/CBC/UA Results: Drooling during exam, swallowing a lot, started drooling more when pressed on cranial abdomen Chem - Creat 1.7 but USG > 1.050, PCV 54%, Rads- gas filled intestines - appear a bit bunched in the caudal abdomen, oddly shaped poop/ foreign material in descending colon Chest rads WNL Currently on IV supportive care.

ULTRASONOGRAPHIC EXAMINATION OF THE ABDOMEN

Urinary System

The **urinary bladder**, trigone, and pelvic urethra presented normal thicknesses and normal tone. The ureters were not visible which is normal. No uroliths or sediment were visualized, and anechoic urine was present. No evidence of inflammatory or neoplastic changes were noted. Ureteral papillae were normal. The pelvic urethra was imaged 2.0 cm beyond the cystourethral junction.

The **kidneys** revealed normal size and structure, corticomedullary definition and ratio for this age. The cortices presented largely uniform texture with normal echogenic relationship to liver and spleen. Medullary structure differed distinctly from the cortex and no evidence of pelvic dilation was present. The capsules were acceptably uniform without significant irregularities. The left kidney measured 5.0 cm. The right kidney measured 5.0 cm.

Adrenal Glands

The **adrenal glands** were not visualized.

Spleen

The **spleen** presented a smooth homogeneous parenchyma hyperechoic to liver and renal cortical parenchyma. The capsule was smooth without noticeable expansion or deviation from within the spleen or adjacent pathology. The splenic vasculature demonstrated normal volume without signs of congestion or thrombosis. No sonographic evidence of acute or chronic inflammatory, neoplastic, or infarctual changes were noted.

Liver

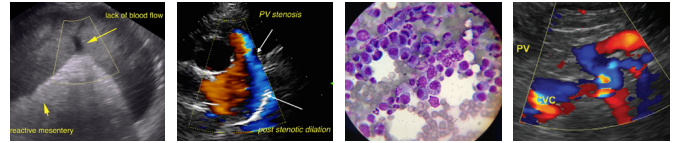
The **liver** images submitted revealed subjectively normal liver size, contour, and structure. Parenchymal echogenicity was naturally coarse and hypoechoic to the spleen. Vascular and biliary tracts were of normal volume with no evidence of congestion. The gallbladder presented acceptably thin walls with primarily anechoic content. The cystic and common bile ducts were normal. No pathological hepatic lymphadenopathy was evident. No overt structural evidence of inflammatory, infiltrative or regenerative pathology was evident.

Gastrointestinal

The **stomach** presented a minor amount of hyperechoic artifact. Minor excessive GI gas is noted. No evidence of obstructive disease. The small intestine and colon were unremarkable.

Pancreas

The base and limbs of the **pancreas** were observed to be largely isoechoic to surrounding omental fat. Pancreatic duct and capsular contour were acceptably normal and parenchyma respected normal curvilinear patterns. No overt evidence of active inflammatory or neoplastic disease was noted.



PATIENT

Bruno Lavinio

ULTRASONOGRAPHIC FINDINGS

- Gastrointestinal upset

SPECIES

Canine

INTERPRETATION OF THE FINDINGS & FURTHER RECOMMENDATIONS

No evidence of foreign body. Supportive GI care should prove effective.

BREED

Bernadoodle

SEX

Neutered Male

AGE

2 Years

WEIGHT

86 Pounds

INTERPRETED BY

Eric Lindquist, DMV
DABVP, Cert. IVUSS

IMAGING PERFORMED BY

Dr. Scott

HOSPITAL NAME

Ho Ho Kus VH

REFERRING VET

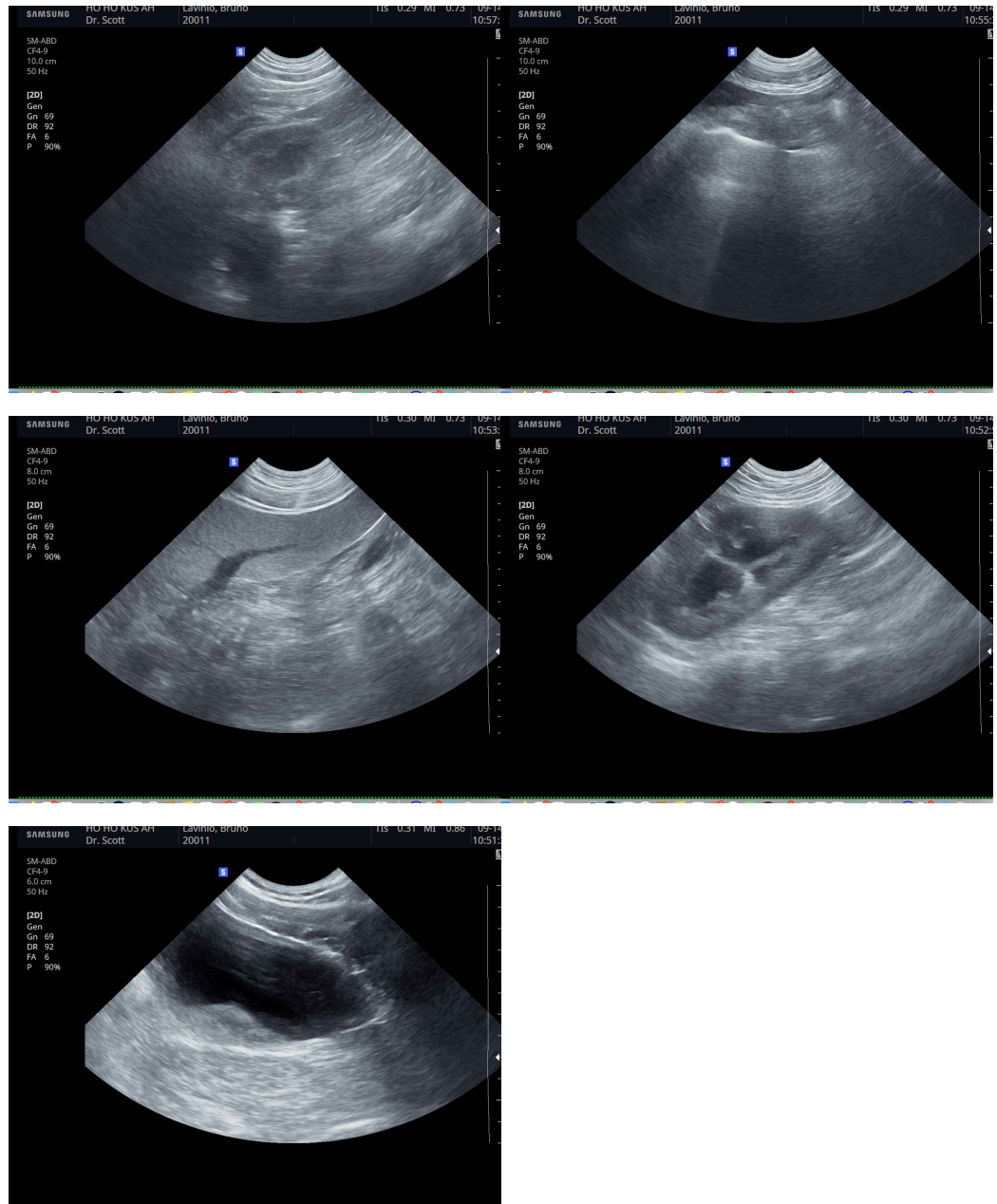
Dr. Scott

INVOICE

13026

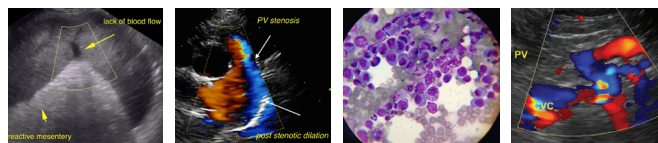
DATE

9/14/21



The information and recommendations provided are based on the images presented by the referring veterinarian. No evaluation can be communicated regarding pathology that was not visible in the image/video clips provided.

Thank you for this referral. If the clinical or image interpretation does not parallel your findings or if I



PATIENT

Bruno Lavinio

can be of any further assistance please contact me.

Eric Lindquist, DMV, DABVP, Cert. IVUSS, CEO of SonoPath.com
info@SonoPath.com

SPECIES

Canine

BREED

Bernadoodle

SEX

Neutered Male

AGE

2 Years

WEIGHT

86 Pounds

INTERPRETED BY

Eric Lindquist, DMV
DABVP, Cert. IVUSS

**IMAGING
PERFORMED BY**

Dr. Scott

HOSPITAL NAME

Ho Ho Kus VH

REFERRING VET

Dr. Scott

INVOICE

13026

DATE

9/14/21