



PATIENT

Lola Motta

SPECIES

Canine

BREED

Dachshund

SEX

Spayed Female

AGE

9 Years

WEIGHT

13.2

INTERPRETED BY

Eric Lindquist, DMV
DABVP, Cert. IVUSS

IMAGING PERFORMED BY

Dr. Mayra Sanchez

HOSPITAL NAME

Sunset Animal Hospital

REFERRING VET

Dr. Mayra Sanchez

INVOICE

25342

DATE

9/11/21

PRESENTING CLINICAL SIGNS

Patient presented for vomiting and retching multiple times Appetite decreased
Abnormal PE/Chem/CBC/UA Results: PE: NSF CBC/chem = HCT 57, remainder WNL Radiographs = thickened stomach wall; no obvious FB or obstruction

ULTRASONOGRAPHIC EXAMINATION OF THE ABDOMEN

Urinary System

The **urinary bladder**, trigone, and pelvic urethra presented normal thicknesses and normal tone. The ureters were not visible which is normal. A minor amount of suspended debris was present. No evidence of inflammatory or neoplastic changes were noted. Ureteral papillae were normal.

The **kidneys** revealed normal size and structure, corticomedullary definition and ratio for this age. The cortices presented largely uniform texture with normal echogenic relationship to liver and spleen. Medullary structure differed distinctly from the cortex and no evidence of pelvic dilation was present. The capsules were acceptably uniform without significant irregularities. The left kidney measured 5.0 cm. The right kidney measured 5.0 cm.

Adrenal Glands

Both **adrenal glands** were visualized and recognized as having normal shape, size, position and echogenicity for this breed. The phrenic vasculature, glandular echogenicity and detail were unremarkable. Capsule, cortex, and medullary definition were normal for this age patient. The left adrenal gland measured 0.5 cm. The right adrenal gland measured 0.4 cm.

Spleen

The **spleen** presented a smooth homogeneous parenchyma hyperechoic to liver and renal cortical parenchyma. The capsule was smooth without noticeable expansion or deviation from within the spleen or adjacent pathology. The splenic vasculature demonstrated normal volume without signs of congestion or thrombosis. No sonographic evidence of acute or chronic inflammatory, neoplastic, or infarctual changes were noted.

Liver

The **liver** revealed slight increased portal markings and minor coarse architecture. The gallbladder and common bile duct were unremarkable.

Gastrointestinal

The **stomach** was filled with ingesta, consistent with post-prandial presentation. The small intestine and colon were unremarkable.

Pancreas

The base and limbs of the **pancreas** were observed to be largely isoechoic to surrounding omental fat. Pancreatic duct and capsular contour were acceptably normal and parenchyma respected normal curvilinear patterns. No overt evidence of active inflammatory or neoplastic disease was noted.

ULTRASONOGRAPHIC FINDINGS

- Structurally unremarkable abdomen, post-prandial presentation



PATIENT

Lola Motta

INTERPRETATION OF THE FINDINGS & FURTHER RECOMMENDATIONS

Dietary indiscretion, food intolerance, structurally insignificant inflammatory bowel or occult parasitism and occult Addison's are all potentials. No evidence of foreign body.

SPECIES

Canine

BREED

Dachshund

SEX

Spayed Female

AGE

9 Years

WEIGHT

13.2

INTERPRETED BY

Eric Lindquist, DMV
DABVP, Cert. IVUS

IMAGING PERFORMED BY

Dr. Mayra Sanchez

HOSPITAL NAME

Sunset Animal Hospital

REFERRING VET

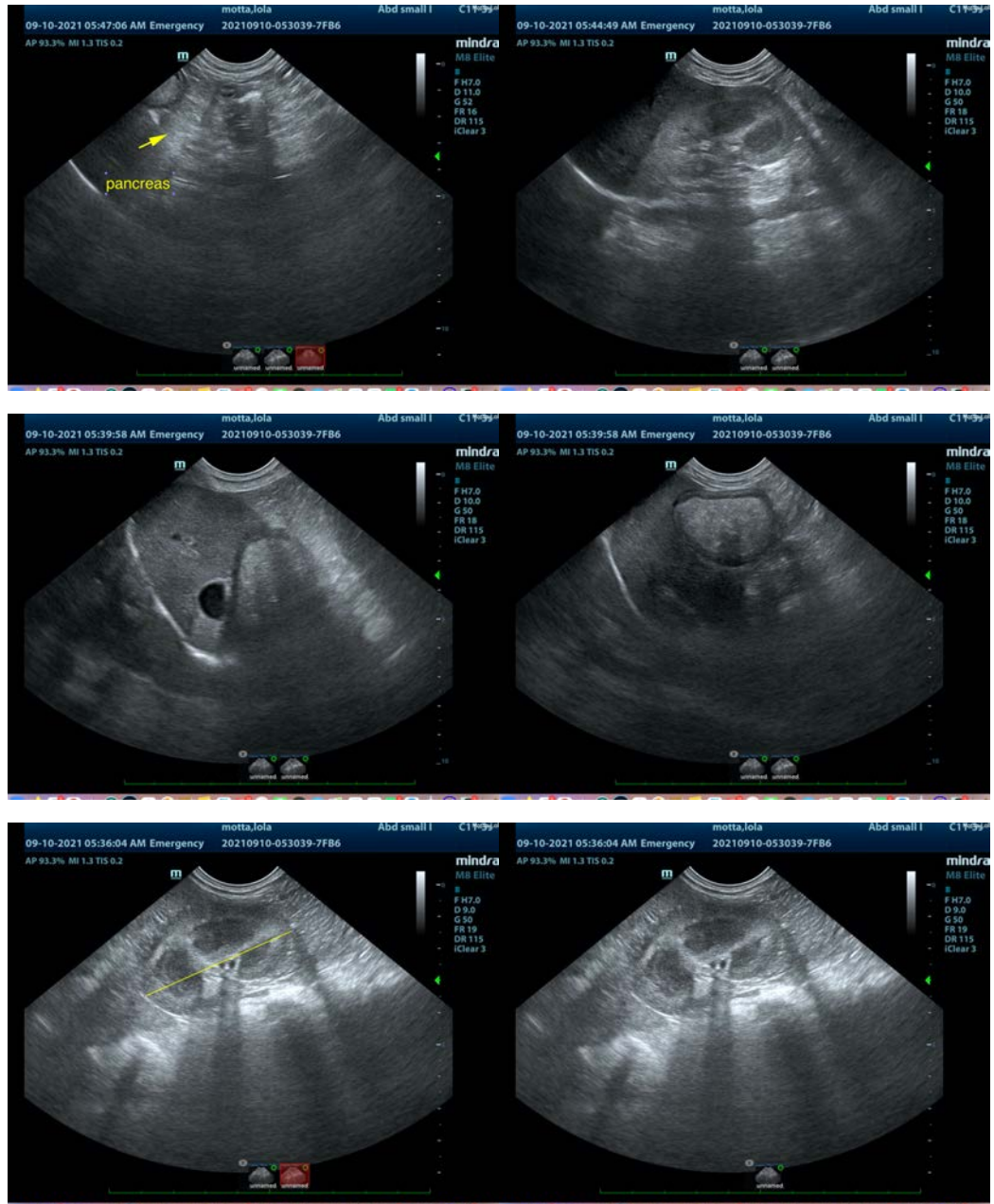Dr. Mayra Sanchez

INVOICE

25342

DATE

9/11/21





PATIENT

Lola Motta

SPECIES

Canine

BREED

Dachshund

SEX

Spayed Female

AGE

9 Years

WEIGHT

13.2

INTERPRETED BY

Eric Lindquist, DMV
DABVP, Cert. IVUSS

IMAGING PERFORMED BY

Dr. Mayra Sanchez

HOSPITAL NAME

Sunset Animal Hospital

REFERRING VET

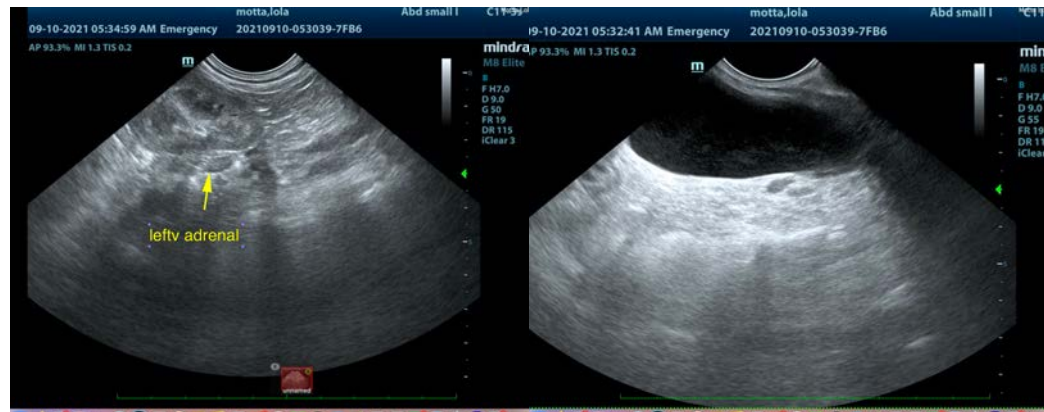
Dr. Mayra Sanchez

INVOICE

25342

DATE

9/11/21



The information and recommendations provided are based on the images presented by the referring veterinarian. No evaluation can be communicated regarding pathology that was not visible in the image/video clips provided.

Thank you for this referral. If the clinical or image interpretation does not parallel your findings or if I can be of any further assistance please contact me.

Eric Lindquist, DMV, DABVP, Cert. IVUSS, CEO of SonoPath.com
info@SonoPath.com