

**DATE**

9/9/22

PRESENTING CLINICAL SIGNS

History: History of Hypertrophic Obstructive Cardiomyopathy with mild LAE.

There was scant pericardial effusion seen 07/15/22. Patient is asymptomatic for cardiac disease at this time. It was recommended to reassess effusion status in 2-3 months. History of episodic seizure episodes since March 2021, well controlled with Zonisamide.

PATIENT

Emmi Fowler

SPECIES

Feline

Current Medications: Zonisamide 25mg QD.

Date of Previous IntraPet Ultrasound: Echocardiograms: 7/15/22, 11/9/21, and 4/2/21.

Sedation: Not required to complete full diagnostic ultrasound.

Stat Report: Not requested.

BREED

DSH

Imaging Performed By: Rachel Brillhart, RDMS.

LIMITED ULTRASONOGRAPHIC EXAMINATION**SEX**

Spayed Female

Images of the liver reveal normal structure without evidence of passive congestion. The gallbladder and common bile duct were unremarkable. A large amount of falciform fat was noted in this patient.

AGE

1/19/11

The extracardiac space revealed excessive thoracic fat. Subjectively cardiac volume and contractility appear to be normal. No pericardial effusion noted. Trace pleural effusion was noted, yet subjectively the left atrial size appears to be normal. However, full recheck echocardiogram is warranted to assess for persistent left atrial enlargement.

WEIGHT

12 Pounds 13 Ounces

ULTRASONOGRAPHIC FINDINGS

- Large amount of thoracic fat
- Nonspecific trace pleural effusion
- Subjectively unremarkable heart

INTERPRETED BY

Eric Lindquist, DMV
DABVP, Cert. IVUSS

INTERPRETATION OF THE FINDINGS & FURTHER RECOMMENDATIONS

Full recheck echocardiogram is warranted to assess for persistent left atrial enlargement. Full abdominal sonogram is warranted to assess for primary pathology that may be causing pleural effusion secondarily, yet this is trace and should not be causing any overt clinical signs. However, it may be a sign of more significant systemic disease.

HOSPITAL NAME

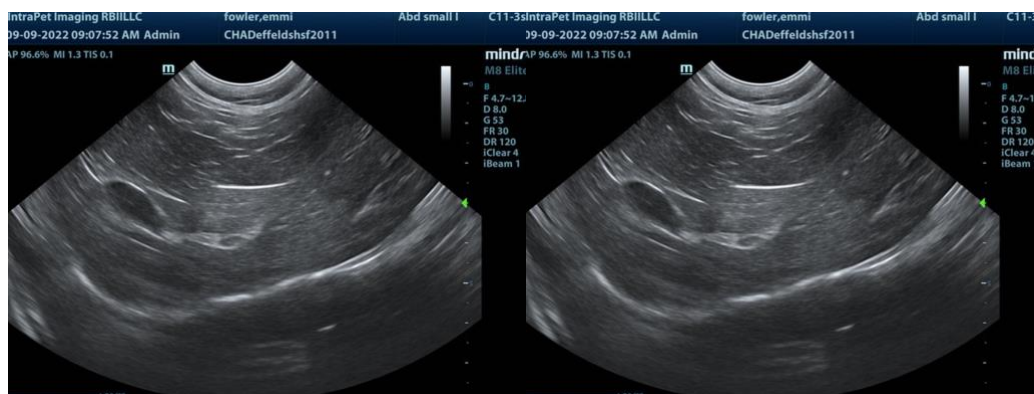
Chadwell AH

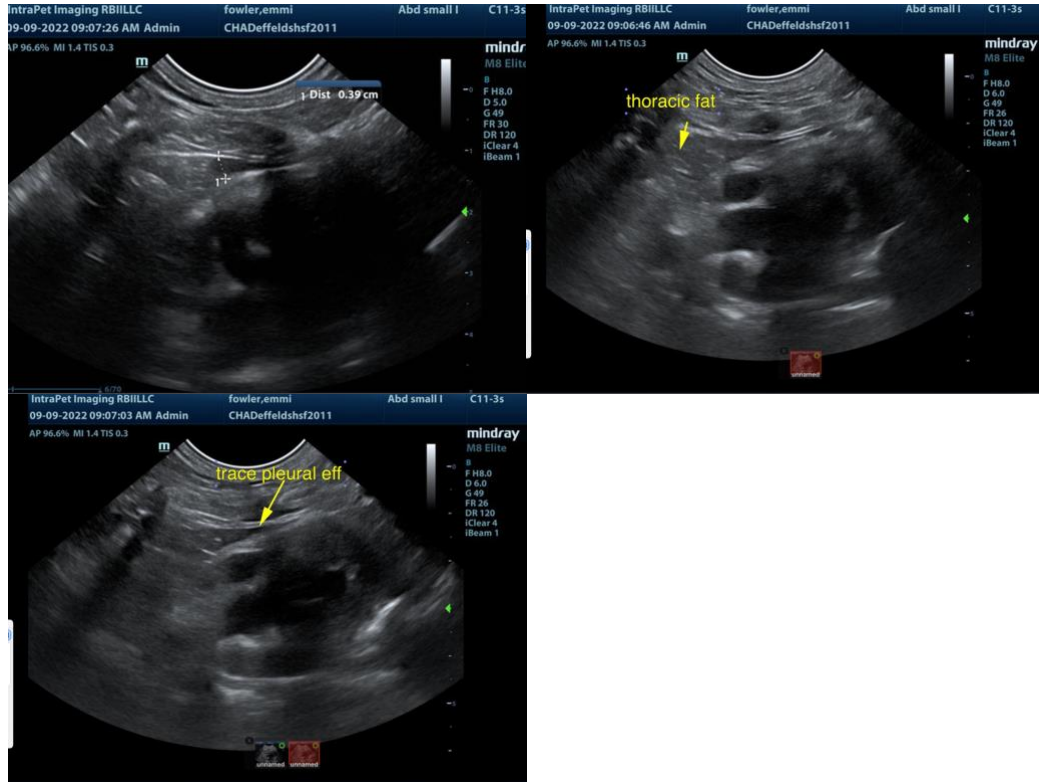
REFERRING VET

Dr. Schaupp

INVOICE

17236





The information and recommendations provided are based on the images presented by the referring veterinarian. No evaluation can be communicated regarding pathology that was not visible in the image/video clips provided.

Thank you for this referral. If the clinical or image interpretation does not parallel your findings or if I can be of any further assistance please contact me.

Eric Lindquist, DMV, DABVP, Cert. IVUSS, CEO of SonoPath.com
info@SonoPath.com