



PATIENT PRESENTING CLINICAL SIGNS

Bruce Karp Patient presents for recheck echo, last one performed by SonoPath mobile on 7/26/21. Current meds: Benazepril 5 mgs, furosemide 12.5 mgs, and Pimobendan 3mgs.

SPECIES ULTRASONOGRAPHIC EXAMINATION OF THE HEART

Canine

BREED

Cavalier King Charles

SEX

Neutered Male

AGE

12 Years

WEIGHT

10 lbs 9 oz

CANINE CARDIAC PARAMETERS	MR VMAX (m/s)	TR VMAX (m/s)	LA/AO (Boon method)	LA/AO (Heart Base; Swe)	FS (%)	EF (%)	EPSS (cm)
NORMAL PARAMETER	4.5-5.5	<2.7	1.3	<1.6	28-40	40-100	<0.6
PATIENT	5.5		NM	1.5	39	72	NM
CANINE CARDIAC PARAMETERS	HR (BPM)	AV VMAX (m/s)	PV MAX (m/s)	BODY WEIGHT (kg)	LA 2D short axis Base view (cm)	LVIDd Avg; 2D and m-mode short axis (cm)	LVIDs Avg; 2D and m-mode short axis (cm)
NORMAL PARAMETER	50-100	0.7-1.7	0.7-1.6				
PATIENT	105	1.9	0.8		2.3	2.18	

Cardiac Presentation

The cardiac presentation has greatly improved compared to the prior sonogram. Occasional arrhythmia noted. Prolapse of the anterior mitral valve leaflet noted. However, the left ventricular and left atrial diameters have improved significantly. Mitral insufficiency is persistently present with moderate to complete filling of the left atrium. Tricuspid insufficiency also noted yet compensated at 2.8 m/sec. The right heart was unremarkable. No pericardial effusion.

INTERPRETED BY

Eric Lindquist, DMV DABVP, Cert. IVUSS

IMAGING PERFORMED BY

Kelly Vazquez

HOSPITAL NAME

Brenda King Vet

ULTRASONOGRAPHIC FINDINGS

- Stable mitral insufficiency on the current protocol

INTERPRETATION OF THE FINDINGS & FURTHER RECOMMENDATIONS

Recheck echo in 3-6 months depending upon the clinical status.

REFERRING VET

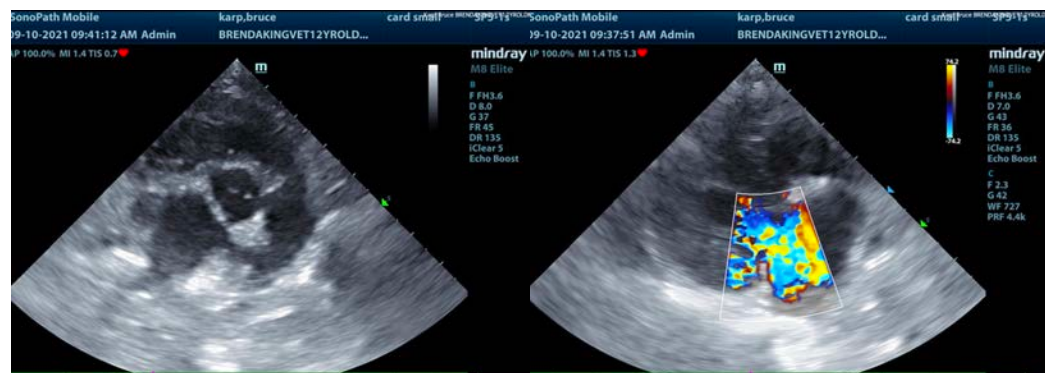Dr. Brenda King

INVOICE

25304

DATE

9/10/21





PATIENT

Bruce Karp

SPECIES

Canine

BREED

Cavalier King Charles

SEX

Neutered Male

AGE

12 Years

WEIGHT

10 lbs 9 oz

INTERPRETED BY

Eric Lindquist, DMV
DABVP, Cert. IVUSS

IMAGING PERFORMED BY

Kelly Vazquez

HOSPITAL NAME

Brenda King Vet

REFERRING VET

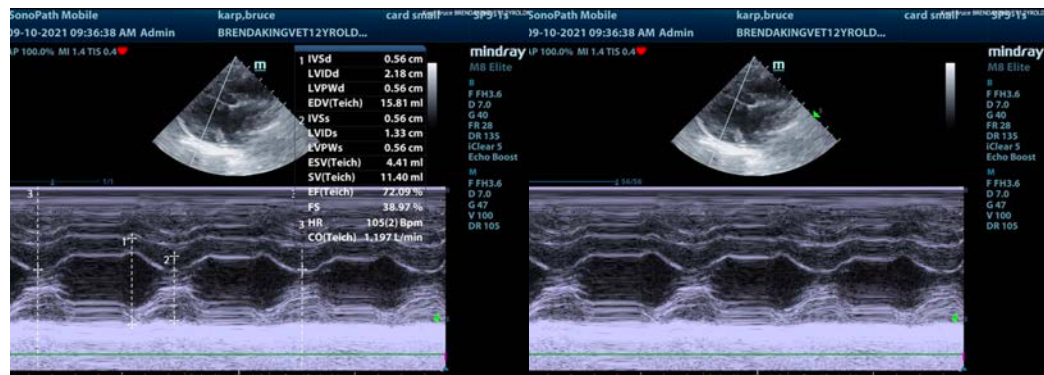
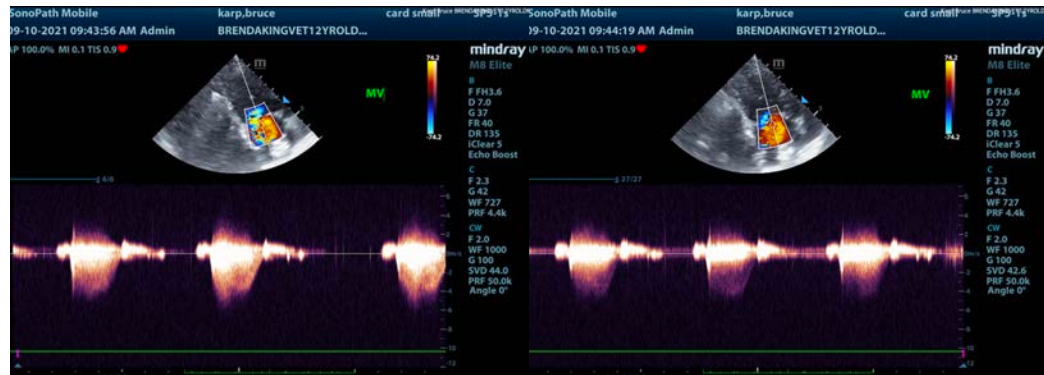
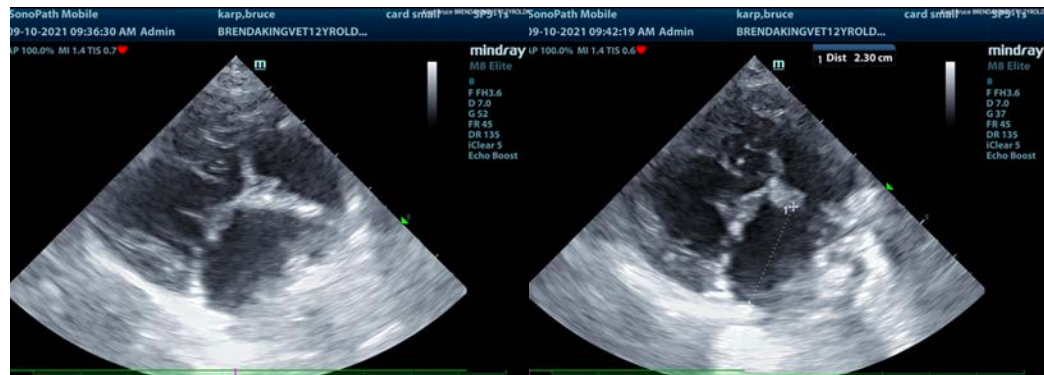
Dr. Brenda King

INVOICE

25304

DATE

9/10/21



The information and recommendations provided are based on the images presented by the referring veterinarian. No evaluation can be communicated regarding pathology that was not visible in the image/video clips provided.

Thank you for this referral. If the clinical or image interpretation does not parallel your findings or if I can be of any further assistance please contact me.

Eric Lindquist, DMV, DABVP, Cert. IVUSS, CEO of SonoPath.com
info@SonoPath.com