



PATIENT

Abby Gerhart

SPECIES

Canine

BREED

Cocker Spaniel

SEX

Spayed Female

AGE

7 Years 10 Months

WEIGHT

11.7 kg

INTERPRETED BY

Eric Lindquist, DMV
DABVP, Cert. IVUSS

IMAGING PERFORMED BY

Dr. Brian Barnes

HOSPITAL NAME

Westview VH

REFERRING VET

Dr. Brian Barnes

INVOICE

12965

DATE

9/10/21

PRESENTING CLINICAL SIGNS

History: Bulging left eye, normal IOPS. US of eye cannot visualize structures behind cornea, significant scleritis, buphthalmous, neovascularization, hyperpigmentation on cornea, distichia still present. HX of TECA, LBO left ear

Abnormal PE/Chem/CBC/UA Results:

LIMITED ULTRASONOGRAPHIC EXAMINATION

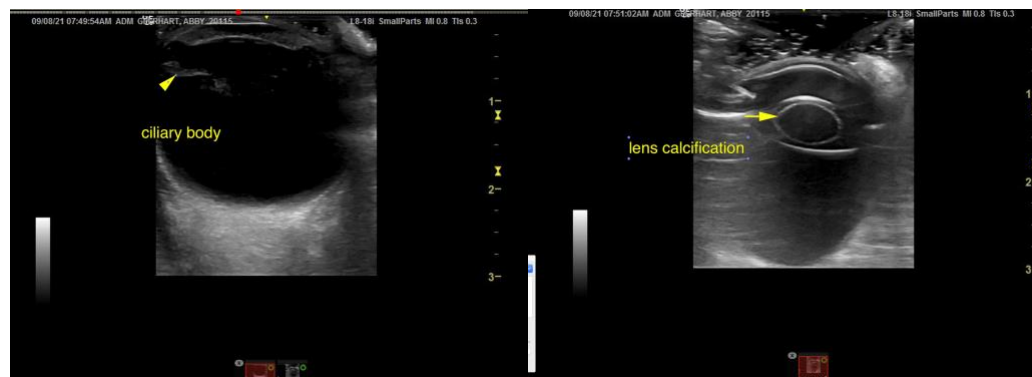
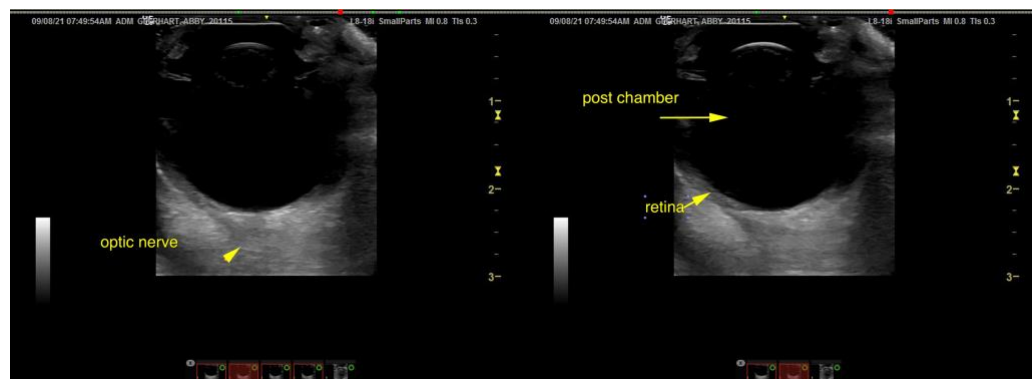
A single eye was imaged in this patient with normal retina, posterior chamber and anterior chamber. The lens appeared to be in proper position, however, was significantly mineralized. A mild amount of suspended debris noted in the posterior chamber, suggestive for inflammation. The retina optic nerve appeared normal. There is some thickening in the ciliary body as well as mineralization of the lens, most consistent with cataracts and chronic uveitis, however, no evidence of tumors present. Posterior chamber was largely intact other than suspended debris.

ULTRASONOGRAPHIC FINDINGS

- Suspect cataracts and uveitis
- Normal posterior chamber other than minor inflammatory sediment

INTERPRETATION OF THE FINDINGS & FURTHER RECOMMENDATIONS

No evidence of tumors.





PATIENT

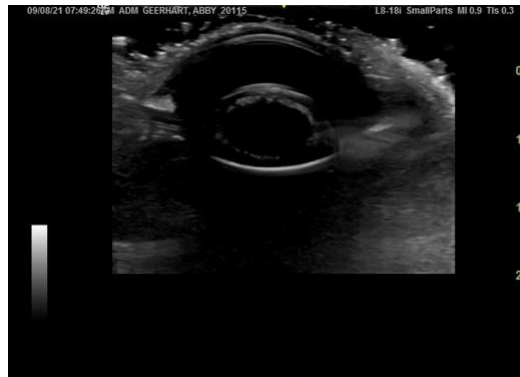Abby Gerhart

SPECIES

Canine

BREED

Cocker Spaniel



SEX

Spayed Female

AGE

7 Years 10 Months

WEIGHT

11.7 kg

INTERPRETED BY

Eric Lindquist, DMV
DABVP, Cert. IVUSS

**IMAGING
PERFORMED BY**

Dr. Brian Barnes

HOSPITAL NAME

Westview VH

REFERRING VET

Dr. Brian Barnes

INVOICE

12965

DATE

9/10/21

The information and recommendations provided are based on the images presented by the referring veterinarian. No evaluation can be communicated regarding pathology that was not visible in the image/video clips provided.

Thank you for this referral. If the clinical or image interpretation does not parallel your findings or if I can be of any further assistance please contact me.

Eric Lindquist, DMV, DABVP, Cert. IVUSS, CEO of SonoPath.com
info@SonoPath.com