



**PATIENT**

Roguen Lewis

**SPECIES**

Canine

**BREED**

Golden Retriever

**SEX**

Neutered male

**AGE**

8 years

**WEIGHT**

40.6 lbs

**INTERPRETED BY**

Eric Lindquist, DMV  
DABVP, Cert. IVUSS

**IMAGING PERFORMED BY**

Dr. Trudeau

**HOSPITAL NAME**

Petworks VH

**REFERRING VET**

Dr. Trudeau

**INVOICE**

32704

**DATE**

9/1/22

**PRESENTING CLINICAL SIGNS**

History: Episode of weakness/listlessness x 2 (end of June and Aug 3/22); currently stable and appears normal Abd u/s to rule out abdomen abnormalities Diagnosed with Subaortic stenosis in 2015 via Dr Cote at AVC - goes every 2yr for rechecks - stable (Atenolol 50mg -1 tab BID), Voltaren SID on left eye for cataract dx with Dr Cullen

Abnormal PE/Chem/CBC/UA Results: CBC/15/lytes/4Dx unremarkable

**ULTRASONOGRAPHIC EXAMINATION OF THE ABDOMEN**

**Urinary System**

The **urinary bladder**, trigone, and pelvic urethra presented normal thicknesses and normal tone. The ureters were not visible which is normal. No uroliths or sediment were visualized and anechoic urine was present. No evidence of inflammatory or neoplastic changes was noted. Ureteral papillae were normal.

The residual prostate was uniform and measured 1.23 cm.

The **kidneys** revealed normal size and structure, corticomedullary definition and ratio for this age. The cortices presented largely uniform texture with normal echogenic relationship to liver and spleen. Medullary structure differed distinctly from the cortex and no evidence of pelvic dilation was present. The capsules were acceptably uniform without significant irregularities. The left kidney measured 6.78 cm. The right kidney measured 7.23 cm.

**Adrenal Glands**

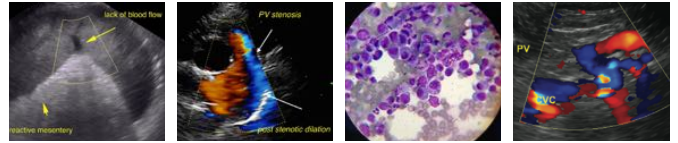
Both **adrenal glands** were visualized and recognized as having normal shape, size, position and echogenicity for this breed. The phrenic vasculature, glandular echogenicity and detail were unremarkable. Capsule, cortex, and medullary definition were normal for this age patient. The left adrenal gland measured 0.44 cm at the cranial pole and 0.49 cm at the caudal pole. The right adrenal gland measured 0.57 cm at the cranial pole and 0.43 cm at the caudal pole.

**Spleen**

The **spleen** revealed multi-focal, hypoechoic non-disruptive nodular changes. This is consistent with hyperlasia.

**Liver**

The **liver** images submitted revealed subjectively normal liver size, contour, and structure. Parenchymal echogenicity was naturally coarse and hypoechoic to the spleen. Vascular and biliary tracts were of normal volume with no evidence of congestion. The gallbladder presented acceptably thin walls with primarily anechoic content. The cystic and common bile ducts were normal. No pathological hepatic lymphadenopathy was evident. No overt structural evidence of inflammatory, infiltrative or regenerative pathology was evident.



**PATIENT**

Roguen Lewis

**SPECIES**

Canine

**BREED**

Golden Retriever

**SEX**

Neutered male

**AGE**

8 years

**WEIGHT**

40.6 lbs

**INTERPRETED BY**

Eric Lindquist, DMV  
DABVP, Cert. IVUSS

**IMAGING  
PERFORMED BY**

Dr. Trudeau

**HOSPITAL NAME**

Petworks VH

**REFERRING VET**

Dr. Trudeau

**INVOICE**

32704

**DATE**

9/1/22

**Gastrointestinal**

Examination of the **gastrointestinal tract** revealed a stomach and intestine free of stasis, of normal wall thickness, acceptable curvilinear mural detail, and peristaltic activity. Small and large intestine demonstrated normal luminal chyme and stool consistency respectively. No obstructive or overt infiltrative disease was noted. No associated abnormal lymphatic activity was noted.

**Pancreas**

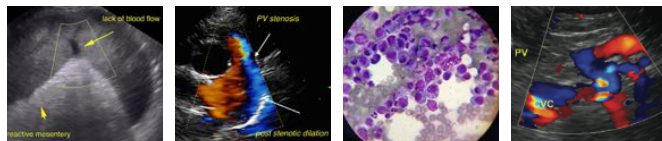
The base and limbs of the **pancreas** were observed to be largely isoechoic to surrounding omental fat. Pancreatic duct and capsular contour were acceptably normal and parenchyma respected normal curvilinear patterns. No overt evidence of active inflammatory or neoplastic disease was noted.

**ULTRASONOGRAPHIC FINDINGS**

Nodular hyperplasia splenic pattern.

**INTERPRETATION OF THE FINDINGS & FURTHER RECOMMENDATIONS**

FNA of the spleen is warranted for further definition as to mild potential for round cell neoplasia or abscessation.



**PATIENT**

Roguen Lewis

**SPECIES**

Canine

**BREED**

Golden Retriever

**SEX**

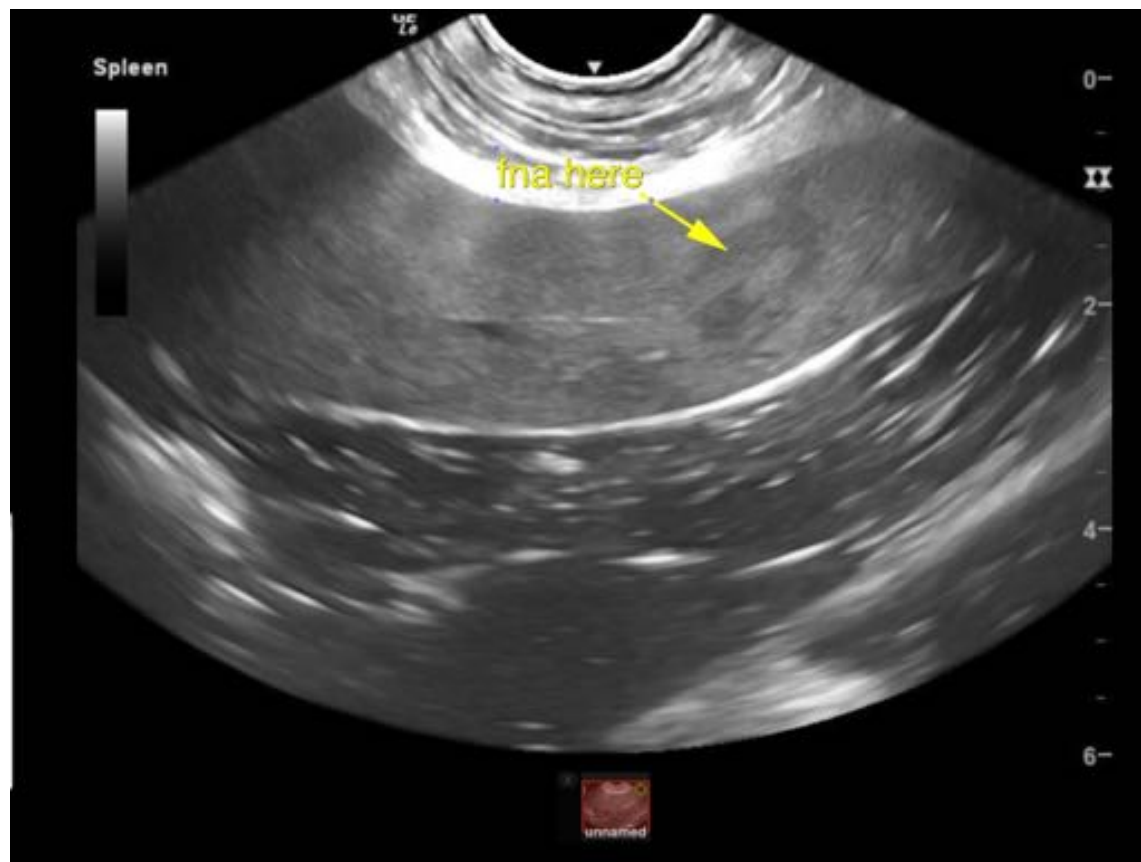
Neutered male

**AGE**

8 years

**WEIGHT**

40.6 lbs



**INTERPRETED BY**

Eric Lindquist, DMV  
DABVP, Cert. IVUSS

**IMAGING  
PERFORMED BY**

Dr. Trudeau

**HOSPITAL NAME**

Petworks VH

**REFERRING VET**

Dr. Trudeau

**INVOICE**

32704

**DATE**

9/1/22



**PATIENT**

Roguen Lewis

**SPECIES**

Canine

**BREED**

Golden Retriever

**SEX**

Neutered male

**AGE**

8 years

**WEIGHT**

40.6 lbs

**INTERPRETED BY**

Eric Lindquist, DMV  
DABVP, Cert. IVUSS

**IMAGING  
PERFORMED BY**

Dr. Trudeau

**HOSPITAL NAME**

Petnetworks VH

**REFERRING VET**

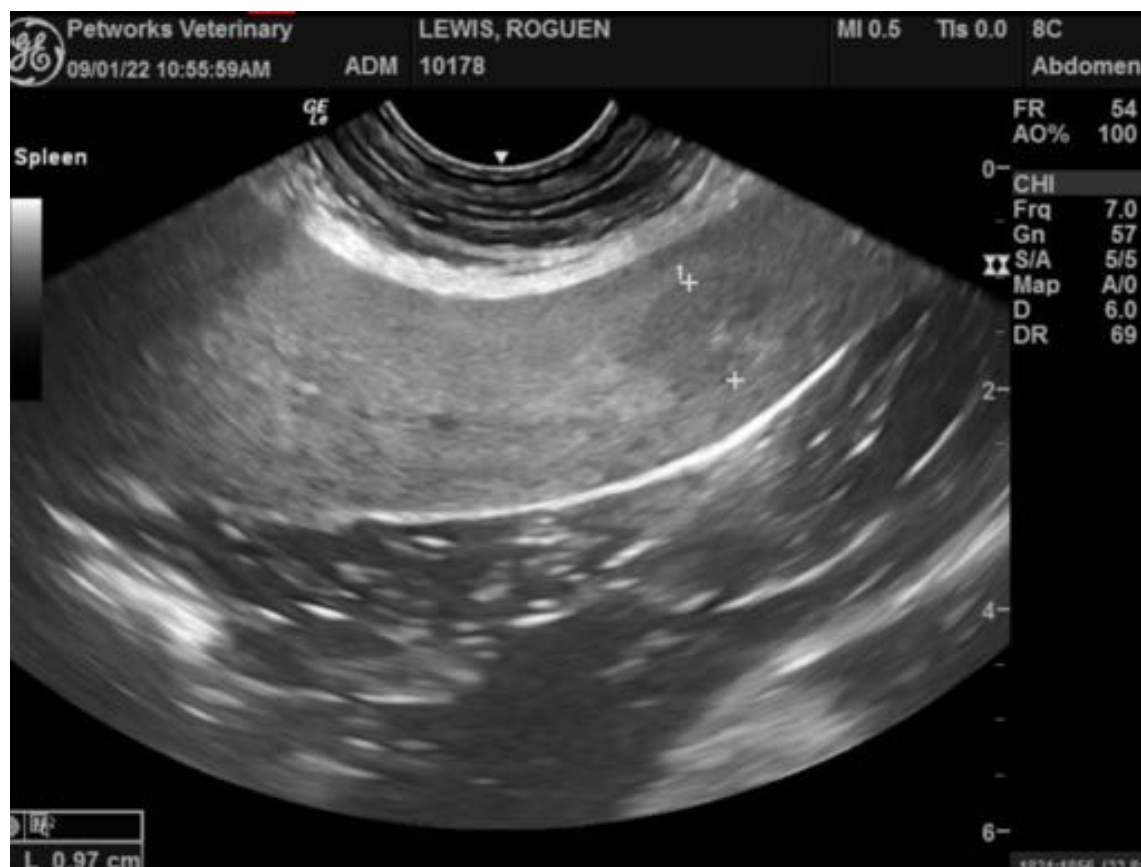Dr. Trudeau

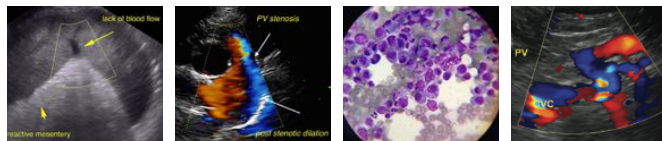
**INVOICE**

32704

**DATE**

9/1/22





## PATIENT

Roguen Lewis

## SPECIES

Canine

## BREED

Golden Retriever

## SEX

Neutered male

## AGE

8 years

## WEIGHT

40.6 lbs

## INTERPRETED BY

Eric Lindquist, DMV  
DABVP, Cert. IVUSS

## IMAGING PERFORMED BY

Dr. Trudeau

## HOSPITAL NAME

Petworks VH

## REFERRING VET

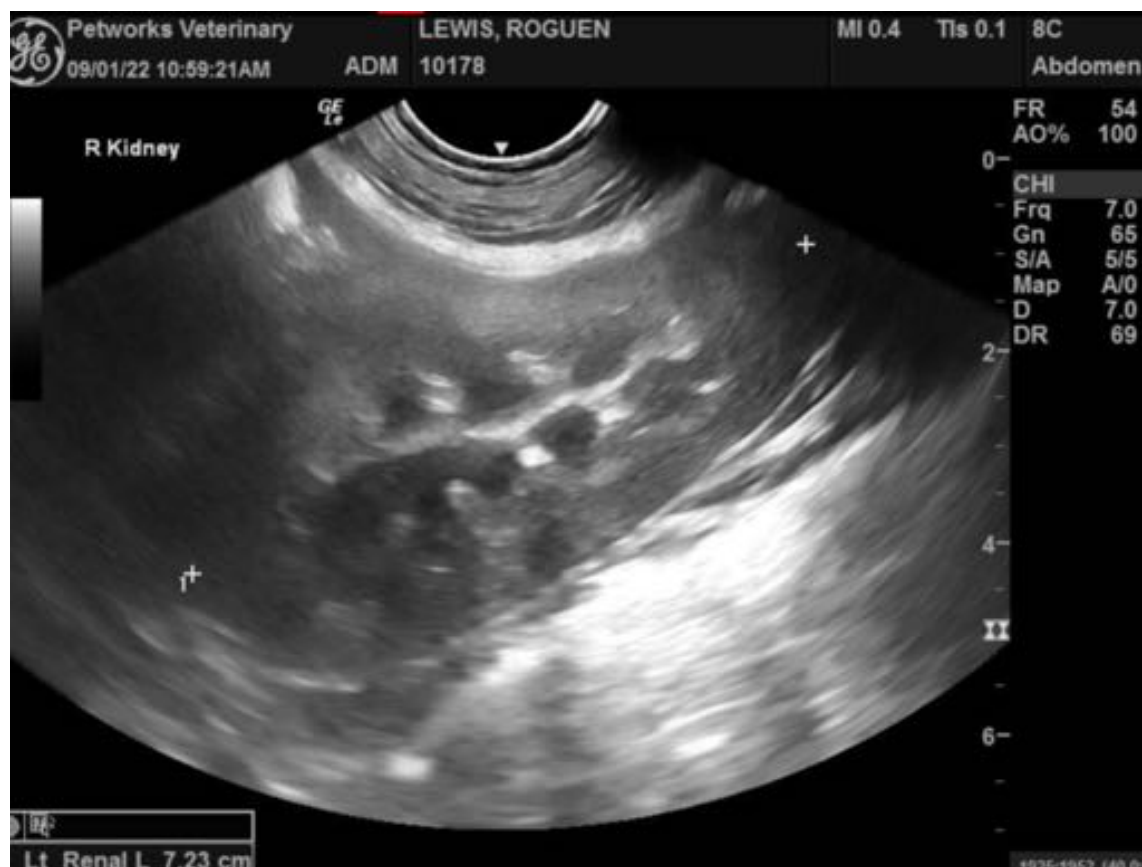Dr. Trudeau

## INVOICE

32704

## DATE

9/1/22





**PATIENT**

Roguen Lewis

**SPECIES**

Canine

**BREED**

Golden Retriever

**SEX**

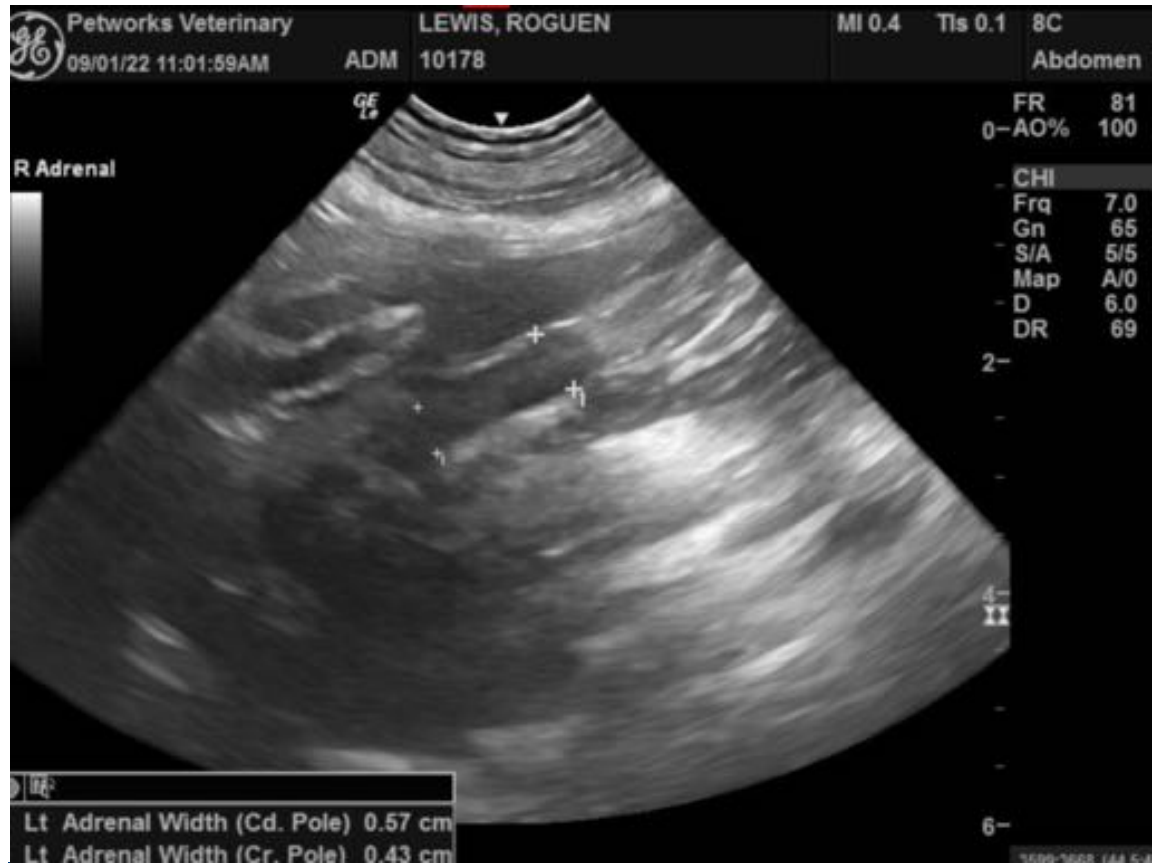Neutered male

**AGE**

8 years

**WEIGHT**

40.6 lbs



**INTERPRETED BY**

Eric Lindquist, DMV  
DABVP, Cert. IVUSS

**IMAGING PERFORMED BY**

Dr. Trudeau

**HOSPITAL NAME**

Petnetworks VH

**REFERRING VET**

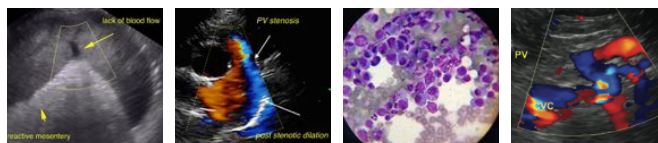
Dr. Trudeau

**INVOICE**

32704

**DATE**

9/1/22



**PATIENT**

Roguen Lewis

**SPECIES**

Canine

**BREED**

Golden Retriever

**SEX**

Neutered male

**AGE**

8 years

**WEIGHT**

40.6 lbs

**INTERPRETED BY**

Eric Lindquist, DMV  
DABVP, Cert. IVUSS

**IMAGING  
PERFORMED BY**

Dr. Trudeau

**HOSPITAL NAME**

Petnetworks VH

**REFERRING VET**

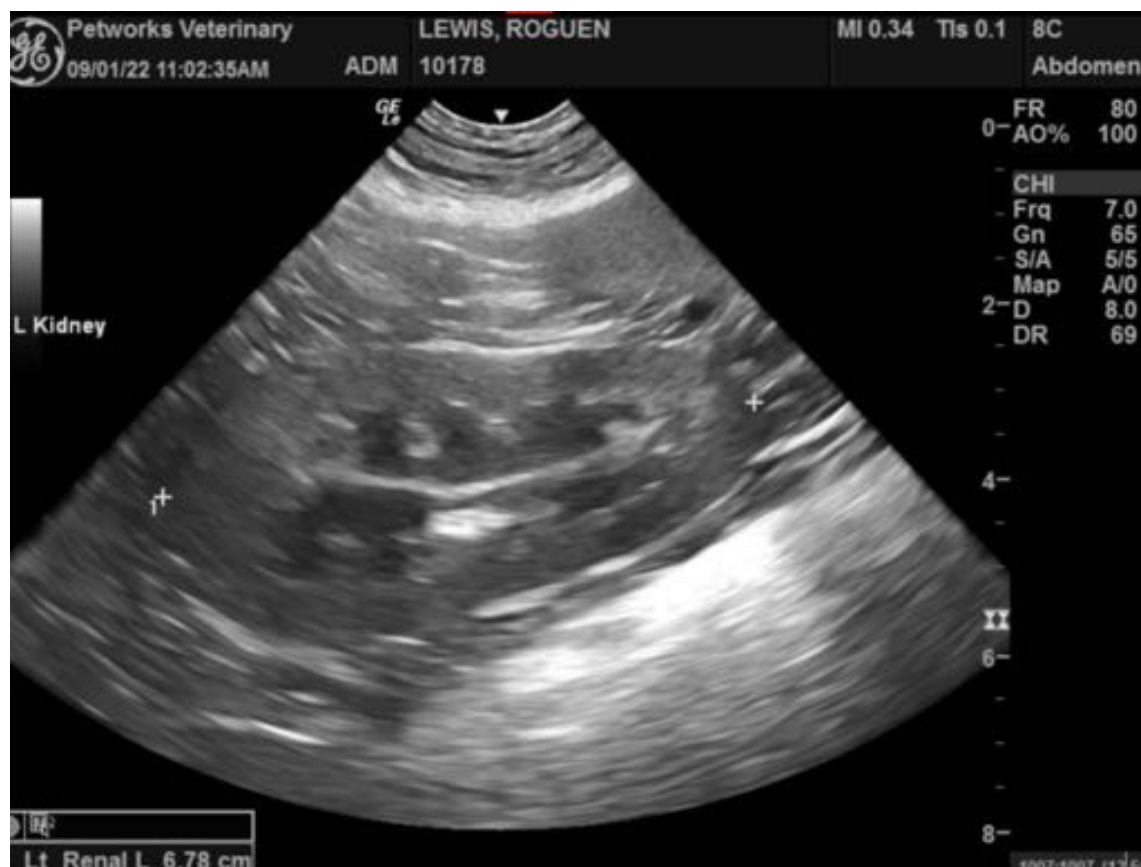Dr. Trudeau

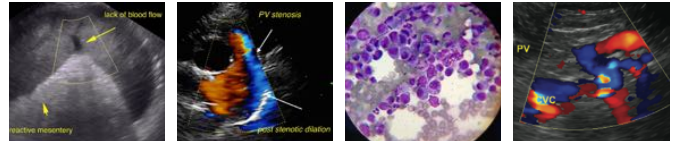
**INVOICE**

32704

**DATE**

9/1/22





**PATIENT**

Roguen Lewis

**SPECIES**

Canine

**BREED**

Golden Retriever

**SEX**

Neutered male

**AGE**

8 years

**WEIGHT**

40.6 lbs

**INTERPRETED BY**

Eric Lindquist, DMV  
DABVP, Cert. IVUSS

**IMAGING PERFORMED BY**

Dr. Trudeau

**HOSPITAL NAME**

Petnetworks VH

**REFERRING VET**

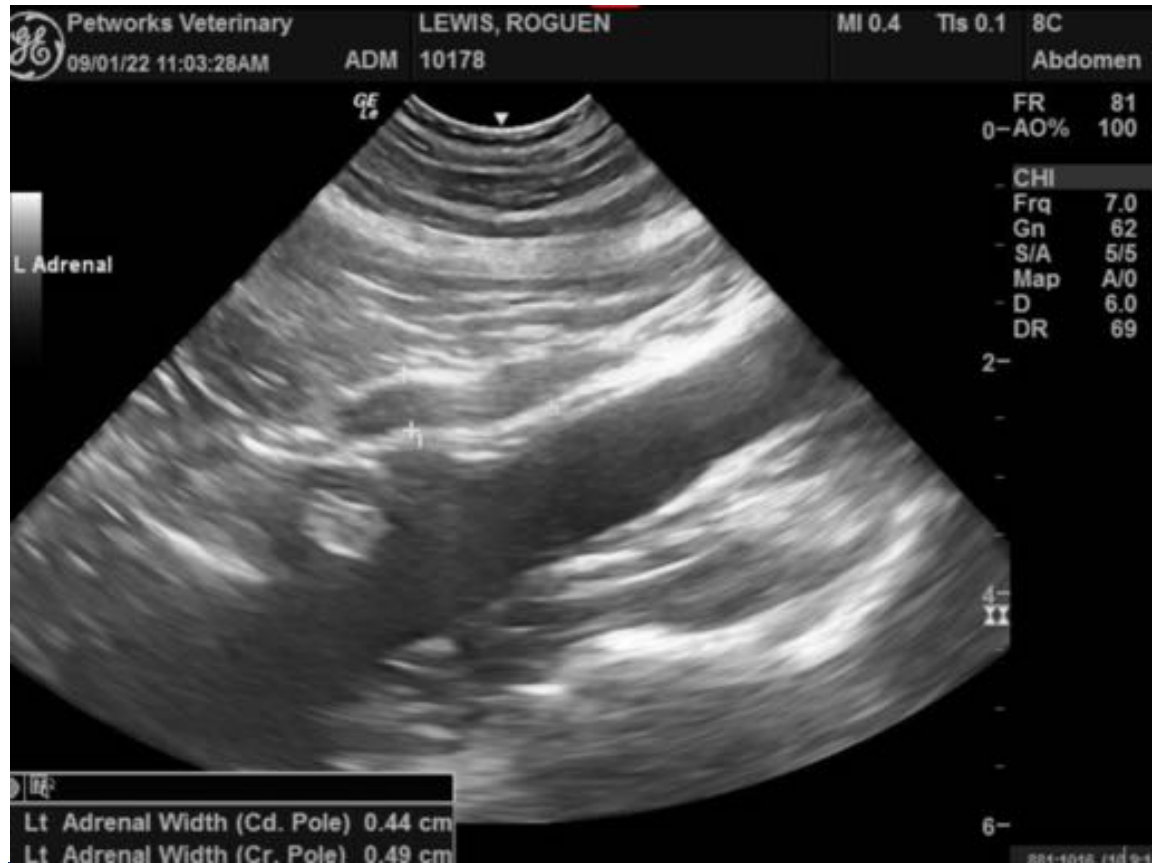Dr. Trudeau

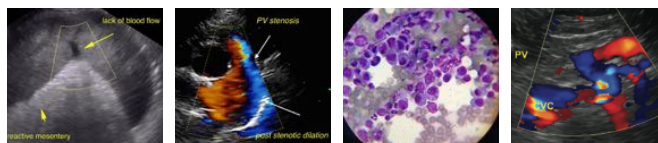
**INVOICE**

32704

**DATE**

9/1/22





## PATIENT

Roguen Lewis

## SPECIES

Canine

## BREED

Golden Retriever

## SEX

Neutered male

## AGE

8 years

## WEIGHT

40.6 lbs

## INTERPRETED BY

Eric Lindquist, DMV  
DABVP, Cert. IVUSS

## IMAGING PERFORMED BY

Dr. Trudeau

## HOSPITAL NAME

Petnetworks VH

## REFERRING VET

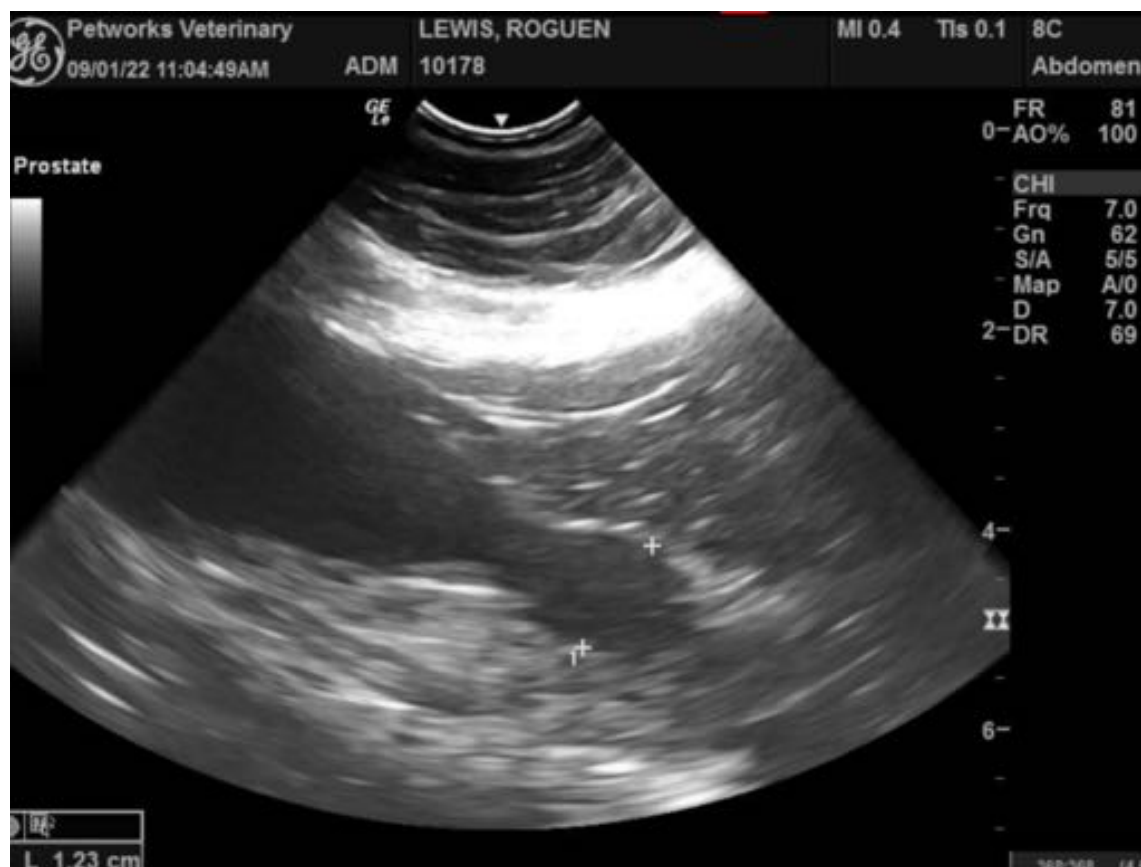Dr. Trudeau

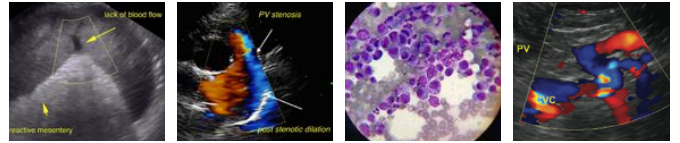
## INVOICE

32704

## DATE

9/1/22





**PATIENT**

Roguen Lewis

**SPECIES**

Canine

**BREED**

Golden Retriever

**SEX**

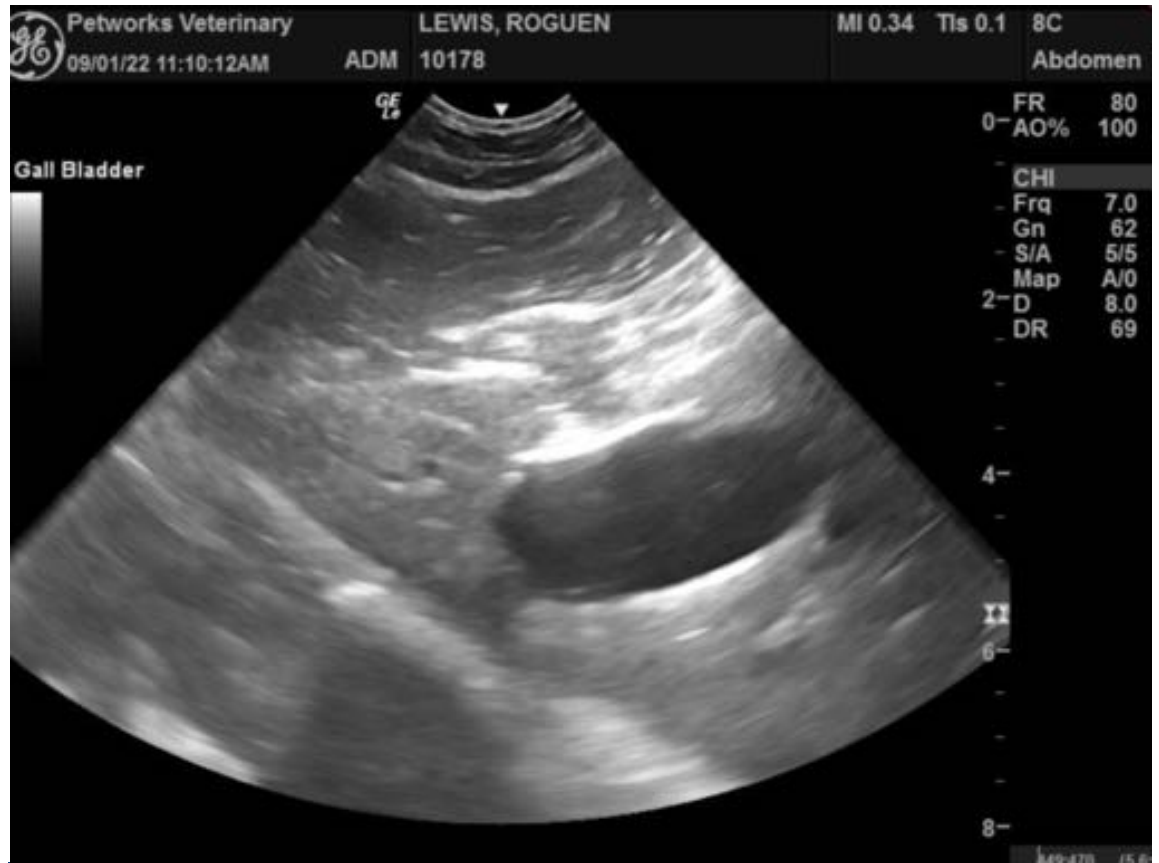Neutered male

**AGE**

8 years

**WEIGHT**

40.6 lbs



**INTERPRETED BY**

Eric Lindquist, DMV  
DABVP, Cert. IVUSS

**IMAGING PERFORMED BY**

Dr. Trudeau

**HOSPITAL NAME**

Petworks VH

**REFERRING VET**

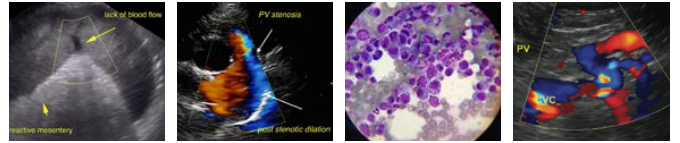
Dr. Trudeau

**INVOICE**

32704

**DATE**

9/1/22



**PATIENT**

Roguen Lewis

**SPECIES**

Canine

**BREED**

Golden Retriever

**SEX**

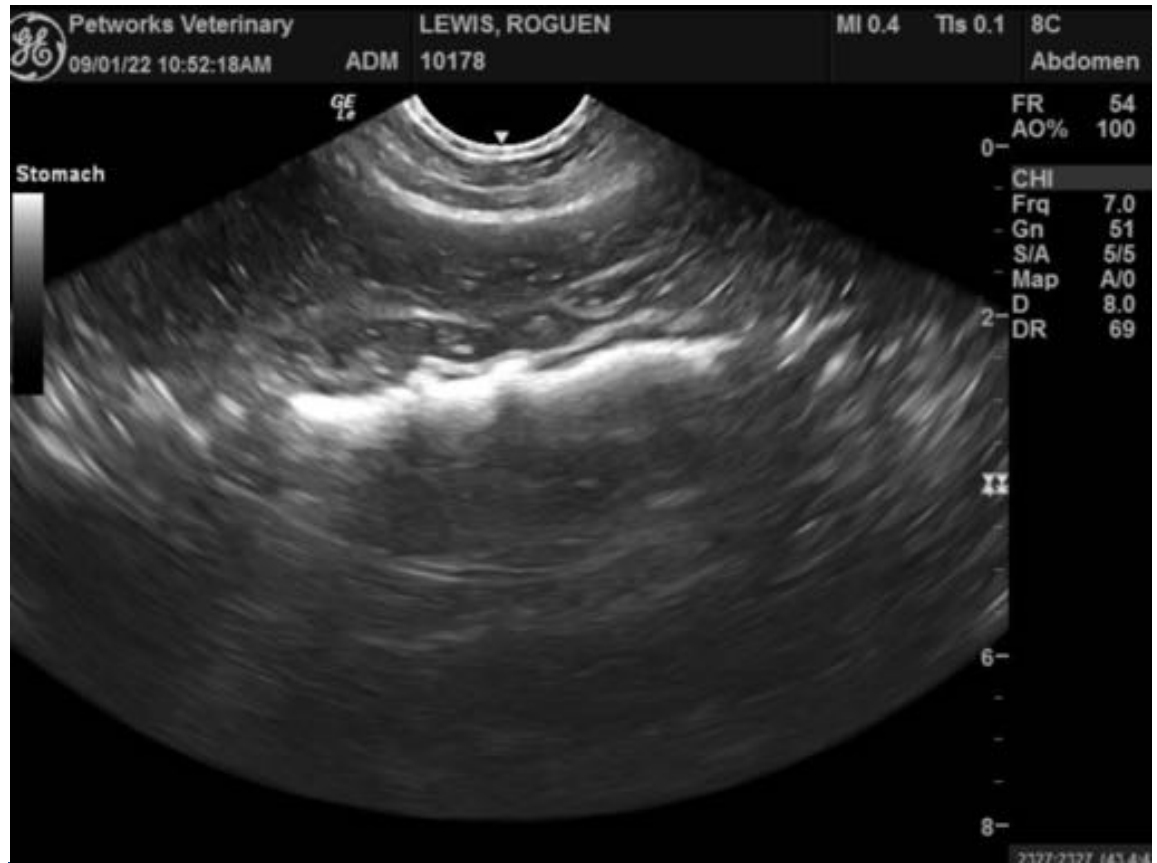Neutered male

**AGE**

8 years

**WEIGHT**

40.6 lbs



**INTERPRETED BY**

Eric Lindquist, DMV  
DABVP, Cert. IVUSS

**IMAGING PERFORMED BY**

Dr. Trudeau

**HOSPITAL NAME**

Petworks VH

**REFERRING VET**

Dr. Trudeau

**INVOICE**

32704

**DATE**

9/1/22

The information and recommendations provided are based on the images presented by the referring veterinarian/sonographer. No evaluation can be communicated regarding pathology that was not visible in the image/video clips provided.

Thank you for this referral. If the clinical or image interpretation does not parallel your findings or if I can be of any further assistance please contact me.

**Eric Lindquist**, DMV, DABVP, Cert. IVUSS, CEO of SonoPath.com  
info@SonoPath.com