



**PATIENT**

Monster Ferguson

**PRESENTING CLINICAL SIGNS**

History: recheck soft shadowing gastric material

**SPECIES**

Canine

**ULTRASONOGRAPHIC EXAMINATION OF THE ABDOMEN**

**Urinary System**

**BREED**

Pitbull

The **urinary bladder**, trigone, and pelvic urethra presented normal thicknesses and normal tone. The ureters were not visible which is normal. No uroliths or sediment were visualized and anechoic urine was present. No evidence of inflammatory or neoplastic changes was noted. Ureteral papillae were normal.

**SEX**

Neutered male

The **kidneys** were normal in size and contour with idiopathic, hyperechoic medullary rim sign and is not overtly pathological unless underlying proteinuria is an issue. The left kidney measured 7.28 cm.

**AGE**

7 years

**Adrenal Glands**

**WEIGHT**

108 lbs

Both **adrenal glands** were visualized and recognized as having normal shape, size, position and echogenicity for this breed. The phrenic vasculature, glandular echogenicity and detail were unremarkable. Capsule, cortex, and medullary definition were normal for this age patient. The right adrenal gland measured 2.42 x 0.82 cm at the caudal pole and 0.67 cm at the cranial pole. The left adrenal gland measured 1.58 x 0.67 cm at the caudal pole and 0.53 cm at the cranial pole.

**INTERPRETED BY**

Eric Lindquist, DMV  
DABVP, Cert. IVUSS

**Spleen**

**IMAGING PERFORMED BY**

Jenn

The **spleen** presented a smooth homogeneous parenchyma hyperechoic to liver and renal cortical parenchyma. The capsule was smooth without noticeable expansion or deviation from within the spleen or adjacent pathology. The splenic vasculature demonstrated normal volume without signs of congestion or thrombosis. No sonographic evidence of acute or chronic inflammatory, neoplastic, or infarctual changes was noted.

**HOSPITAL NAME**

Rockaway AH

**Liver**

**REFERRING VET**

Dr. Maniar

The **liver** images submitted revealed subjectively normal liver size, contour, and structure. Parenchymal echogenicity was naturally coarse and hypoechoic to the spleen. Vascular and biliary tracts were of normal volume with no evidence of congestion. The gallbladder revealed small calculi noted.

**INVOICE**

32695

**Gastrointestinal**

**DATE**

9/1/22

The **stomach** revealed persistent ingesta. Some of the ingesta was shadowing. Progressively shadowing luminal gastric material was noted. This is consistent with ingesta with no overt evidence of obstruction. There was no overt foreign body noted. The small intestine and colon were unremarkable.



**PATIENT**

**Pancreas**

Monster Ferguson

The base and limbs of the **pancreas** were observed to be largely isoechoic to surrounding omental fat. Pancreatic duct and capsular contour were acceptably normal and parenchyma respected normal curvilinear patterns. No overt evidence of active inflammatory or neoplastic disease was noted.

**SPECIES**

Canine

**ULTRASONOGRAPHIC FINDINGS**

**BREED**

Pitbull

Shadowing gastric material, consistent with ingesta.

**SEX**

Neutered male

**INTERPRETATION OF THE FINDINGS & FURTHER RECOMMENDATIONS**

Medical management is indicated.

**AGE**

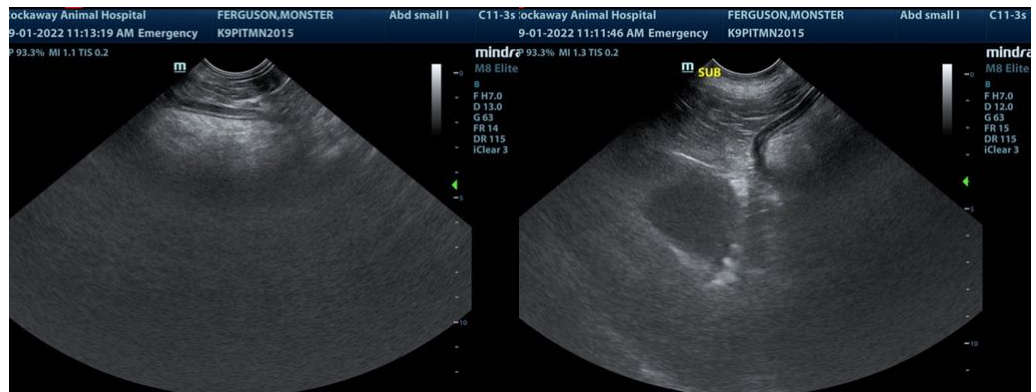
7 years

**WEIGHT**

108 lbs

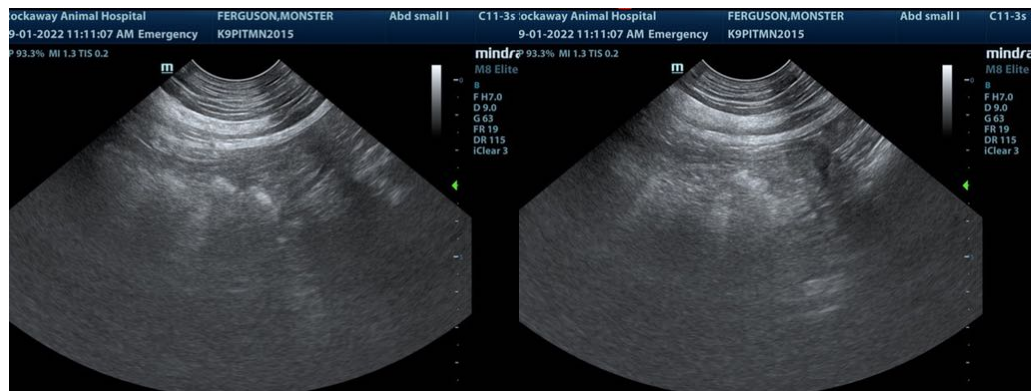
**INTERPRETED BY**

Eric Lindquist, DMV  
DABVP, Cert. IVUS



**IMAGING PERFORMED BY**

Jenn



**HOSPITAL NAME**

Rockaway AH

**REFERRING VET**

Dr. Maniar

**INVOICE**

32695

**DATE**

9/1/22



**PATIENT**

Monster Ferguson

**SPECIES**

Canine

**BREED**

Pitbull

**SEX**

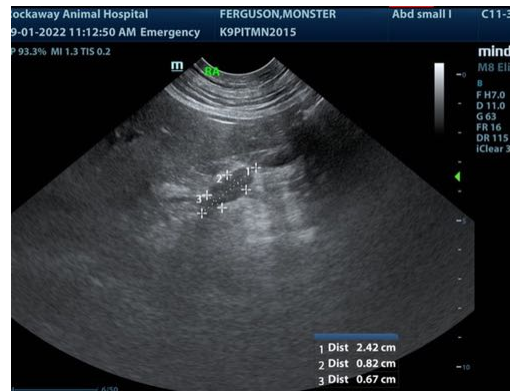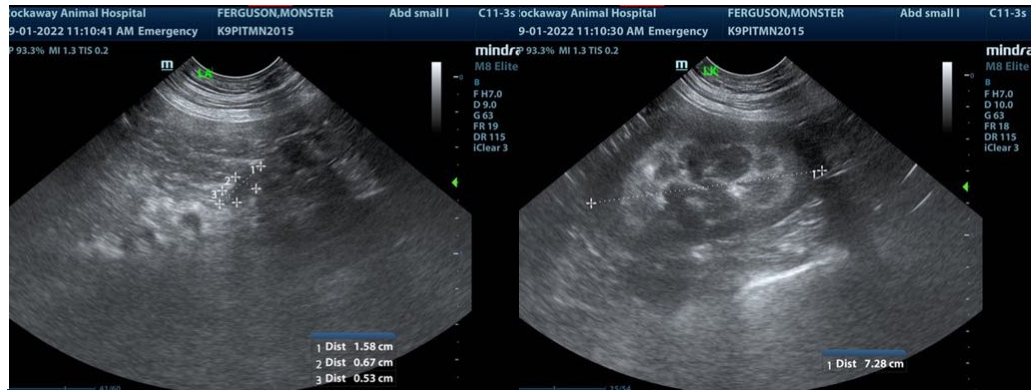
Neutered male

**AGE**

7 years

**WEIGHT**

108 lbs



**INTERPRETED BY**

Eric Lindquist, DMV  
DABVP, Cert. IVUSS

The information and recommendations provided are based on the images presented by the referring veterinarian/sonographer. No evaluation can be communicated regarding pathology that was not visible in the image/video clips provided.

**IMAGING PERFORMED BY**

Jenn

Eric Lindquist, DMV, DABVP, Cert. IVUSS, CEO of SonoPath.com  
info@SonoPath.com

**HOSPITAL NAME**

Rockaway AH

**REFERRING VET**

Dr. Maniar

**INVOICE**

32695

**DATE**

9/1/22

Thank you for this referral. If the clinical or image interpretation does not parallel your findings or if I can be of any further assistance please contact me.