



PATIENT

Frankie Chrust

PRESENTING CLINICAL SIGNS

Weight loss.

SPECIES

Feline

ULTRASONOGRAPHIC EXAMINATION OF THE ABDOMEN

Urinary System

The **urinary bladder**, trigone, and pelvic urethra presented normal thicknesses and normal tone. The ureters were not visible which is normal. No uroliths or sediment were visualized and anechoic urine was present. No evidence of inflammatory or neoplastic changes were noted. Ureteral papillae were normal.

BREED

DSH

The **kidneys** presented a relatively uniform cortical hyperechogenicity when compared to the renal medulla, spleen and liver. No overt masses were noted. Corticomedullary definition was nebulous and the ratio favored the cortex slightly. The ureters were not visible and assumed to be normal. These changes are most consistent with chronic interstitial nephritis yet infiltrative disease could not be entirely ruled out without biopsy though neoplasia is not suspected. The kidneys measured 3.5 cm each.

SEX

Neutered Male

AGE

10 Years

Adrenal Glands

The regions of the **adrenal glands** were unremarkable.

WEIGHT

12.3 Pounds

Spleen

The **spleen** presented a smooth homogeneous parenchyma hyperechoic to liver and renal cortical parenchyma. The capsule was smooth without noticeable expansion or deviation from within the spleen or adjacent pathology. The splenic vasculature demonstrated normal volume without signs of congestion or thrombosis. No sonographic evidence of acute or chronic inflammatory, neoplastic, or infarctual changes were noted.

INTERPRETED BY

Eric Lindquist, DMV

Liver

DABVP, Cert. IVUSS

The **liver** images submitted revealed subjectively normal liver size, contour, and structure. Parenchymal echogenicity was naturally coarse and hypoechoic to the spleen. Vascular and biliary tracts were of normal volume with no evidence of congestion. The gallbladder presented acceptably thin walls with primarily anechoic content. The cystic and common bile ducts were normal. No pathological hepatic lymphadenopathy was evident. No overt structural evidence of inflammatory, infiltrative or regenerative pathology was evident.

IMAGING PERFORMED BY

Eric Lindquist, DMV

DABVP, Cert. IVUSS

Gastrointestinal

HOSPITAL NAME

Franklin Lakes AH

The **stomach** revealed a 2.6 cm shadowing, non-obstructive structure, consistent with likely hairball accumulation. The small intestine and colon were unremarkable.

Pancreas

REFERRING VET

Dr. Kozak

The base and limbs of the **pancreas** were observed to be largely isoechoic to surrounding omental fat. Pancreatic duct and capsular contour were acceptably normal and parenchyma respected normal curvilinear patterns. No overt evidence of active inflammatory or neoplastic disease was noted.

INVOICE

40937

ULTRASONOGRAPHIC FINDINGS

- Interstitial nephrosis renal pattern
- Hairball density in the gastric fundus

DATE

9/1/22



PATIENT

Frankie Chrust

INTERPRETATION OF THE FINDINGS & FURTHER RECOMMENDATIONS

Hairball therapy warranted. Assessment for pain related disease warranted given the patient history.

SPECIES

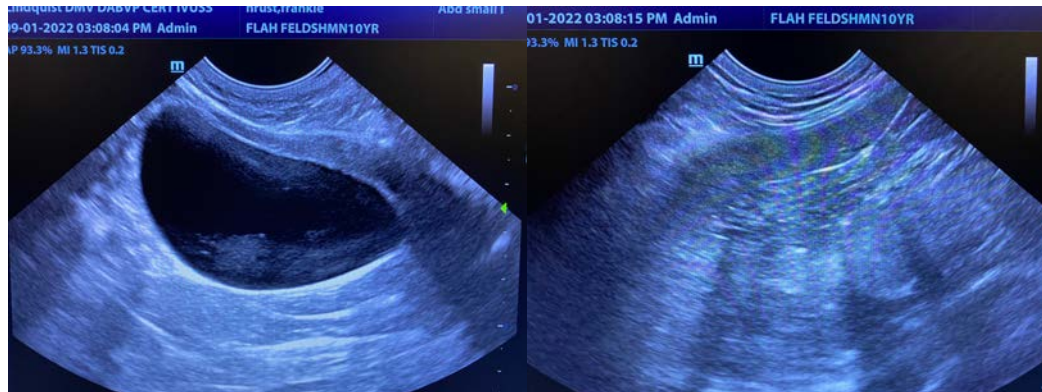
Feline

BREED

DSH

SEX

Neutered Male

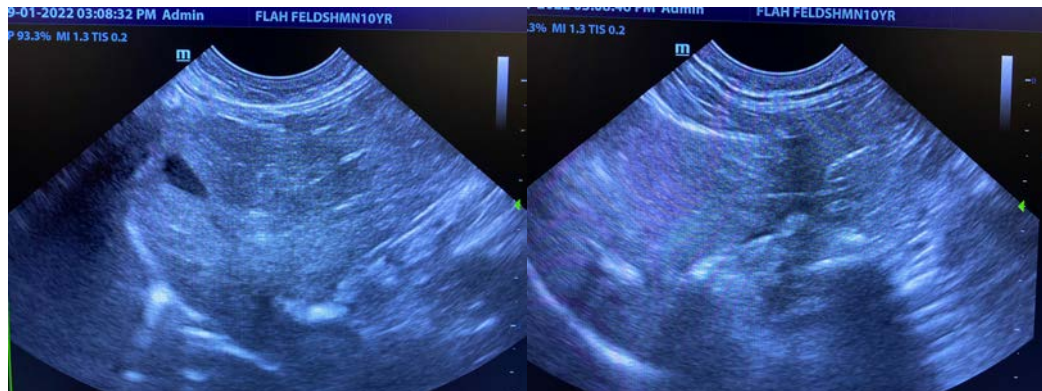


AGE

10 Years

WEIGHT

12.3 Pounds



INTERPRETED BY

Eric Lindquist, DMV

DABVP, Cert. IVUSS

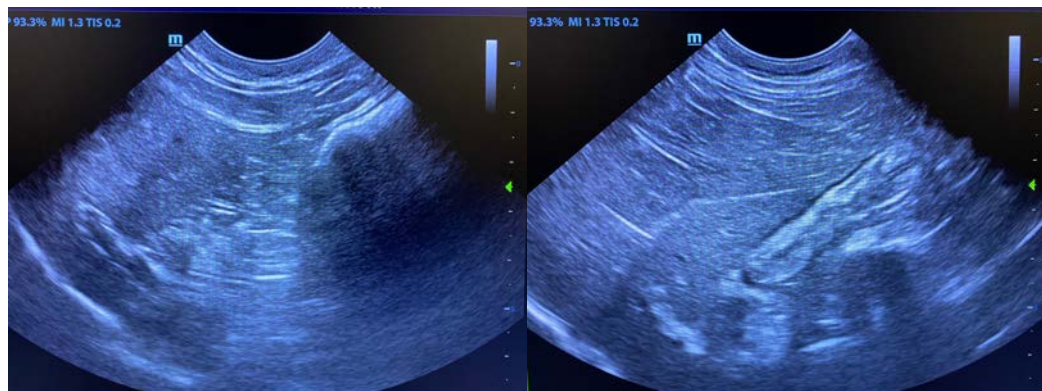
IMAGING PERFORMED BY

Eric Lindquist, DMV

DABVP, Cert. IVUSS

HOSPITAL NAME

Franklin Lakes AH



REFERRING VET

Dr. Kozak

INVOICE

40937

DATE

9/1/22



PATIENT

Frankie Chrust

SPECIES

Feline

BREED

DSH

SEX

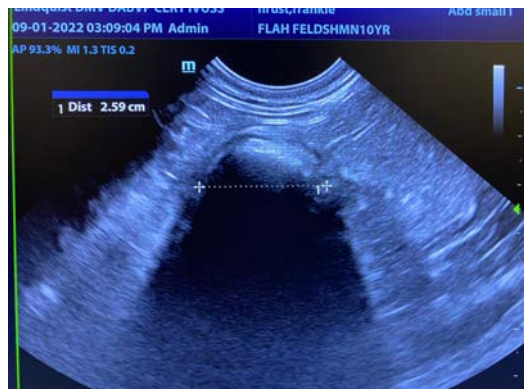Neutered Male

AGE

10 Years

WEIGHT

12.3 Pounds



The information and recommendations provided are based on the images presented by the referring veterinarian/sonographer. No evaluation can be communicated regarding pathology that was not visible in the image/video clips provided.

Thank you for this referral. If the clinical or image interpretation does not parallel your findings or if I can be of any further assistance please contact me.

Eric Lindquist, DMV, DABVP, Cert. IVUSS, CEO of SonoPath.com

info@SonoPath.com

INTERPRETED BY

Eric Lindquist, DMV

DABVP, Cert. IVUSS

IMAGING PERFORMED BY

Eric Lindquist, DMV

DABVP, Cert. IVUSS

HOSPITAL NAME

Franklin Lakes AH

REFERRING VET

Dr. Kozak

INVOICE

40937

DATE

9/1/22