

PATIENT

Roscoe Blair

SPECIES

Canine

BREED

English Pointer

SEX

Male

AGE

8 years

WEIGHT

56 lbs

INTERPRETED BY

Eric Lindquist, DMV
DABVP, Cert. IVUSS

IMAGING PERFORMED BY

Jenn

HOSPITAL NAME

Rockaway AH

REFERRING VET

Dr. Maniar

INVOICE

46510

DATE

8/9/23

PRESENTING CLINICAL SIGNS

History: chronic vomiting, chronic diarrhea, enlarged prostate decreased appetite Current meds Cerenia Pepcid
Abnormal PE/Chem/CBC/UA Results: Decreased ALB increased Glob increased ALKP E Canis +

ULTRASONOGRAPHIC EXAMINATION OF THE ABDOMEN

Urinary System

The **urinary bladder**, trigone, and pelvic urethra presented normal thicknesses and normal tone. The ureters were not visible which is normal. No uroliths or sediment were visualized and anechoic urine was present. No evidence of inflammatory or neoplastic changes was noted. Ureteral papillae were normal.

The **prostate** was uniformly enlarged with lobar swelling appeared to impinge upon the urethra and mildly deviate the descending colon. The prostatic tissue was hyperechoic containing focal areas of decreased echogenicity. These changes are suggestive of either chronic inflammatory episodes, benign cystic pathology or both. Underlying neoplasia cannot be completely ruled-out but is lower on the differential list. This presentation is most consistent with benign prostatic hyperplasia with possible active prostatitis. Neutering or off-label Finasteride (Propecia) (0.1-0.5 mg/kg Sid) treatment is indicated +/- FNA or prostatic wash cytology and culture. The prostate measured 3.5 cm.

The **kidneys** revealed largely normal size and structure, corticomedullary definition and ratio (cortex 1/3 of medulla) were essentially maintained with some age-related loss of curvilinear patterns regarding the capsule and C/M junction. The cortices presented largely uniform texture with some increased echogenicity expected for his age patient. Medullary structure differed distinctly from that of the cortex and no evidence of pelvic dilation was present. The right kidney measured 7.9 cm and the left kidney measured 7.02 cm.

Adrenal Glands

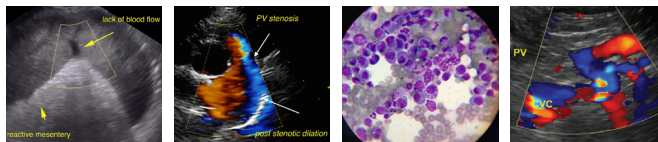
Both **adrenal glands** were visualized and recognized as having normal shape, size, position and echogenicity for this breed. The phrenic vasculature, glandular echogenicity and detail were unremarkable. Capsule, cortex, and medullary definition were normal for this age patient. The right adrenal gland measured 3.42 x 1.9 cm at the cranial pole and 0.62 cm at the caudal pole.

Spleen

The **spleen** presented a smooth homogeneous parenchyma hyperechoic to liver and renal cortical parenchyma. The capsule was smooth without noticeable expansion or deviation from within the spleen or adjacent pathology. The splenic vasculature demonstrated normal volume without signs of congestion or thrombosis. No sonographic evidence of acute or chronic inflammatory, neoplastic, or infarctual changes was noted.

Liver

The **liver** images submitted revealed subjectively normal liver size, contour, and structure. Parenchymal echogenicity was naturally coarse and hypoechoic to the spleen. Vascular and biliary tracts were of



PATIENT

Roscoe Blair

normal volume with no evidence of congestion. The gallbladder presented acceptably thin walls with primarily anechoic content. The cystic and common bile ducts were normal. No pathological hepatic lymphadenopathy was evident. No overt structural evidence of inflammatory, infiltrative or regenerative pathology was evident.

SPECIES

Canine

Gastrointestinal

Examination of the **gastrointestinal tract** revealed a stomach and intestine free of stasis, of normal wall thickness, acceptable curvilinear mural detail, and peristaltic activity. Small and large intestine demonstrated normal luminal chyme and stool consistency respectively. No obstructive or overt infiltrative disease was noted. No associated abnormal lymphatic activity was noted.

BREED

English Pointer

SEX

Male

Pancreas

The base and limbs of the **pancreas** were observed to be largely isoechoic to surrounding omental fat. Pancreatic duct and capsular contour were acceptably normal and parenchyma respected normal curvilinear patterns. No overt evidence of active inflammatory or neoplastic disease was noted.

AGE

8 years

ULTRASONOGRAPHIC FINDINGS

WEIGHT

56 lbs

BPH Prostate.

Otherwise, structurally unremarkable abdomen.

INTERPRETED BY

Eric Lindquist, DMV
DABVP, Cert. IVUSS

INTERPRETATION OF THE FINDINGS & FURTHER RECOMMENDATIONS

There was no evidence of pathology. Neutering should prove effective regarding prostatic presentation. Screening for Addison's is warranted even though the adrenal glands appear normal.

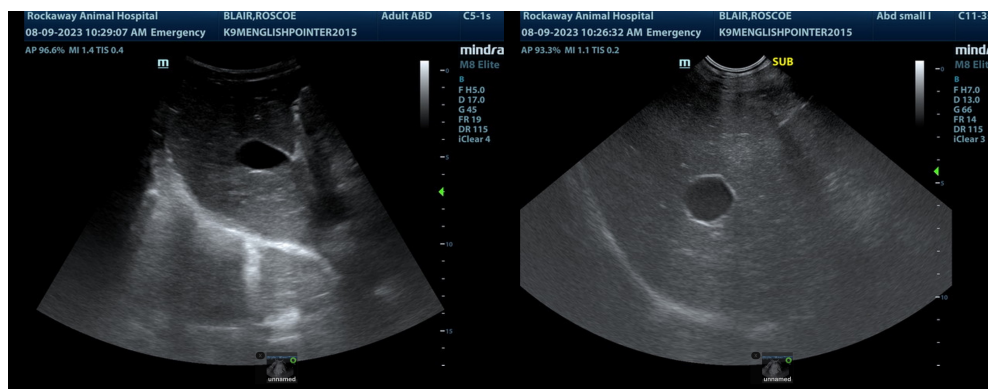
IMAGING PERFORMED BY

Jenn

Dietary indiscretion, food intolerance, structurally significant inflammatory bowel or occult parasitism and occult Addison's are all potentials.

HOSPITAL NAME

Rockaway AH



REFERRING VET

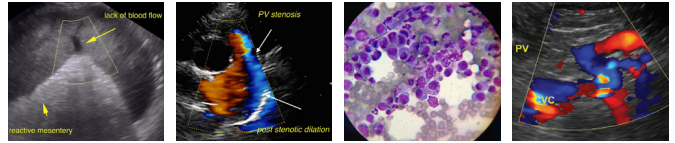
Dr. Maniar

INVOICE

46510

DATE

8/9/23



PATIENT

Roscoe Blair

SPECIES

Canine

BREED

English Pointer

SEX

Male

AGE

8 years

WEIGHT

56 lbs

INTERPRETED BY

Eric Lindquist, DMV
DABVP, Cert. IVUSS

IMAGING PERFORMED BY

Jenn

HOSPITAL NAME

Rockaway AH

REFERRING VET

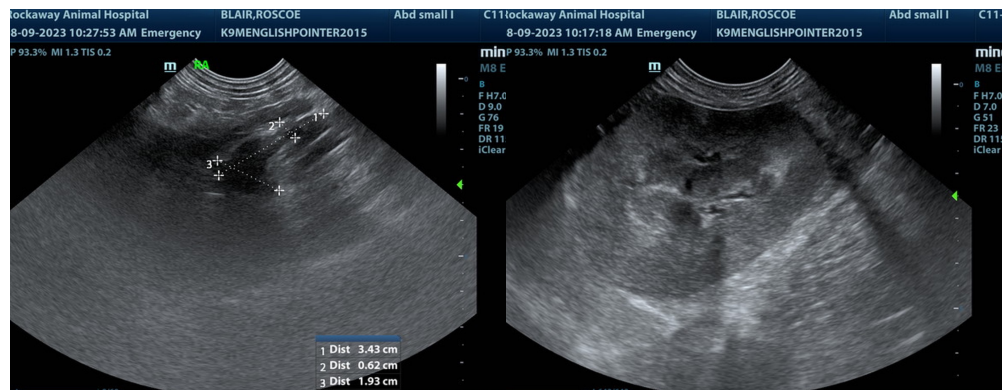
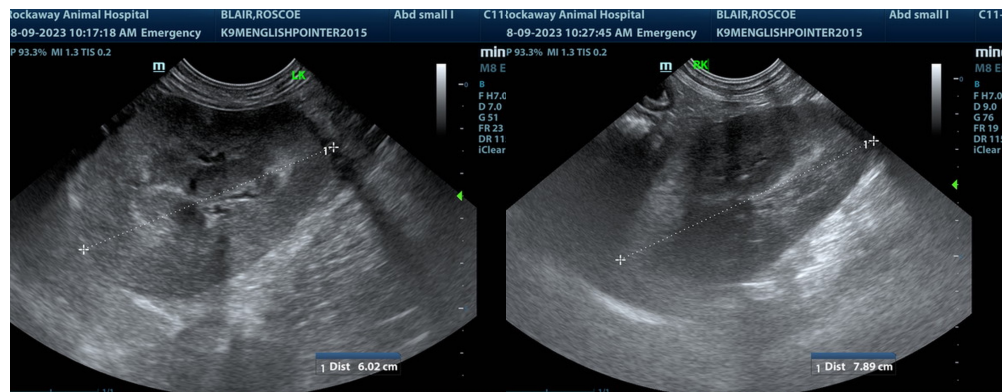
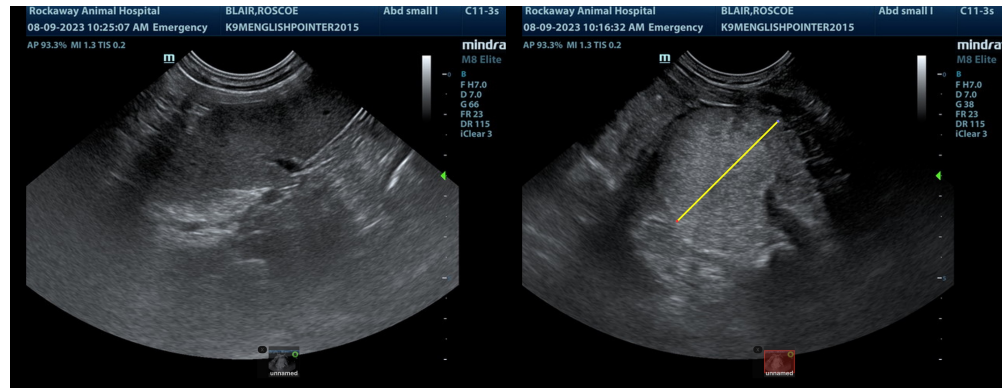
Dr. Maniar

INVOICE

46510

DATE

8/9/23



The information and recommendations provided are based on the images presented by the referring veterinarian/sonographer. No evaluation can be communicated regarding pathology that was not visible in the image/video clips provided.

Thank you for this referral. If the clinical or image interpretation does not parallel your findings or if I can be of any further assistance please contact me.

Eric Lindquist, DMV, DABVP, Cert. IVUSS, CEO of SonoPath.com
info@SonoPath.com